University of California
San Francisco

Lung MRI
Educational Session, ISMRM 2019

Peder Larson, Ph.D.
Associate Professor
Department of Radiology and Biomedical Imaging
peder.larson@ucsf.edu

May 16, 2019

Declaration of Financial Interests or Relationships

Speaker Name: Peder Larson

I have the following financial interest or relationship(s) to disclose with regard to the subject matter of this presentation:

- Consultant: Human Longevity Inc

Outline

- Why Lung MRI?
- Challenges in Lung MRI
- Imaging Methods
  - ^{1}H MRI
  - Inhaled Gasses (O_2, Hyperpolarized ^{3}He, Hyperpolarized ^{129}Xe, ^{19}F)

Slides: https://radiology.ucsf.edu/research/labs/larson/educational-materials

(Google: Peder Larson Group, Educational Materials link on sidebar)

Pulmonary Imaging – X-ray

- Radiography (Xray)
  - Fast (~1 s)
  - Widespread
  - 2D projection (no volumetric information)
  - Ionizing radiation

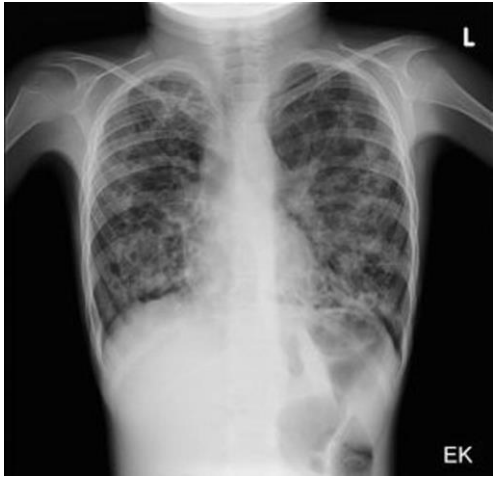

Pulmonary Imaging – Computed Tomography (CT)

- High resolution CT is the gold standard for structural lung imaging
  - Exquisite structural information
  - High resolution (≤ 1 mm)
  - Fast (~1-10 s)
- "*Indispensible in the monitoring of CF patients*" (Radiopaedia.org)
  - Guide therapy and assess response
  - Evaluate a range of features, including tissue thickening, bronchiolitis, bronchiectasis, air trapping, mucus plugging
- *Major drawback*: Substantial Ionizing Radiation
  - Repeated examinations (often every 6-18 months)
  - Substantial exposure in childhood when sensitivity to radiation is much higher
  - Higher rate of radiation-induced malignancies with increases in life span

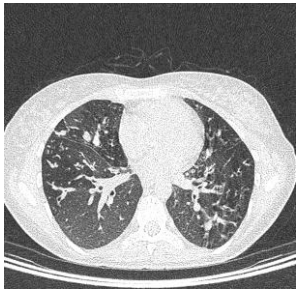

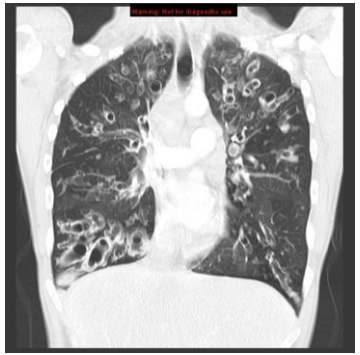

Radiopaedia.org

Pulmonary Imaging - MRI

- Magnetic Resonance Imaging (MRI): Currently ***not*** a major pulmonary imaging modality because
  - Slow (10s to minutes)
  - Spatial resolution not as good at CT
  - Prone to motion artifacts (respiration and cardiac)
  - Often use Breath-hold scanning, challenging for patients with compromised function and in pediatrics
  - Low proton density in lung tissue
  - Large susceptibility differences due to air in lungs leads to short T2*

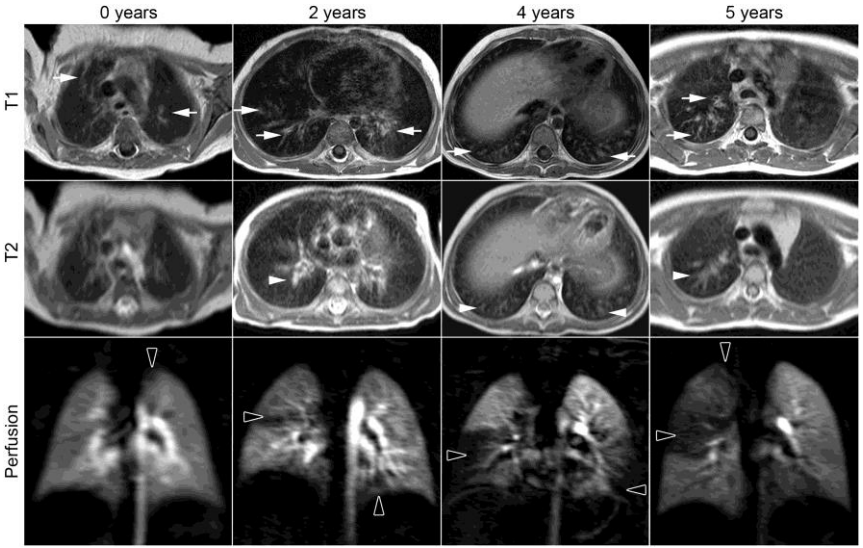

Wielpütz et al; *Am J Respir Crit Care Med* 189, 956-965; 2014.

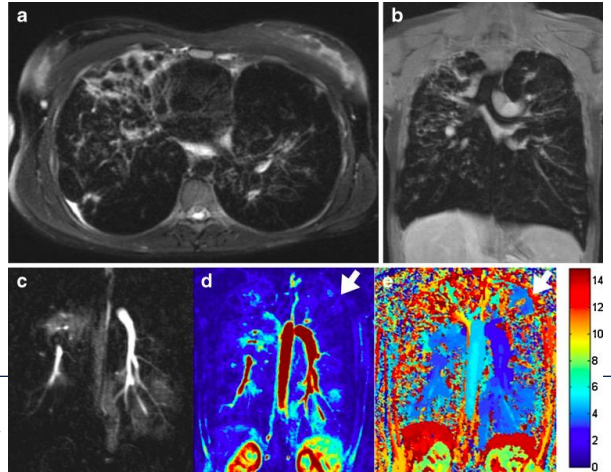

Biederer et al; *Insights Imaging*. 2012 Aug; 3(4): 373–386.

Why is Lung MRI so Challenging?

MR imaging of the lungs is difficult due to:

1) Cardiac and Respiratory Motion

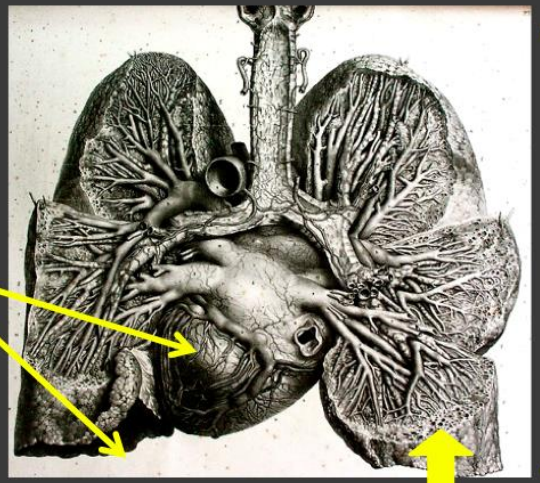

2) Low Proton Density (0.15 g/ml)

3) Lung alveoli create local field inhomogenities and susceptibility gradients → very short T2* (~1ms)

Rapid dephasing of inherently low signal.

†Fawcett/Gehr/Science Photo Library

If Pulmonary MRI is so hard, why should we do it?

- *MRI Advantages*
  - No ionizing radiation
  - Multiple image contrasts available reflecting ventilation, perfusion, cellularity, macromolecular content
  - Resolve lung motion to assess air trapping, motion defects, and tissue stiffness
- Clinical Care
  - Eliminate radiation exposure in routine imaging studies (especially important in pediatrics)
  - Allows more frequent imaging studies to monitor pulmonary structure & function
- Understanding of disease and Development of therapeutics
  - Perform research and longitudinal studies without limitations due to ionizing radiation exposure
  - Particularly valuable for pediatrics and for low acuity diseases such as asthma
- Many possible applications: bronchopulmonary dysplasia, asthma, pulmonary nodules, pulmonary embolism, Interstitial lung diseases, cystic fibrosis, obstructive airway disease, pulmonary infections

MR Imaging Methods

Generally, these fall into two classes

1. ^{1}H MRI methods
   - Using endogenous water signal
   - Address key challenges of motion and short T2*
2. Inhaled gasses
   - Oxygen-enhanced MRI – ^{1}H imaging when breathing 100% O_2
   - Hyperpolarized ^{3}He (now uncommon due to ^{3}He shortage)
   - Hyperpolarized ^{129}Xe
   - ^{19}F labeled gasses (non-hyperpolarized)

UTE and ZTE Lung Methods

- Ultrashort echo time (UTE) MRI
  - Specialized RF excitation, readout gradients, and image reconstruction
  - Capture rapid signal decay
  - Relatively robust to motion during scan
  - ***Inherent information for motion estimation***

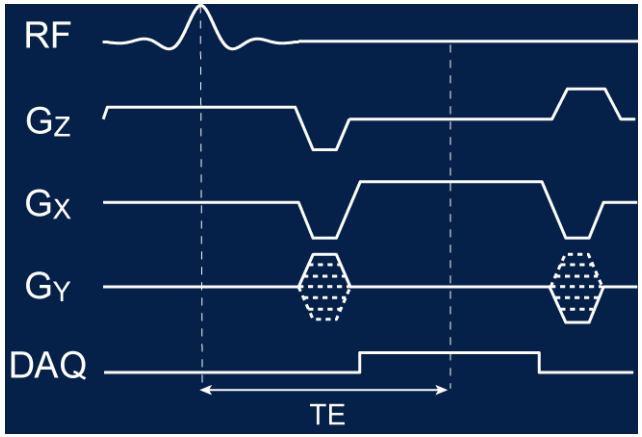

Conventional

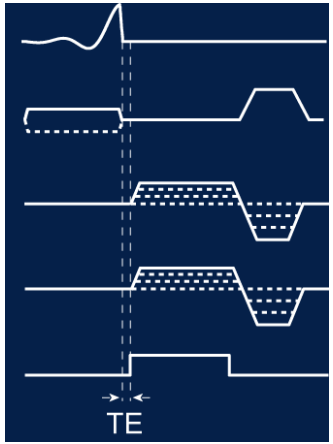

UTE (2D)

Kevin Johnson's "UWUTE"

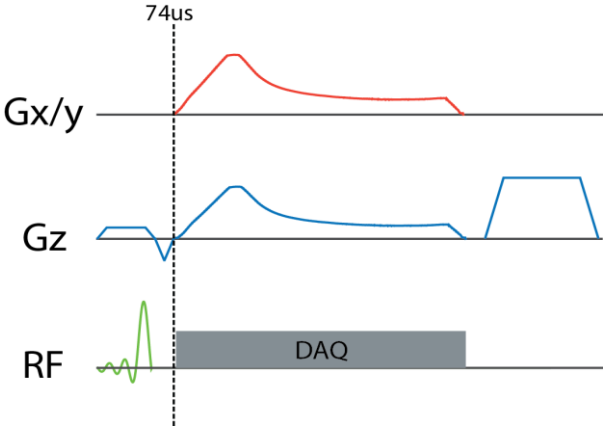

- 3D radial UTE optimized for pulmonary imaging
- Variable density readout (improves SNR)
- Slab excitation (limits FOV to reduce aliasing and motion artifacts)
- Motion correction
  - Adaptive gating (e.g. bellows)
  - Pseudo-random projection ordering (bit-reversed or golden-angle for retrospective data sorting
  - Center of k-space for data-driven motion estimation

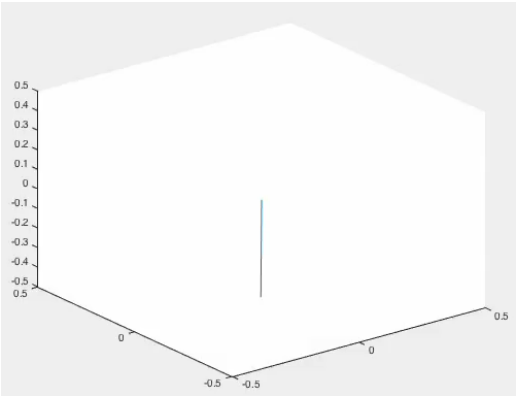

Johnson KM, Fain SB, Schiebler M, Nagle S. MRM 2013; 70(5):1241–1250.

UWUTE: Pulmonary Nodule Detection

- *Goal*: Detect clinically-relevant pulmonary nodules to enable metastatic disease screening in the lung
  - Routine detection with CT
  - Conventional MR sequences fail
- 5-minute Free breathing
- Adaptive bellows-based gating

CT

UTE MRI

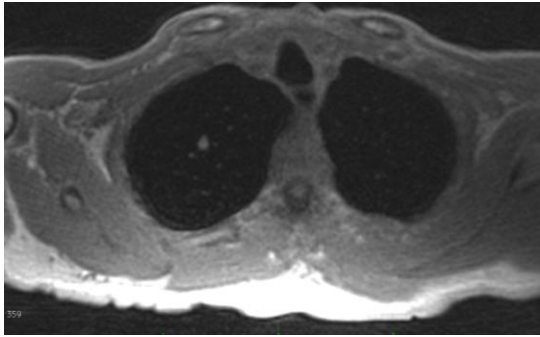

CT

UTE

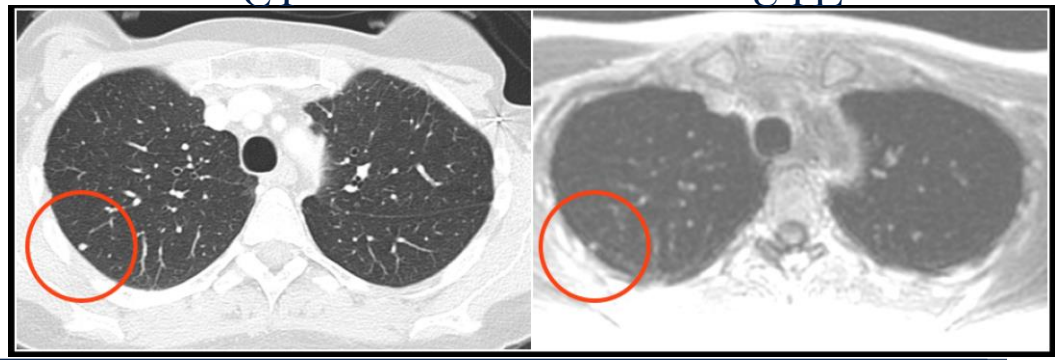

Burris, Larson, Johnson, Hope et al; *Radiology* 2015.

Neonatal Pulmonary MRI

- Cincinnati Children's Hospital
- Dedicated Neonatal 1.5 T MRI
- 3D UTE (UWUTE)
- Self navigation

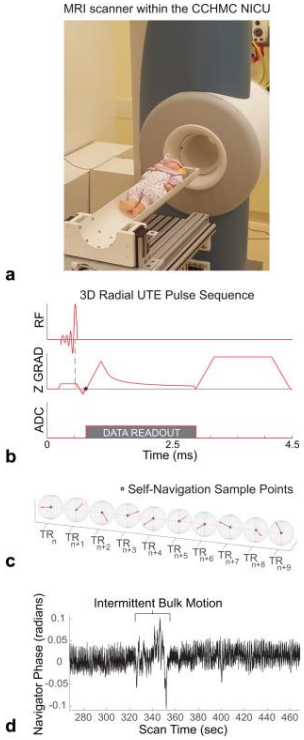

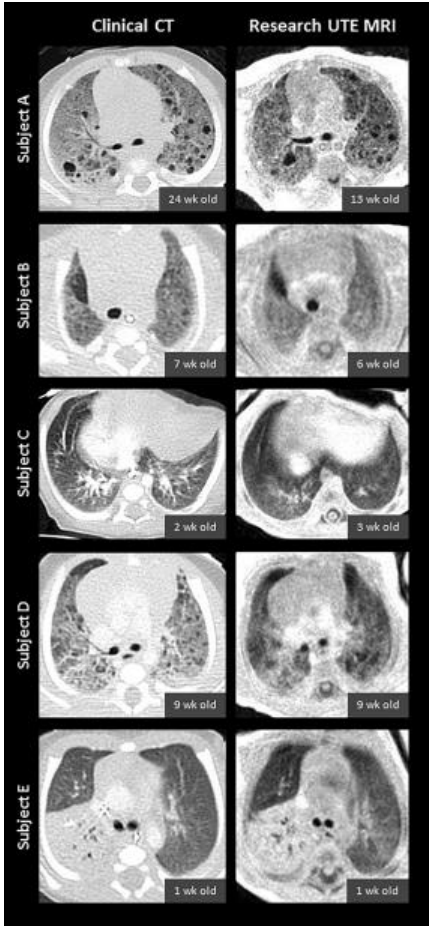

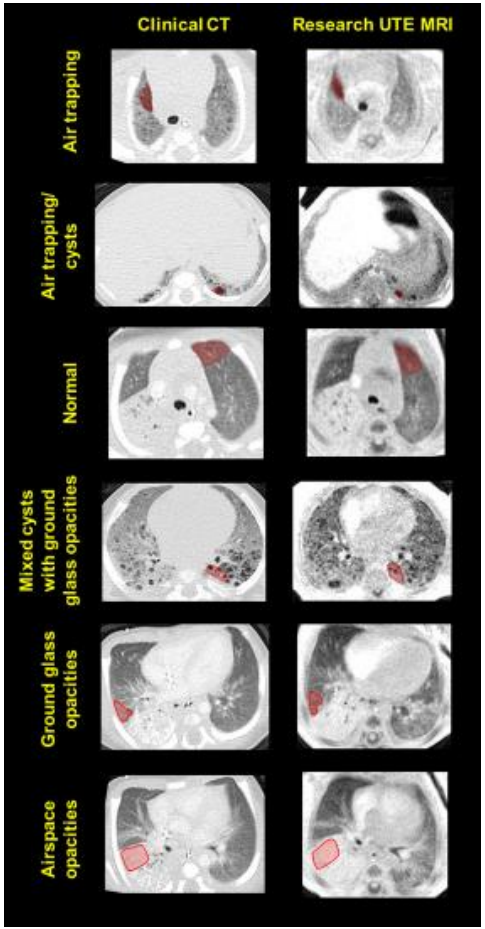

Higano, et al. J. Magn. Reson. Imaging. doi: 10.1002/jmri.25394, 10.1002/jmri.25643

UTE Cones: Pulmonary Nodules in Pediatrics

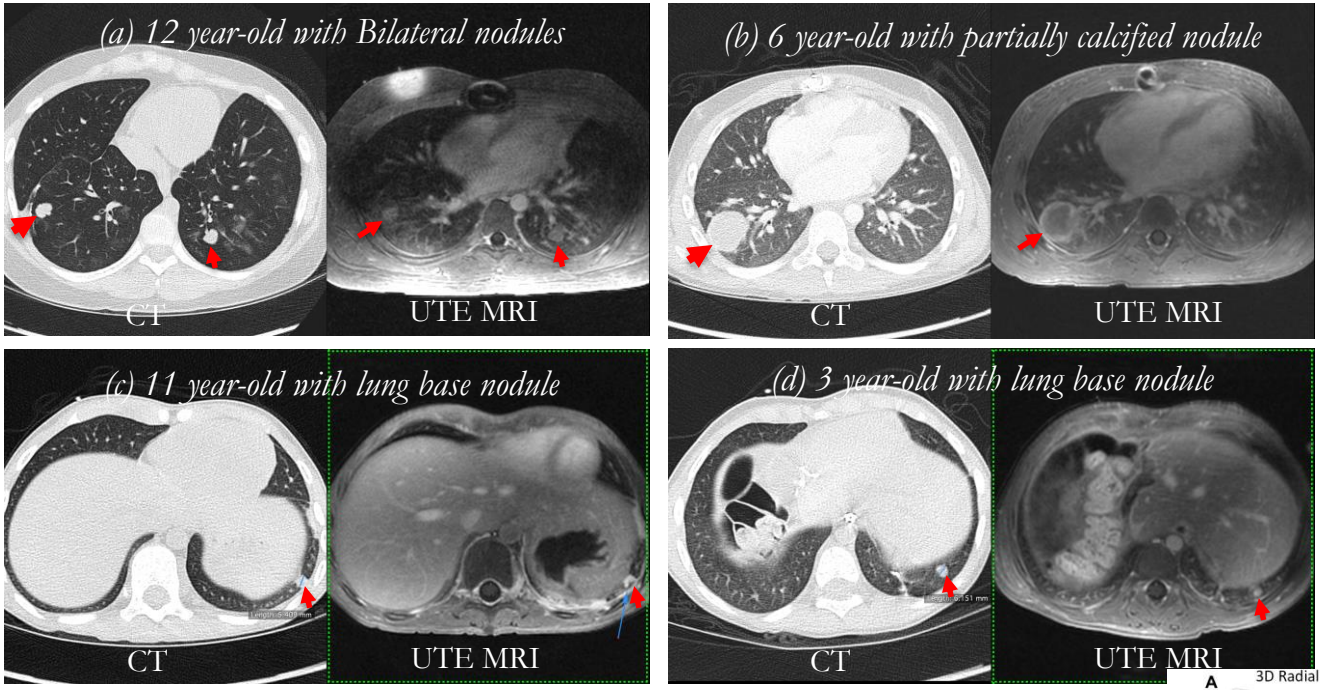

Acquired with UTE Cones sequence, fat suppression, no motion correction, in sedated subjects

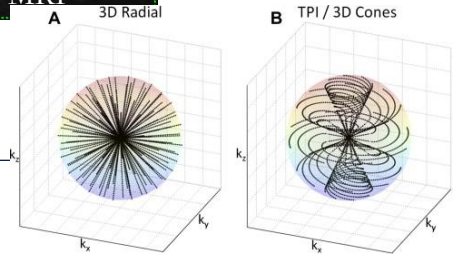

Zucker, Cheng, Vasanawala, et al, J Magn Reson Imaging 2018.

MRI Sequence comparison

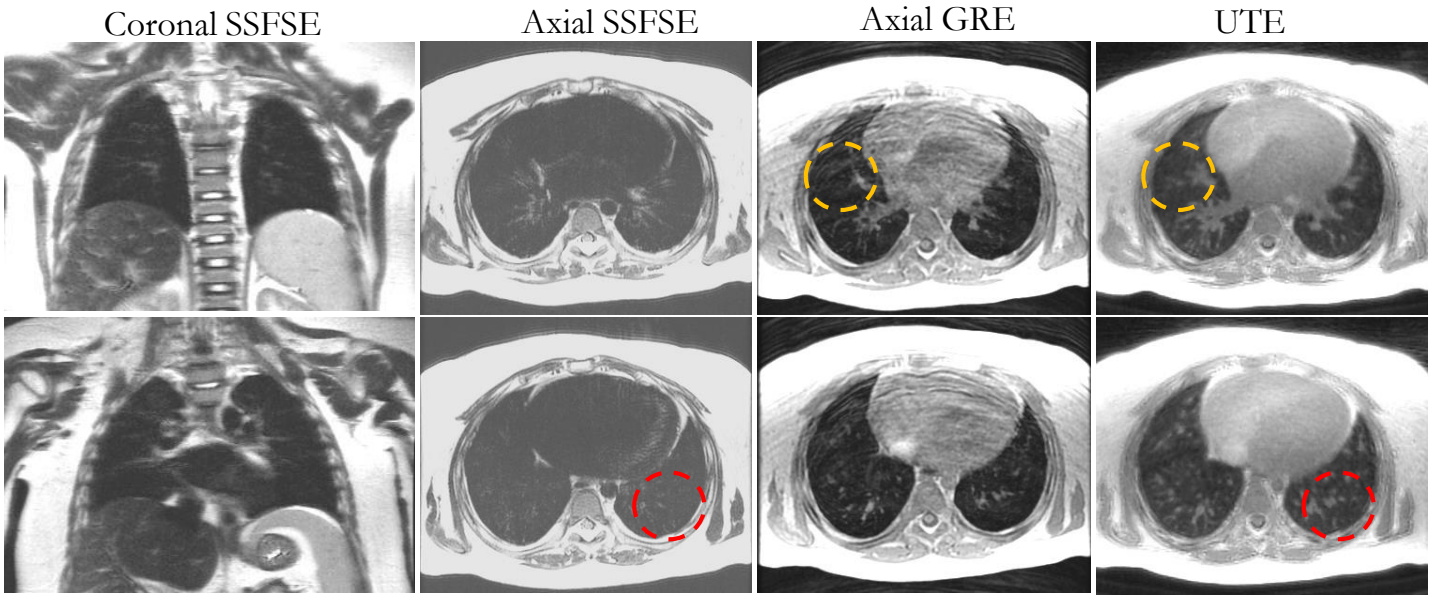

- Sedated 5 year-old
- Only UTE shows signal from the lung parenchyma, and has the most clear visualization of the pulmonary vasculature without motion artifacts.

Zhu, Larson, et al. *Proc. ISMRM* 2019, # 4492.

Other UTE Trajectories

- Twisted Projection Imaging (Boada MRM 1997 doi:10.1002/mrm.1910380624)
- Cones (Gurney et al. MRM 2006 doi: 10.1002/mrm.20796)
- FLORET (Robison et al MRM 2018 doi: 10.1002/mrm.26500)
- Stack of Spirals
- Stack of Stars

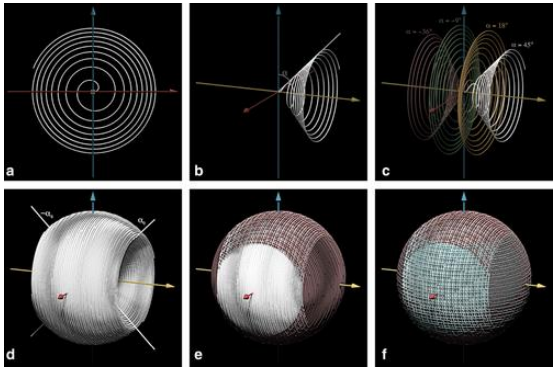

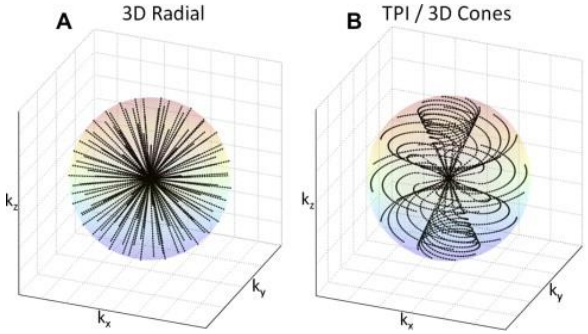

Madelin JMRI 2013 doi: 10.1002/jmri.24168

Major Challenge: Motion

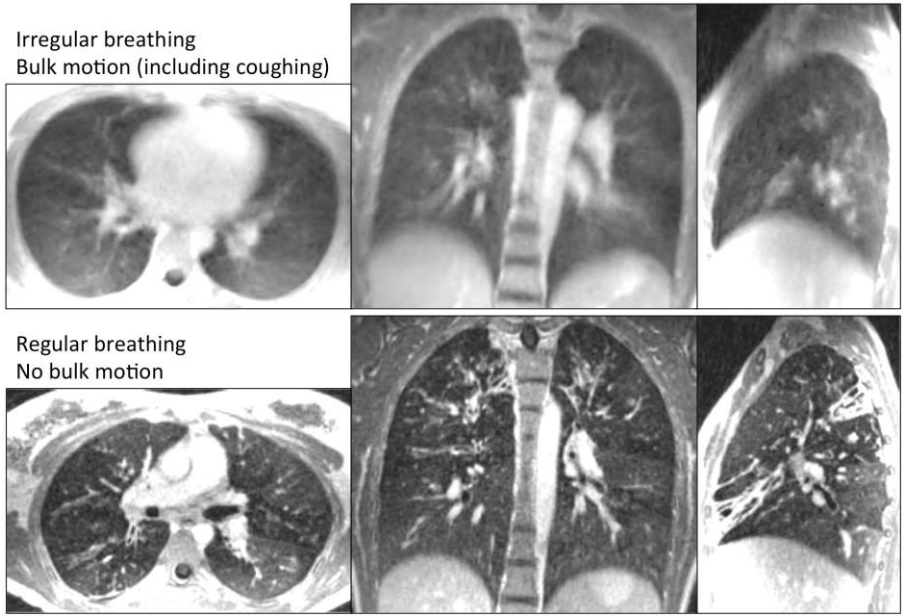

UTE MRI in Pediatric Cystic Fibrosis(CF) patients

Image quality substantially compromised in up to 30% of patients due to uncorrected motion (Irregular breathing, Coughing, Bulk motion)

Particularly problematic for children and patients with compromised pulmonary function

Motion Compensation and Reconstruction

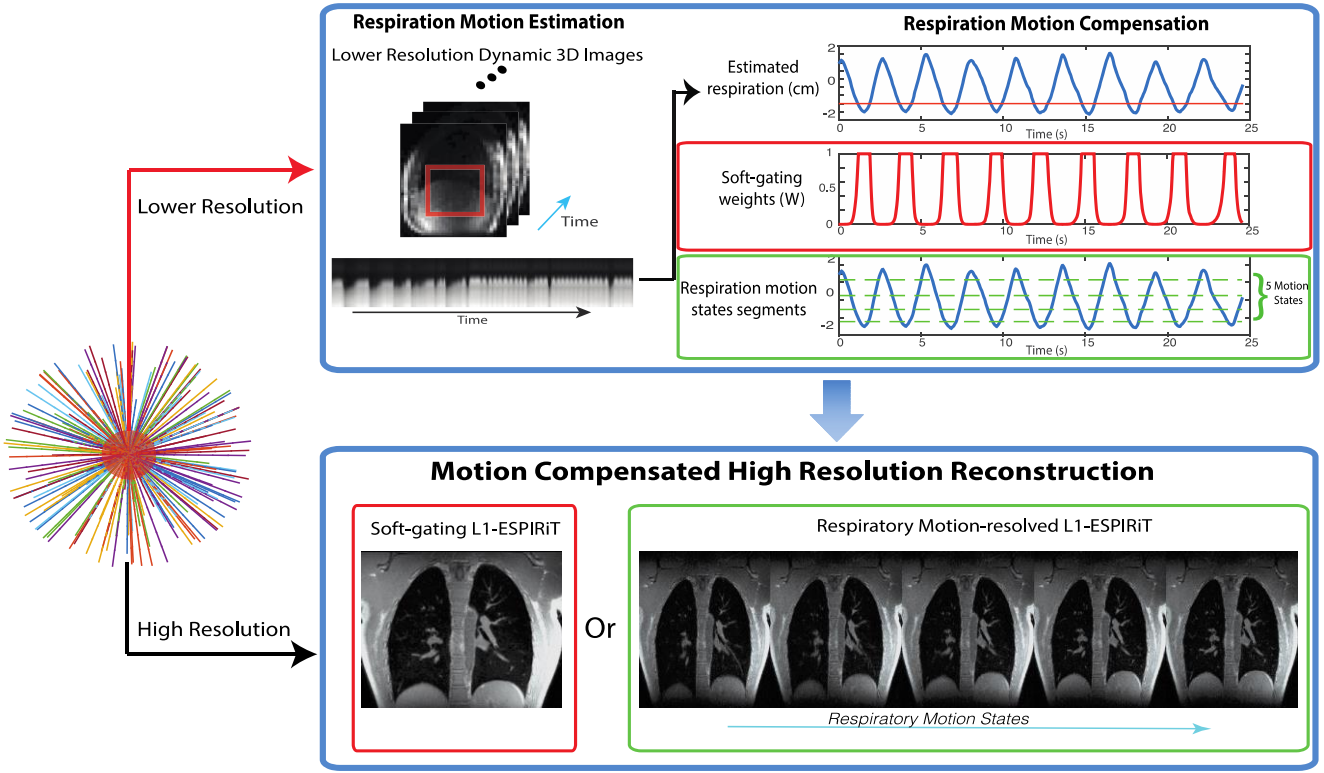

Jiang, Johnson, Lustig, Larson et al, Magn Reson Med 2018.

- With UTE and ZTE, center of k-space or low-resolution images for motion estimation
- Motion Estimation can be used for hard-gating (binning), soft-gating or XD motion-resolved reconstructions

[1] Cheng et al. JMRI 2014 .[2] Johnson et al. MRM 2014. [3] Feng et al. MRM 2015

Motion Estimation: Dynamic 3D Navigator with Local Low-Rank

Jiang, Johnson, Lustig, Larson et al. *Magn Reson Med* 2018.

- Create Image-based navigator [1] from low-frequency portion of k-space data
- Challenge: high-frame rate (>2Hz) and spatial resolution (<1cm) -> ~200-fold undersampling!
- Solution: Enforce a local low-rank constraint across time

$$\underset{M_{\mathrm{lr}}}{\operatorname{argmin}} \quad \frac{1}{2}\|DSM_{\mathrm{lr}} - y_{\mathrm{lr}}\|_2^2 + \lambda \sum_{i \in \Omega} \|L_i M_{\mathrm{lr}}\|_*$$

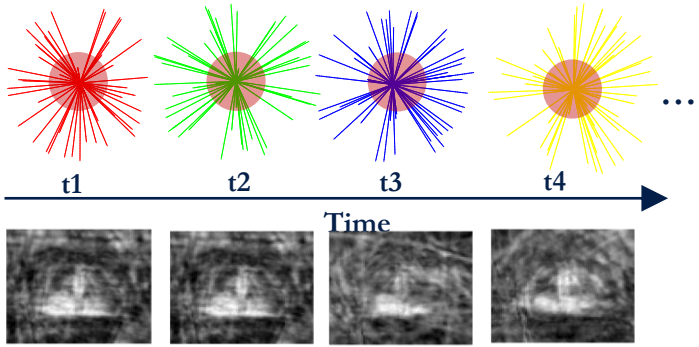

Dynamic 3D Navigator with Local Low-Rank Recon

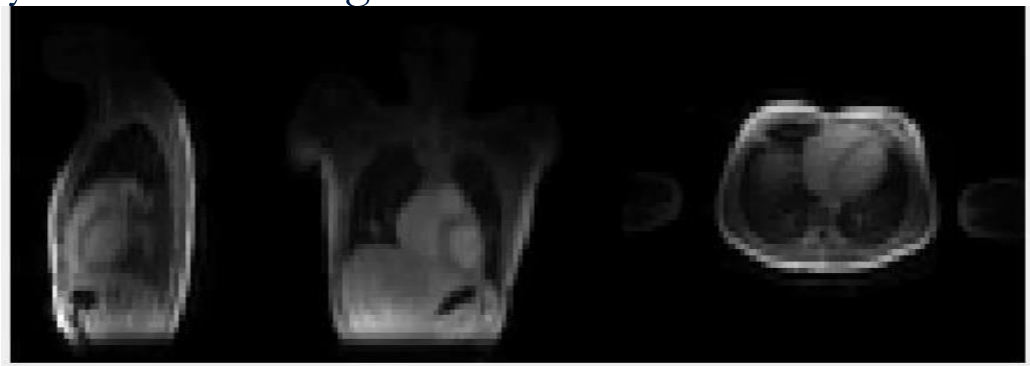

[1] Addy, N O, et al, MRM, 2016

Motion Estimation: Dynamic 3D Self-navigator

Use only center of –space for dynamic reconstruction with local low-rank constraint and parallel imaging (>200-fold undersampled)

6mm isotropic resolution

300ms temporal resolution

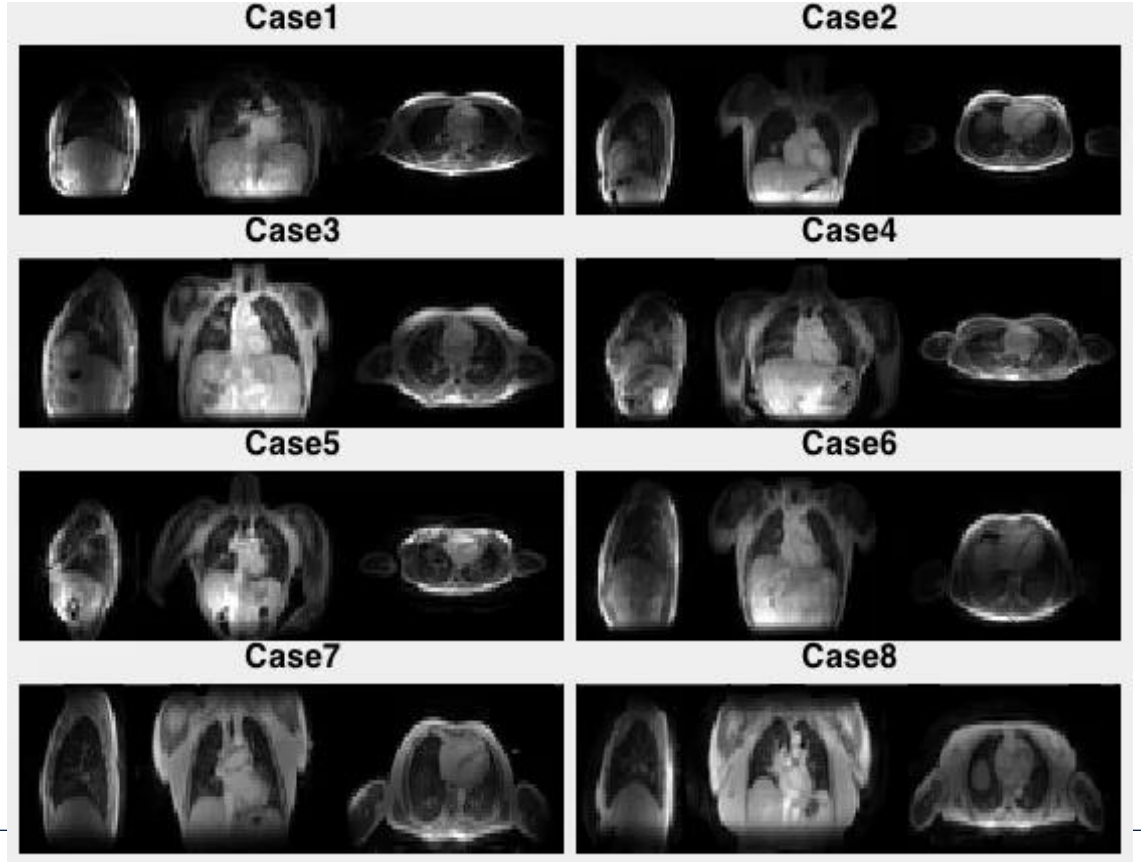

Cystic Fibrosis (CF) patients

Jiang, Johnson, Lustig, Larson et al, Magn Reson Med 2018.

“Extreme MRI”

- Super-high-resolution dynamic reconstruction
  - 1.25mm isotropic
  - 515 ms temporal resolution across 4 minute scan
- Extreme undersampling, extreme computational and memory cost
  - Use multi-scale low-rank factorization
  - Stochastic optimization

Ong, Zhu, Larson, Lustig, et al. ISMRM 2019 #1176 (Thursday 1:57pm 710B)

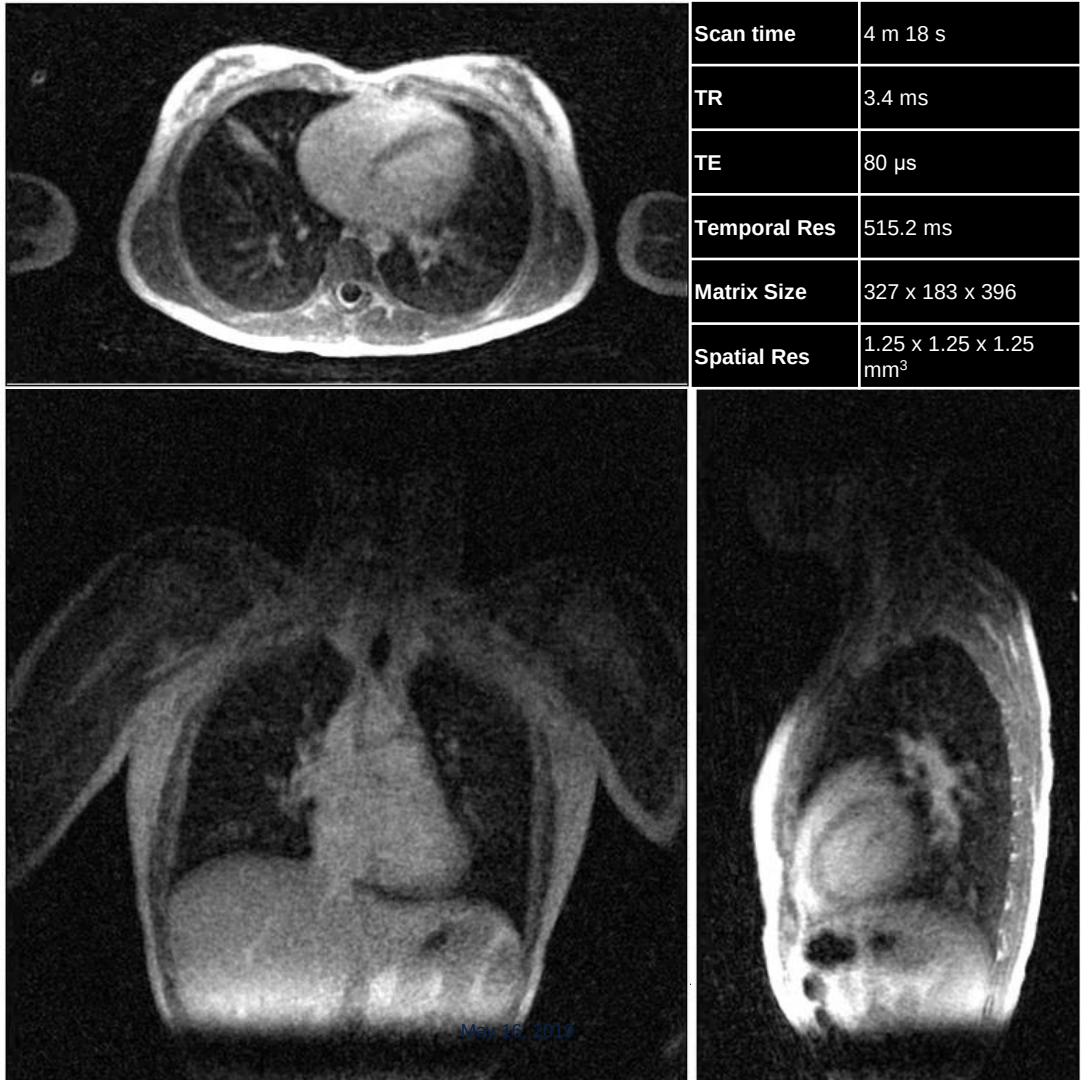

Scan time	4 m 18 s
TR	3.4 ms
TE	80 μs
Temporal Res	515.2 ms
Matrix Size	327 x 183 x 396
Spatial Res	1.25 x 1.25 x 1.25 mm^3

“Extreme MRI”

- 1.6mm isotropic
- 560 ms temporal resolution across 5 minute scan

Ong, Zhu, Larson, Lustig, et al. ISMRM 2019 #1176 (Thursday 1:57pm 710B)

Scan time	4 m 40 s
TR	2.8 ms
TE	80 μs
Temporal Res	560 ms
Matrix Size	320 x 185 x 189
Spatial Res	1.6 x 1.6 x 1.6 mm^3

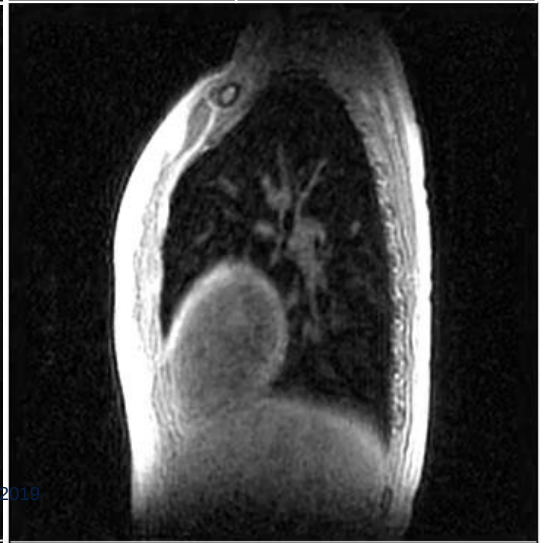

Motion Compensation Strategies

1. Data organization
   - Bin data
   - Reject bulk motion periods
2. Image Reconstruction
   - Single phase with hard or soft-gating (SG)
   - Motion-resolved reconstruction with EXtra Dimensional (XD) methods

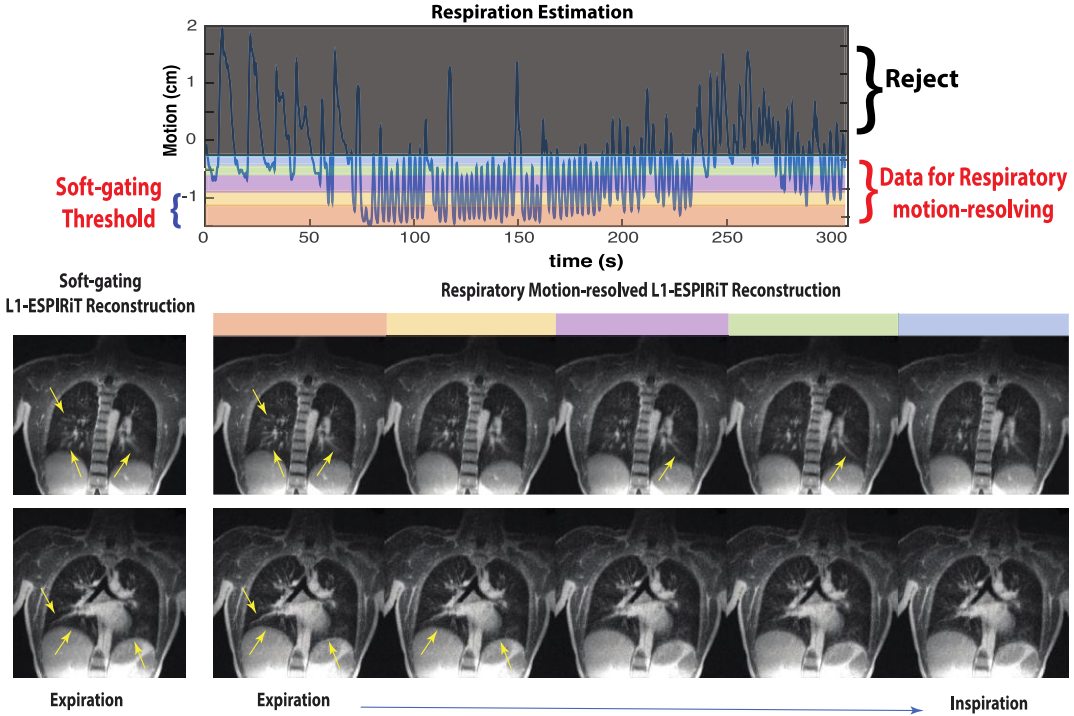

Jiang, Lustig, Larson et al, Magn Reson Med 2018
Feng et al, JMRI. 2019 doi:10.1002/jmri.26245.

Motion-corrected Image Reconstruction

- Motion-resolved (MR)
- Soft-gating(SG)
- Motion-Correction (MoCo)
- **Iterative Motion-Correction (I-MoCo)**

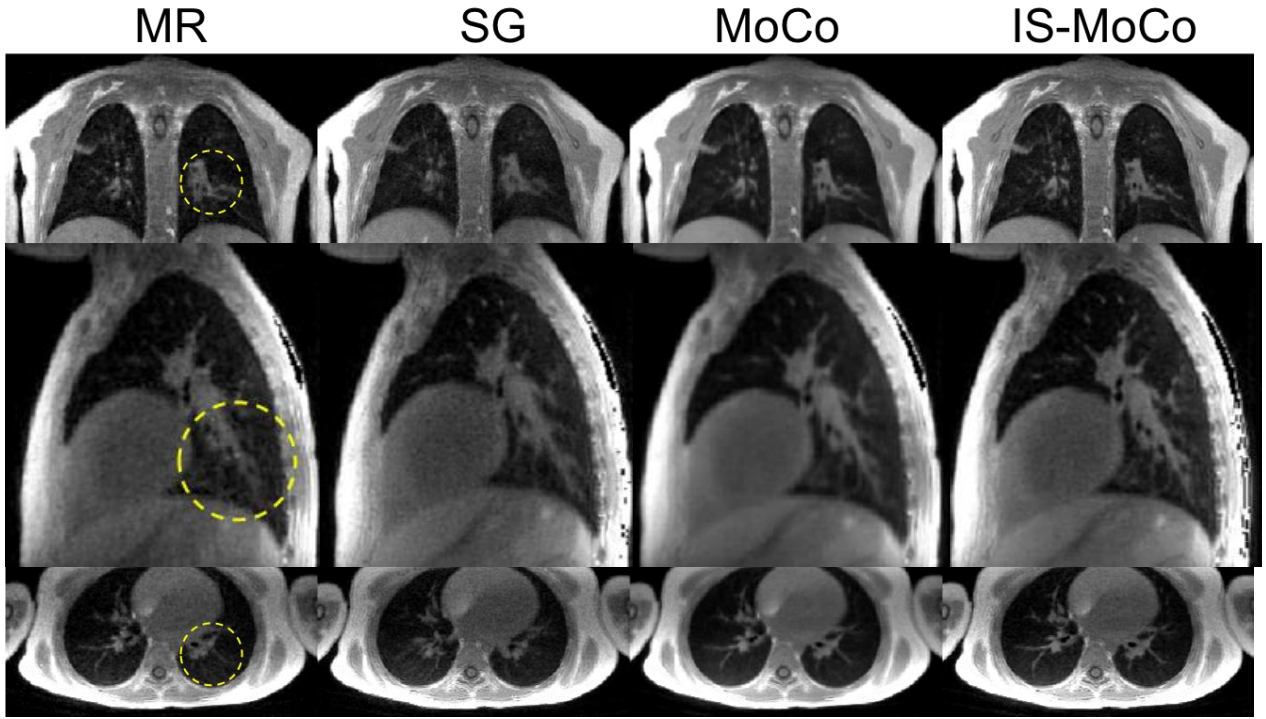

Zhu, Lustig, Larson et al.
Proc ISMRM 2019 #4492
Thursday 8:15am Computer #120

5 year-old, unsedated, 5-minute scan with bulk motion

Pediatric Lung Pathologies Observed with UTE MRI and Motion Compensation

UTE CT

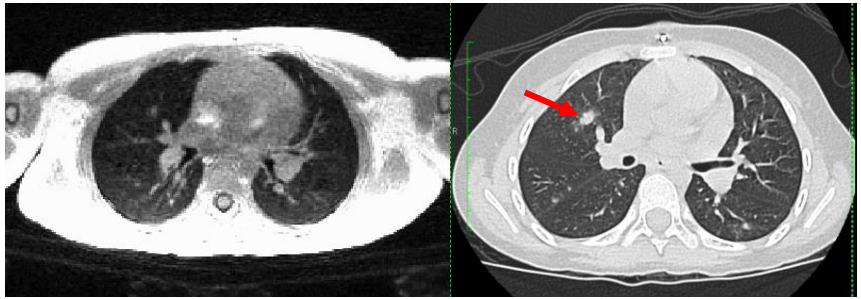

Pulmonary Nodules (5 yo)

UTE CT

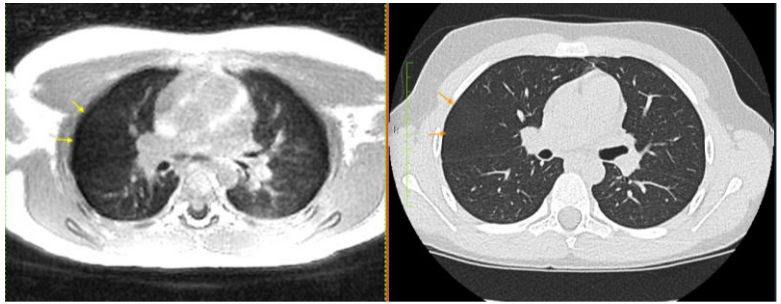

Bronchiolitis Obliterans (11 yo)

UTE CT

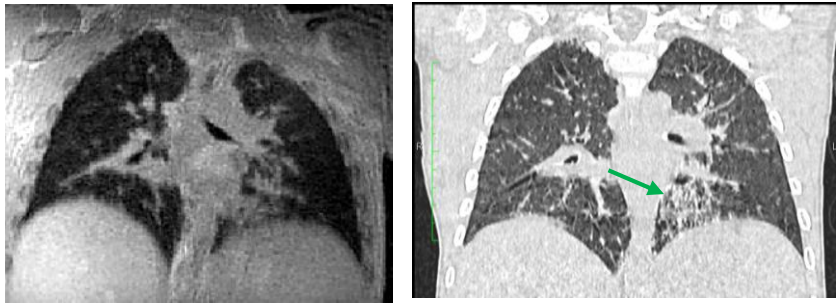

Ground Glass in chILD (4 yo)

UTE CT

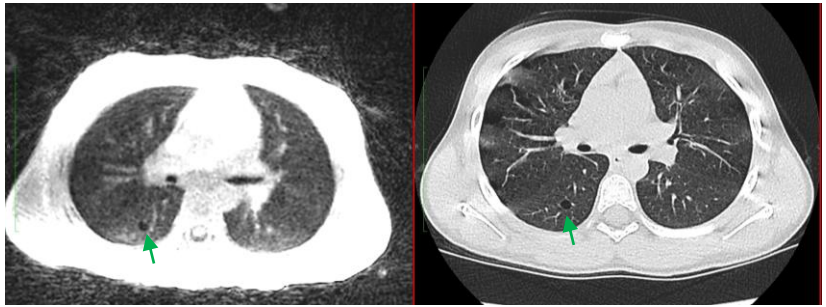

Pneumatoceles (8yo)

Zhu, Larson, et al. *Proc. ISMRM* 2019, # 1898, # 4492.

To UTE or not to UTE: other ^{1}H approaches

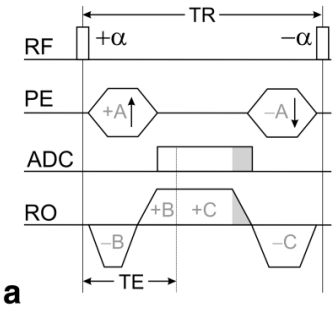

- Ultrafast SSFP (Bieri MRM 2013 DOI: 10.1002/mrm.24858)
  - Short TE (< 1ms) with partial Fourier readout
  - Signal gain from T2* refocusing from SSFP
  - With very short TR (< 2ms), can achieve no banding artifacts at 1.5T
  - Derive ventilation and perfusion via Fourier Decomposition (more in later slides)

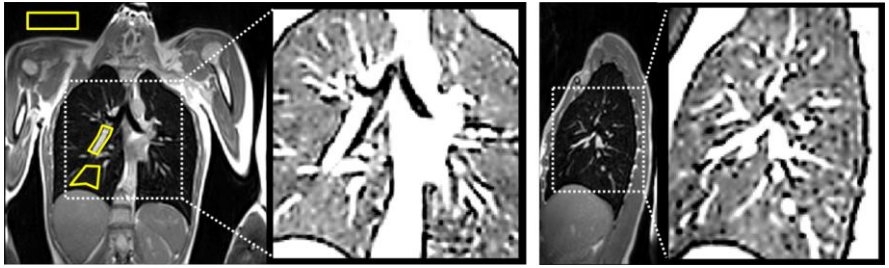

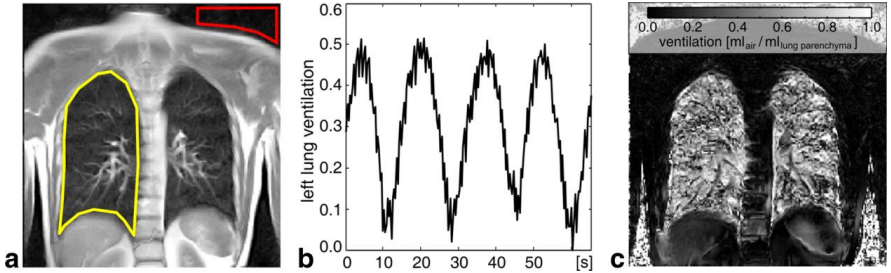

Quantitative Lung Physiology with GRE MRI (Hopkins, Prisk et al UCSD)

- 2D sagittal dynamic imaging with BODY coil; 1.5cm slice, ~1.5mm in-plane
- Fast 2D gradient-echo sequence
  - Use partial k-space for short TE (~1ms) and short TR (<5 ms)
  - Fast 2D scanning with parallel imaging
  - Can freeze respiratory motion

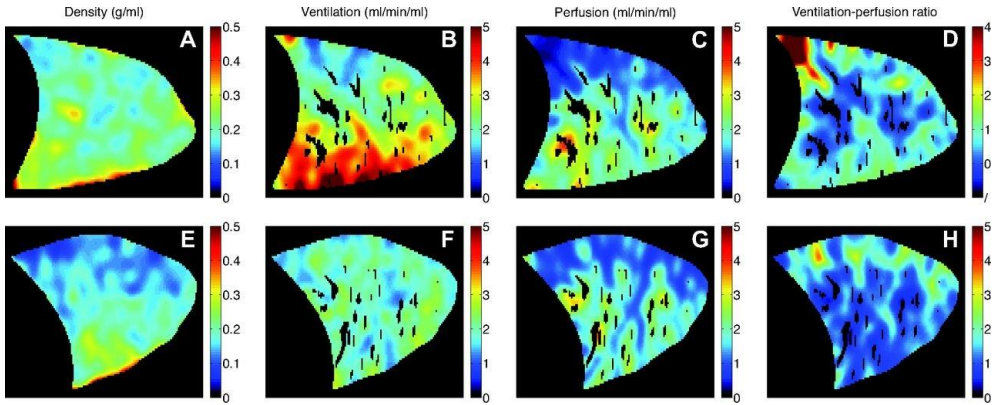

Henderson et al. J Appl Physiol 2013 doi:10.1152/japplphysiol.01531.2012

- Estimate proton density based on 2 TEs and external phantom
- Derive Ventilation and Perfusion
- Combine with Pulmonary ASL methods and oxygen-enhanced imaging

Fourier Decomposition MRI

- Fourier Decomposition (FD) methods derive ventilation (V) and perfusion (Q) in the lung without contrast agents
- Variations: Matrix pencil (MP), and Phase-resolved functional lung (PREFUL) methods

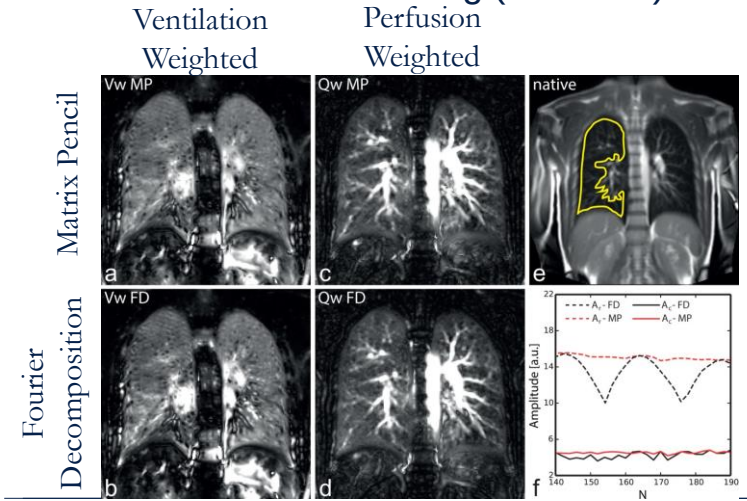

- Based on fast 2D dynamic scanning (e.g. FLASH or, for 1.5T, ultrafast-SSFP), ~0.5 s temporal resolution
- Register dynamic images and analyze temporal frequency amplitudes
- Ventilation changes with amplitude of respiration frequency due to tissue density changes
- Perfusion changes with amplitude of cardiac frequency due to in-flow/time-of-flight effects

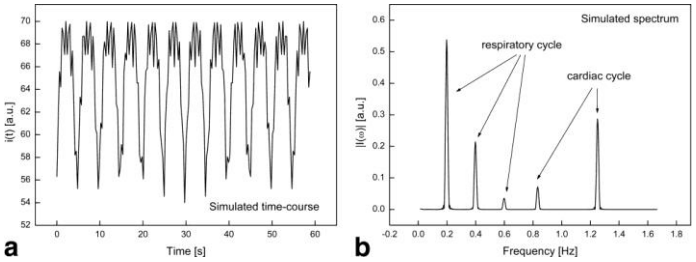

Bauman et al MRM 2009. doi: 10.1002/mrm.22031
Bauman Bieri MRM 2017. doi: 10.1002/mrm.26096
Voskrebenzev Vogel-Claussen et al MRM 2018. doi: 10.1002/mrm.26893

ISMRM 2019: #1, 6, 14, 875, 1880, 1895, 1896, 1897, 4079, 4081, 4093

PREFUL MRI Processing

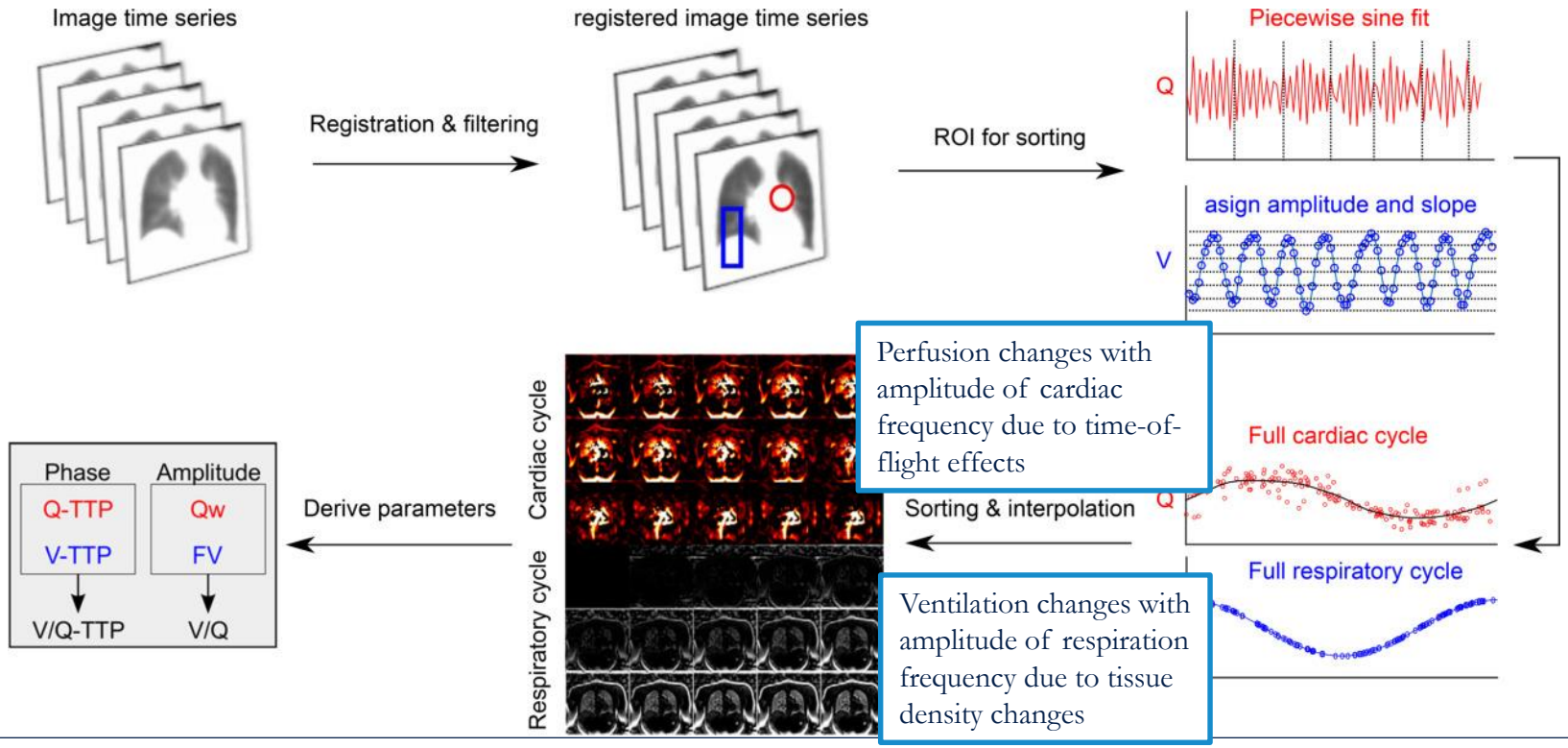

Voskrebenzev Vogel-Claussen et al MRM 2018. doi: 10.1002/mrm.26893

Oxygen enhanced MRI

- O_2 shortens T1 and T2* (See ISMRM 2019 #1889 for details)
  - T1w MRI sensitive to oxygen uptake & ventilation
  - UTE beneficial to remove confounding T2* losses
- Compare images with room air and breathing 100% O_2
- Signal Changes reflect ventilation

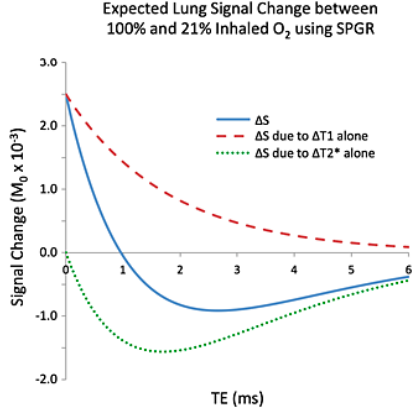

% oxygen enhancements in Healthy subjects

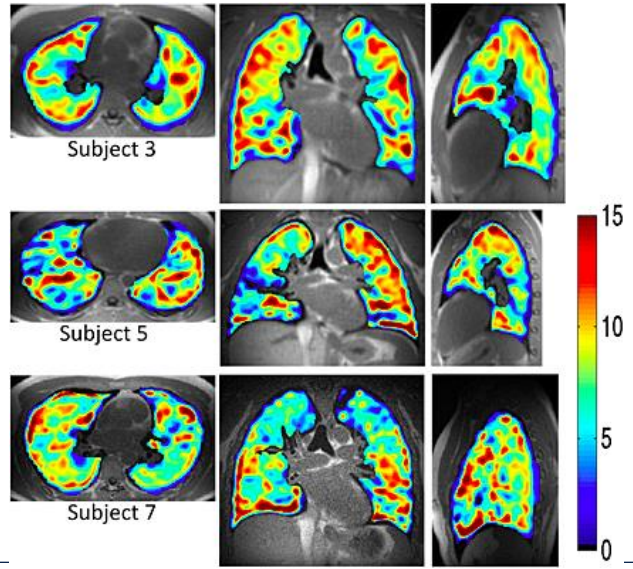

Kruger et al, NMR in Biomed 2014. doi:10.1002/nbm.3158

Oxygen enhanced MRI Relaxation

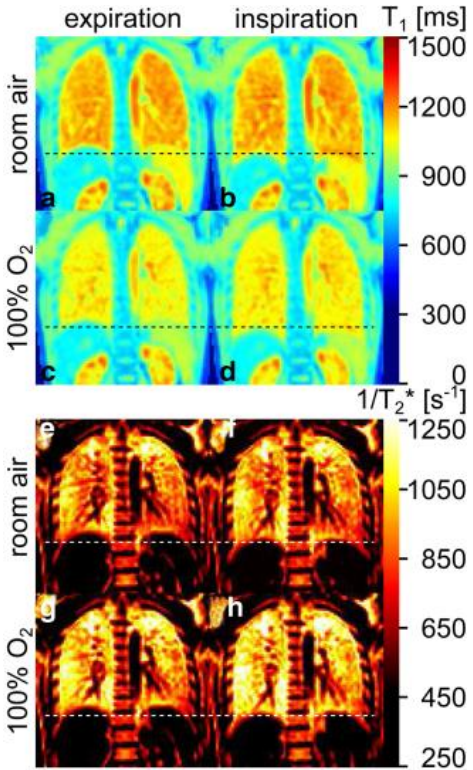

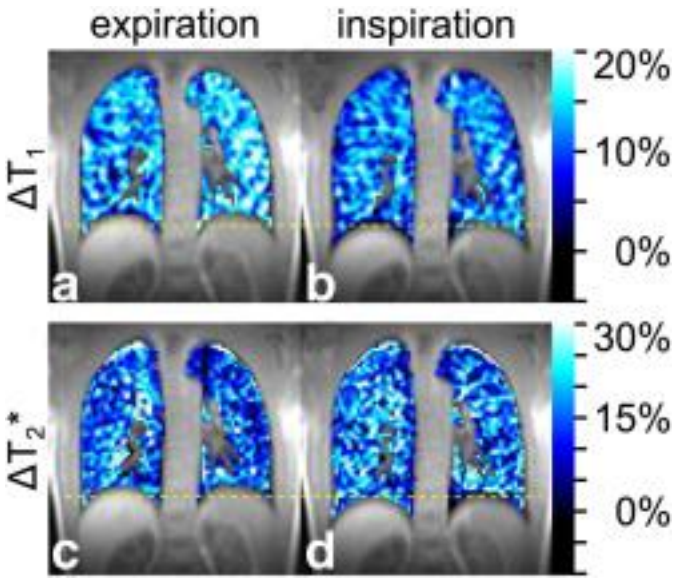

Triphan et al. JMRI 2014. doi:10.1002/jmri.24692

Hyperpolarized Gasses

- Noble gases (e.g. ^{3}He, ^{129}Xe) can be hyperpolarized via Spin Exchange Optical Pumping
- ^{129}Xe is most common (^{3}He is in global shortage)
  - 10-40% polarization!
  - Anesthetic
  - Tissue solubility
- Subjects breathe in hyperpolarized gas, and image
- Phase 3 Clinical Trial of Hyperpolarized ^{129}Xe
- Clinical trial consortium (lead: Jason Woods, Cincinnati Children's Hospital)

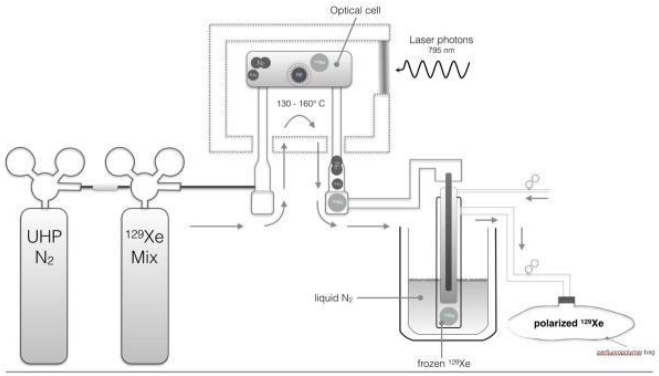

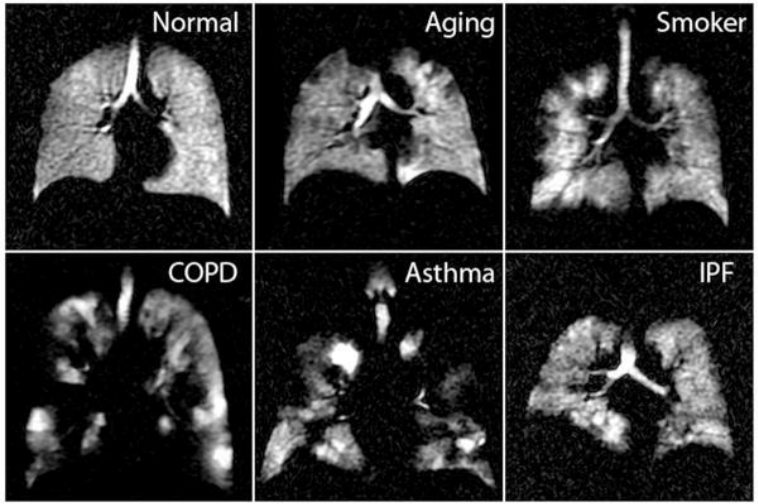

Walker et al. *Rev Mod Phys* 1997, doi:10.1103/RevModPhys.69.629
Roos et al. *Magn Reson Imaging Clin N Am.* 2015, doi: 10.1016/j.mric.2015.01.003

Hyperpolarized ^{129}Xe Ventilation

- Image gas distribution to measure ventilation
- Fast imaging (breath-hold, T1 ~ 20s after inhalation)

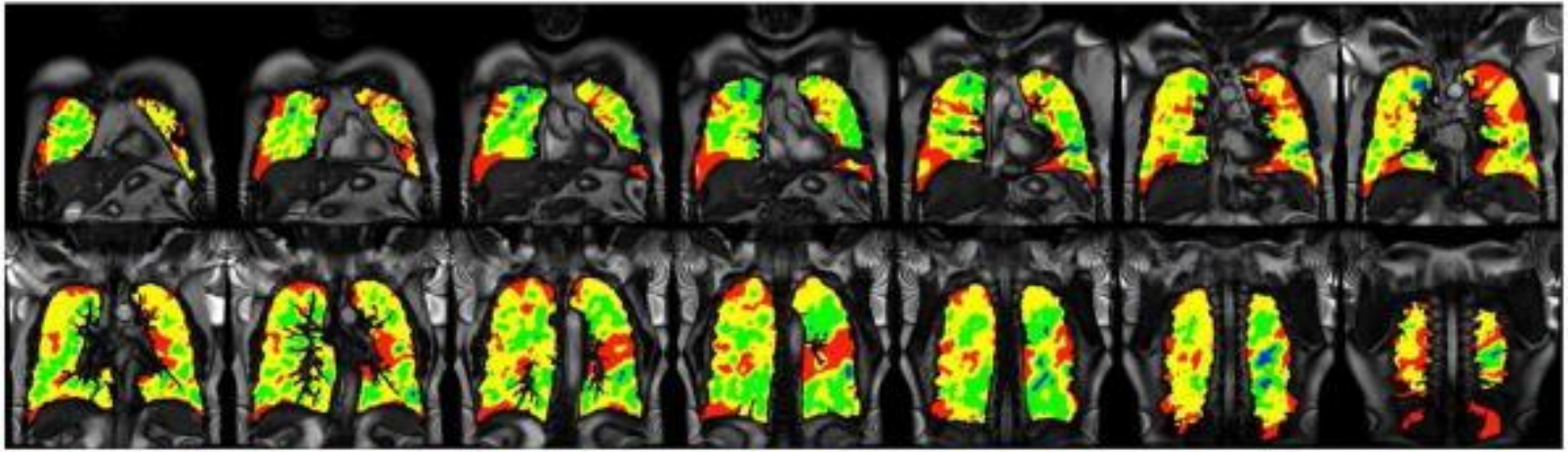

Roos et al. *Magn Reson Imaging Clin N Am*. 2015, doi: 10.1016/j.mric.2015.01.003

Hyperpolarized ^{129}Xe Diffusion-weighted Imaging

- Diffusion-weighted imaging to estimate alveolar sizes
- Image enlarged airways as in emphysema

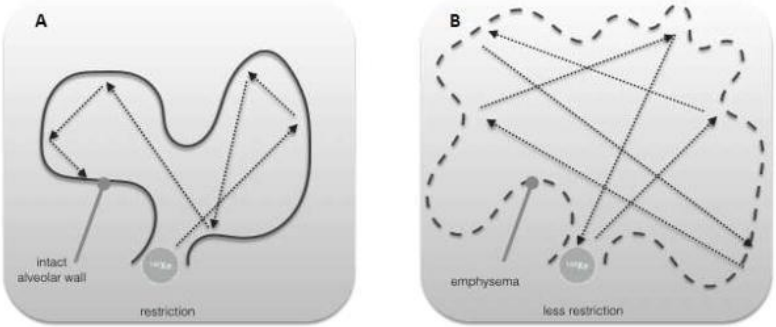

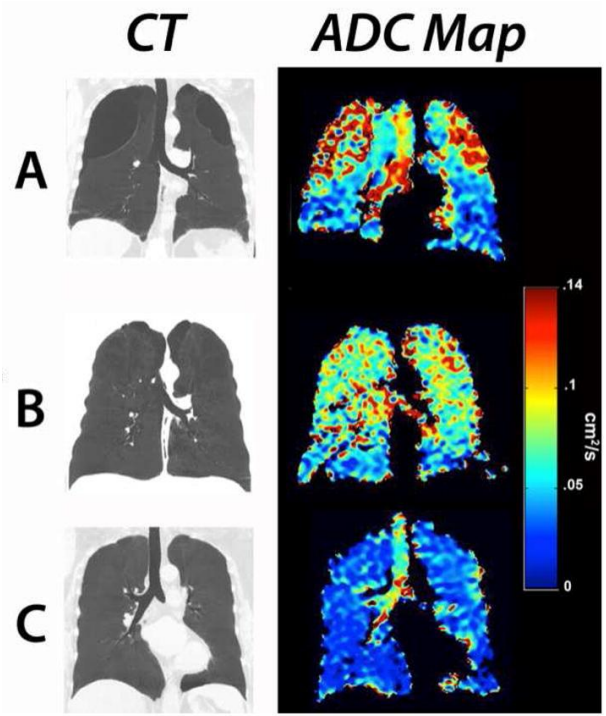

Roos et al. *Magn Reson Imaging Clin N Am*. 2015, doi: 10.1016/j.mric.2015.01.003

Hyperpolarized ^{129}Xe Dissolved Phase Imaging

- Large chemical shift ~200 ppm between gas and dissolved phases of ^{129}Xe
- Allows for imaging of gas exchange within the lung

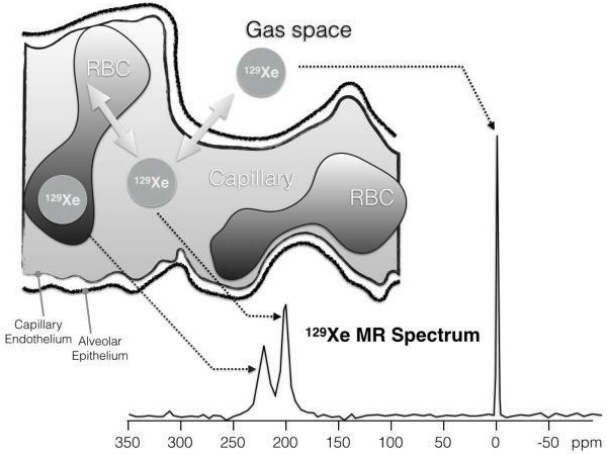

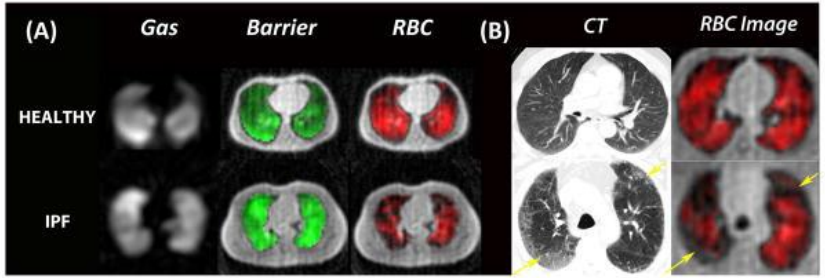

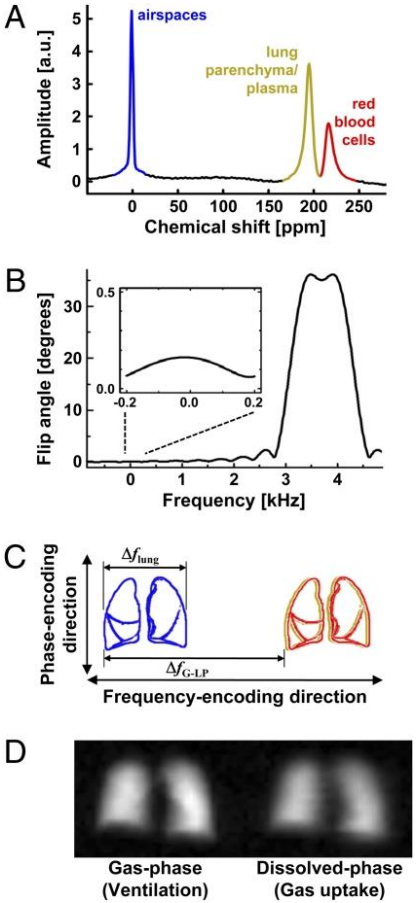

^{19}F Gasses

- Inhale inert fluorinated gasses e.g. tetrafluoromethane (CF_4), sulfur hexafluoride (SF_6), hexafluoroethane (C_2F_6) and perfluoropropane (C_3F_8 or PFP)
- Ventilation imaging
- Flourine-19 has a similar frequency to ^1H so no additional hardware needed
- 100% natural abundance, No background signal
- Non-toxic, inexpensive, and no hyperpolarization required
- Short T2* ~1-2ms, use UTE

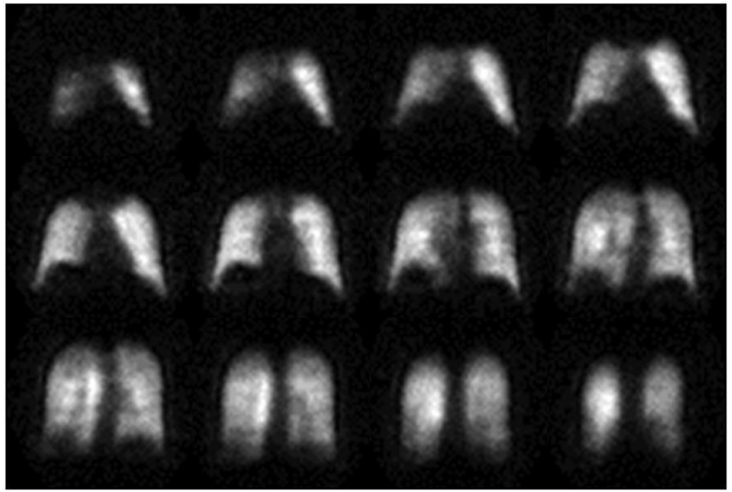

Couch et al NMR in Biomedicine. 2014;27(12):1525–1534. doi:10.1002/nbm.3165
Kruger et al. JMRI 2016 doi: 10.1002/jmri.25002

Summary

- Lung MRI is challenging due to motion, short-T2*, and low signal, but there are many advances in imaging methods and inhaled contrasts
- ^{1}H Imaging Methods
  - UTE and ZTE MRI – Offer ability to capture rapid signal decay and motion. Provides arguably highest resolution anatomical information.
  - Fast 2D gradient-echo methods – Derive functional measurements (ventilation and perfusion) without the need for custom sequences or hardware
- Inhaled gasses
  - Oxygen-enhanced MRI – Assess ventilation and perfusion as a result of relaxation effects
  - Hyperpolarized ^{129}Xe – multiple functional measurements of ventilation, perfusion, and gas exchange
  - ^{19}F – alternative to hyperpolarized gas for background-free ventilation imaging
  - Recent review in Kruger et al. JMRI 2016 doi: 10.1002/jmri.25002

Software Resources

https://github.com/PulmonaryMRI/pulmonary-MRI-reconstruction

- Motion management methods for 3D center-out acquisitions (e.g. UTE radial, cones)

ANTs https://github.com/ANTsX/ANTs

- ANTs Lung MRI Segmentation: https://github.com/ntustison/LungAndLobeEstimationExample (http://onlinelibrary.wiley.com/doi/10.1002/mrm.25824/full)

https://github.com/fumguo/Pulmonary-MRI-and-CT-biomarker-framework

https://github.com/UCSDPulmonaryImaging/Deforminator

PREFUL processing – contact Jens Vogel-Claussen, Hannover Medical School

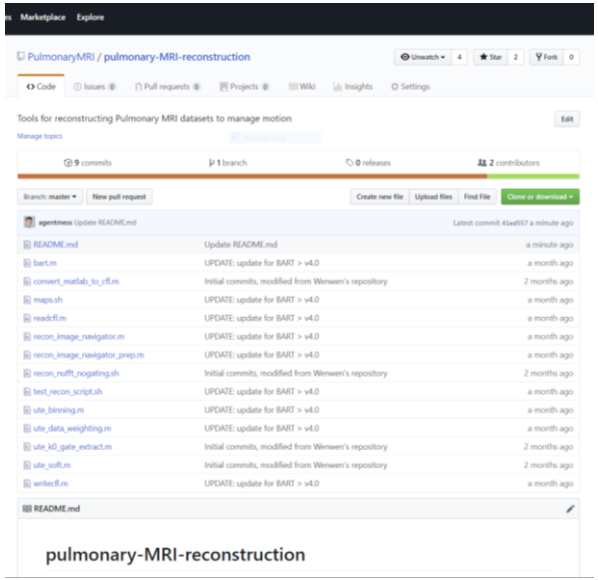

Acknowledgements

- UCSF: Xucheng Zhu, Wenwen Jiang, Marilynn Chan, Ngoc Ly, Thomas Hope, Michael Hope
- UC-Berkeley: Miki Lustig, Frank Ong
- UW-Madison: Kevin Johnson, Sean Fain, Scott Nagle
- Stanford University: Joseph Cheng, Shreyas Vasanawala

Funding

- NIH NHLBI R01HL136965

peder.larson@ucsf.edu @pezlarson http://www.radiology.ucsf.edu/research/labs/larson