

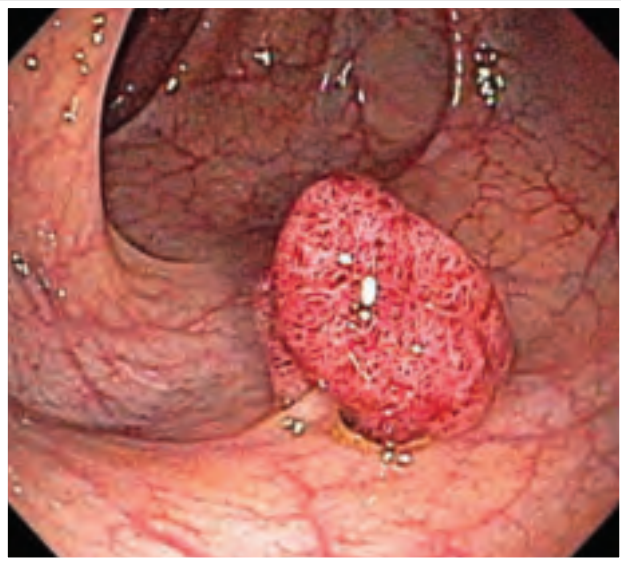


● University of California San Francisco

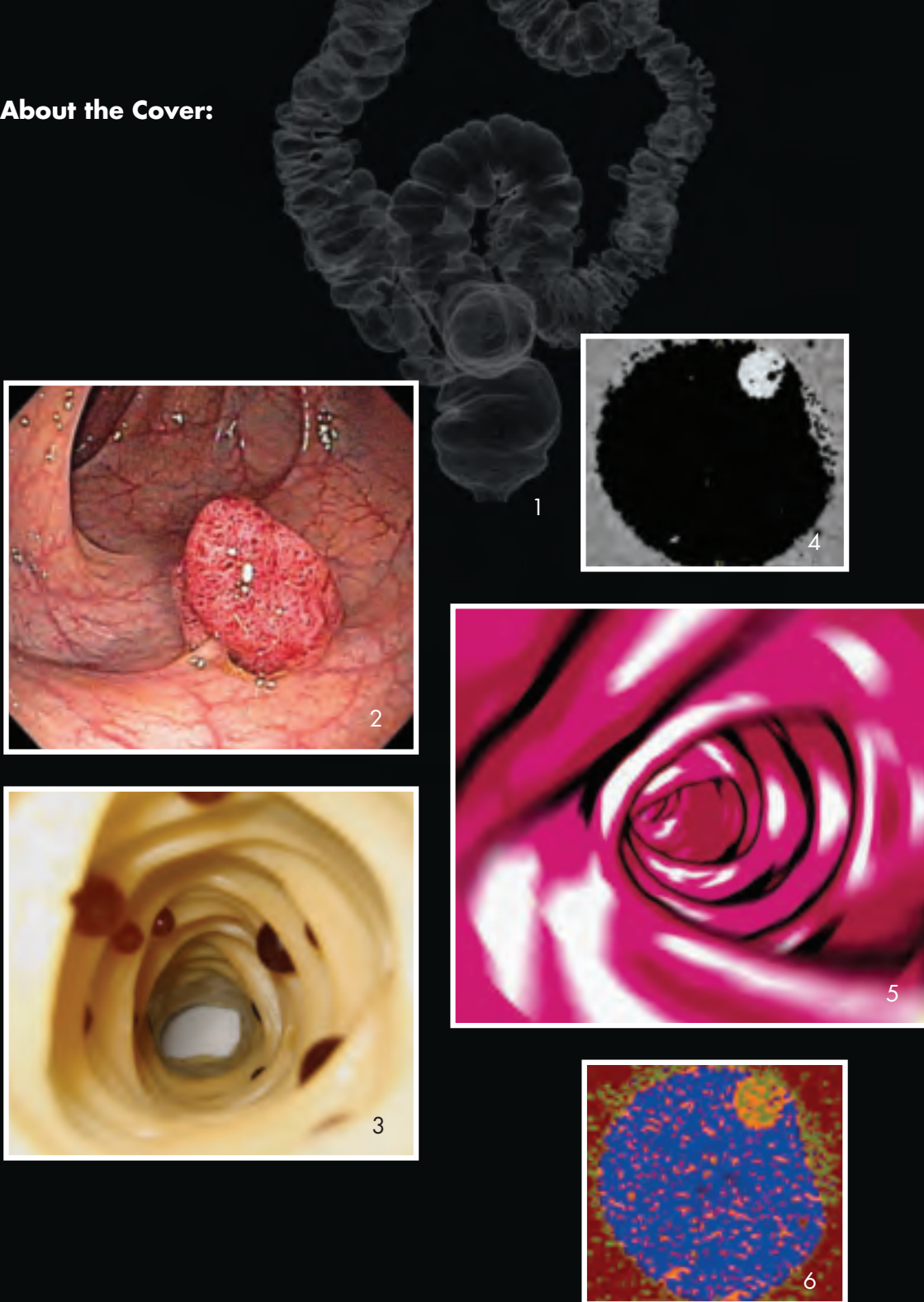IMAGES



UCSF

DEPARTMENT OF RADIOLOGY AND BIOMEDICAL IMAGING

About the Cover:



CT Colonography: Current and Future with Dual Energy CT

Image 1 shows a three dimensional virtual air contrast view of the entire colon at conventional CT colonography. Image 2 is an optical colonoscopic image of a polyp. Image 3 is an endoluminal view of a prototype phantom colorectal sleeve used to test the abilities of dual energy digital subtraction to distinguish stool from polyps. Image 4 demonstrates electronic stool subtraction based on dual energy removal of tagged stool in the phantom model. Image 5 exhibits a color sketch endoluminal view from a conventional CT colonography exam. Image 6 demonstrates dual energy color-coding of tagged-stool as blue and soft tissue as tan/brown in a phantom CT model. The images are provided by Gaurav S. Desai, MBBS, Benjamin M. Yeh, MD and Judy Yee, MD.

TABLE OF CONTENTS

LETTER FROM THE CHAIRMAN

- 2 Introduction by Dr. Ronald L. Arenson

CLINICAL AND RESEARCH NEWS

- 4 Effective Screening for Colon Polyps by CT Colonography: Have We Only Just Begun?
- 8 New Agents for Hyperpolarized ^{13}C Metabolic Imaging
- 11 Preoperative Mapping of Functionally Eloquent Regions with Diffusion MRI and MSI
- 15 Evaluating Risk Factors for Nephrogenic Systemic Fibrosis in a Rat Model
- 18 Neuroimaging-based Approaches to Estimate Hip Fracture Risk

NEW FACILITIES AND TECHNOLOGY

- 22 A Big Year

DEPARTMENTAL UPDATE

- 24 Aslam Assumes Chief of CT Position at SF VAMC
- 24 Nelson to Co-Chair New Department
- 25 Sollitto Takes On Expanded Role in Clinical Operations
- 25 Yeh Appointed Assistant Chief of Radiology at SF VAMC
- 26 Diagnostic Radiology Residency Program
- 30 Nuclear Medicine Residency Program
- 31 Incoming Diagnostic Radiology Residents
- 36 Second, Third, and Fourth Year Residents
- 36 Nuclear Medicine Residents
- 36 Clinical Fellows/Instructors in Radiology
- 37 Radiology Resident Graduates, Class of 2009
- 38 Blumenkranz, Larson, and Park Earn Young Investigators' Awards from the Surbeck Laboratory of Advanced Imaging
- 40 New Faculty Appointments
- 42 Faculty on the Move
- 42 Faculty Roster
- 48 Honors and Awards
- 50 The Margulis Society
- 52 The Margulis Society Donors List
- 53 Retired in 2009
- 56 Alumni News
- 58 In Memoriam
- 59 Imaging Research Symposium and First Annual Bruce Hasegawa Award
- 60 The Lanna Lee Award
- 60 Henry I. Goldberg Center for Advanced Imaging Education
- 62 Radiology Postgraduate Education
- 64 Radiology Continuing Medical Education Calendar

RADIOLOGY RESEARCH

- 65 Research Directions and Recent Publications
- 83 Grants

Dear Colleagues and Friends of Radiology and Biomedical Imaging,

As I write this year, the UCSF School of Medicine, our campus, and indeed the entire University, is in the midst of an unprecedented financial crisis. I am sure those of you in California have read with alarm about the recent crisis in developing a state budget. As the state legislators grappled with the impact of an overall economic downturn, they turned their attention to the University of California, and slashed the UC budget by more than \$800 million. A combination of very unpalatable choices faced us, including the Regents' decision to implement an across-the-board salary reduction and furlough plan.

It is an understatement to say that the choices we face in implementing a salary reduction of this magnitude have been unpopular. We clearly need to keep the clinical enterprise going, as well as fulfill our obligations under research contracts and grants. We owe our residents and other trainees an excellent experience, and we have no desire to move backward in any ranking of educational excellence or research prowess. I want to share a few thoughts and principles we are using in Radiology to move us through this difficult time.

Our clinical activity is a key driver of our ability to educate and to conduct research. Therefore, much of our focus in the past year has been on our exciting outpatient imaging joint venture with the UCSF Medical Center. Last fall, we developed a detailed marketing plan for the first time, and have been working diligently with the medical center marketing department to increase awareness of our services within the medical center and in the Bay Area community. As you read this issue of *Images*, you will see many examples of how our leading-edge research has led to clinical innovations. These are the activities we highlight at community dinners for referring colleagues, at conferences, and in grand round sessions throughout our own institution.

I want to commend Dr. Bill Dillon and the Neuroradiology section in particular, for developing an important and high-quality Precision Spine Center at China Basin. To read more about our efforts there, please visit our China Basin Web site at www.radiology.ucsf.edu/imagingcenter. In addition, Dr. Randy Hawkins and his colleagues in Nuclear Medicine have had impressive success in educating referring clinicians about PET/CT for cancer and cardiology applications, and have made sure we have a nuclear medicine specialist at every single tumor board in the institution.

In addition to marketing our clinical expertise, we continue to achieve amazing success in the research arena. Earlier this year, the campus gave official department status to the Department of Bioengineering and Therapeutic Sciences, co-chaired by our own Sarah Nelson, PhD. While Sarah undertakes this role in very challenging times, I am confident of her success. I am looking forward to working with the new department on, among other things, clinical translational efforts. In the spring, the Department submitted more than 47 grant applications for American Recovery and Reinvestment Act (ARRA) funds. By this fall, we received word that 11 of the grants, or 23 percent, had received funding. On campus overall, the success rate is closer to 15 percent. Ten investigators in the department received nearly \$5.5 million in funding from the ARRA. In addition, Michael Weiner, MD, at the Veterans Affairs Medical Center, continued his stellar funding track record with a \$24 million General Opportunities (GO) grant. With nearly \$30 million in ARRA-related funding, UCSF Radiology and

Biomedical Imaging outpaced all other academic radiology departments in the country. And, many of these ideas will be developed into longer-term research grant applications. Our research faculty demonstrated a tremendous amount of creative energy during this process.

Education will always be essential to who we are and what we do. While this year brought some restructuring of faculty time in the Goldberg Learning Center, I am sure that an even better experience waits for many UCSF medical students who discover the discipline of radiology through the Center. I have asked Dr. Judy Yee to lead a review of the program this year, with a goal of increasing the number of UCSF students we attract into Radiology. I am also proud of the excellent residency review experience we had this past year. Drs. Aliya Qayyum and David Avrin worked very hard with our staff, the residents, and section leadership to assure our success. Once again, I am most grateful to the Margulis Society for all it does to help us provide an outstanding experience for residents. Your support is even more appreciated during these challenging times.




Finally, we are exploring new and exciting mechanisms for staying in touch. I'm sure you are already very familiar with our excellent Radiology postgraduate education programs (see www.radiology.ucsf.edu/postgrad for the current calendar). A discussion of promoting upcoming courses and course announcements drove us to generate our first "tweets" on Twitter. I hope you'll think about following us at www.twitter.com/ucsfradiology. Take a look and let us know what you think!

I again invite you to join us in Chicago on the Sunday after Thanksgiving for our annual RSNA reception. This year we will gather in a true historic landmark, the Frank Lloyd Wright-designed lobby of the Rookery Building in Chicago's Loop. Please come by and enjoy the architecture and your friends and colleagues. We are always happy to see you and hear about your accomplishments.

Please enjoy this 2009 issue of **Images**, and let us know how your own careers and practices are doing as we face the many challenges ahead. Thank you for your support of the Department of Radiology and Biomedical Imaging. Please let us know how we can help you feel even more connected.

Sincerely,


Ronald L. Arenson, MD

EFFECTIVE SCREENING FOR COLON POLYPS BY CT COLONOGRAPHY: HAVE WE ONLY JUST BEGUN?

By Gaurav Desai, MBBS; Judy Yee, MD; Rizwan Aslam, MB, ChB; Yanjun Fu, PhD; John A. Shepherd, PhD; Benjamin M. Yeh, MD

Despite the knowledge that effective screening greatly reduces the risk of developing invasive colorectal cancer, it remains the third most common cause of cancer death in America and worldwide. Each of the currently available colon cancer screening methods has drawbacks. Fecal occult blood testing is quick and non-invasive, but only detects 20 to 70% of colon cancers, and is subject to false positives due to diet and non-cancerous causes of fecal blood. The double-contrast barium enema is accepted by the United States Centers for Medicare and Medicaid Services and most insurance policies, but has only 45 to 60% sensitivity for polyps and is inadequate for staging tumors. And conventional colonoscopy, which is touted by many as the gold standard for colon cancer screening, has a 10% failure rate for reaching the farthest extent of the colon, a 5 to 10% miss-rate for polyps, and a 0.1% rate of complications such as colon perforation. Furthermore, conventional colonoscopy requires a colonic cathartic preparation

that many people regard as unpleasant. The risks for injury are higher for debilitated patients and have led to recommendations that debilitated patients or those older than 75 not undergo colon cancer screening, even though life expectancy continues to increase.

Computed tomography colonography, previously called “virtual colonoscopy,” is emerging as a safe and reliable colon cancer and colonic polyp screening modality. The benefits of CT colonography include excellent patient tolerance, a near-negligible acute complication rate, the ability to image the entire colon, even beyond obstructing masses, and the ability to stage tumors and screen for lymphadenopathy or other intra-abdominal pathology. While several multi-institution trials have confirmed the excellent sensitivity of CT colonography for polyps in an average-risk screening population, drawbacks of CT colonography include the need to follow up with conventional colonoscopy in the 5% of patients

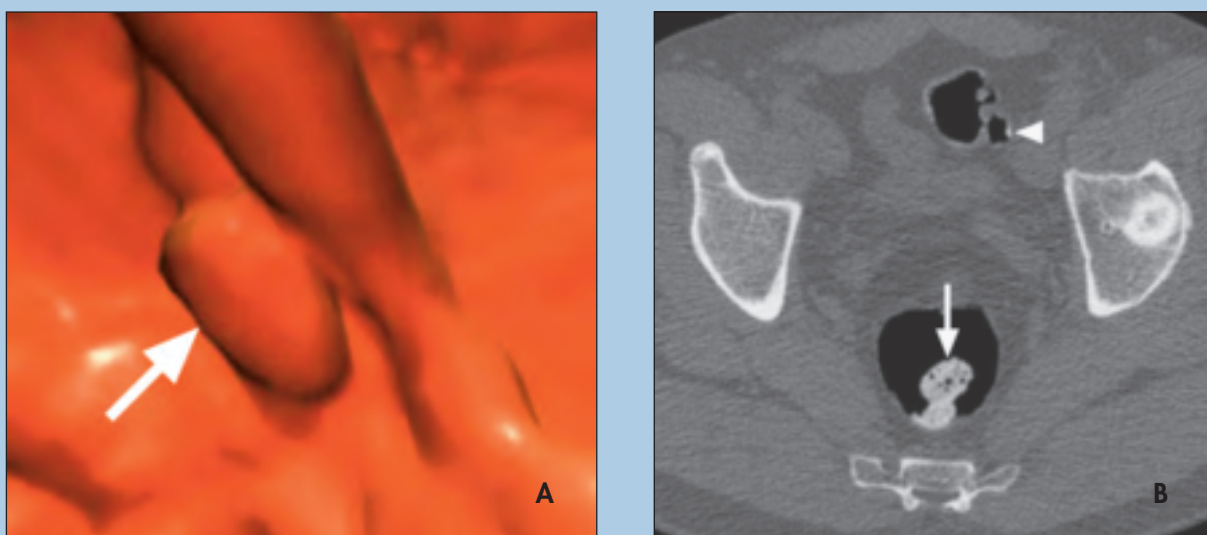


Figure 1. Demonstration of digital stool subtraction. (A) Three-dimensional CT colonography image appears to show a large polyp in the rectum (arrow). (B) The corresponding axial view shows that what appeared to be a polyp has high attenuation (arrow), which is consistent with “tagged” stool rather than

who have polyps at screening, and the need for a cathartic preparation similar to that used in conventional colonoscopy. Furthermore, given the cost of health care in the United States, some have raised the concern that CT colonography may discover extracolonic findings such as aortic aneurysms, renal masses, pulmonary nodules, and other “incidentalomas” that may require expensive further workup, thus contributing to health care costs. Others have pointed to the concern of exposing patients to radiation during CT colonography.

Into this mix, several exciting advances in CT promise to alter the way that CT colon cancer screening is perceived. These advances include low-radiation dose CT scanning, non-cathartic CT colonography, and dual-energy CT.

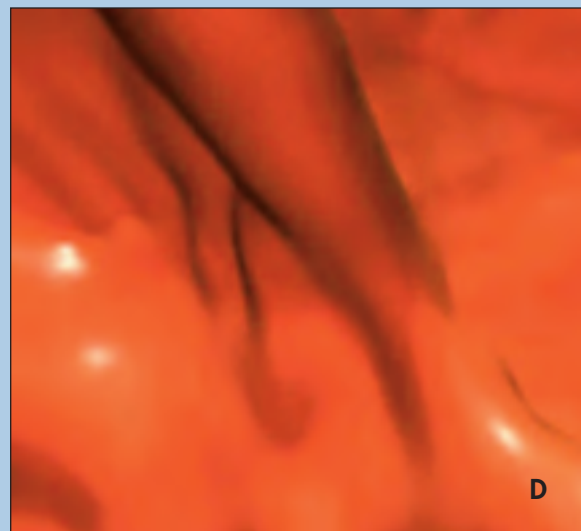
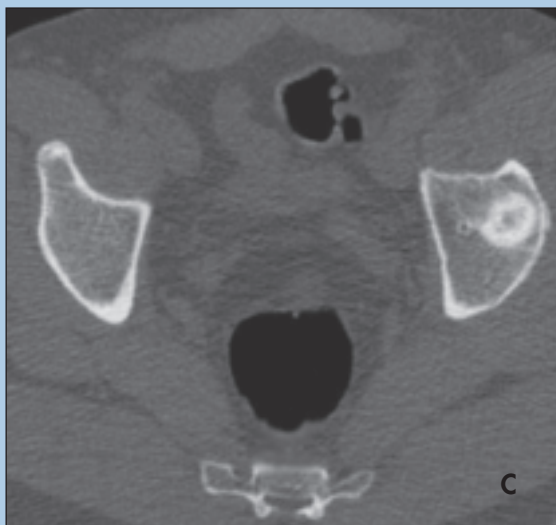
Low-Radiation Dose CT

CT imaging is based upon exposing patients to ionizing radiation from many different angles to determine the extent of X-ray absorption from each angle. These image data are then back-projected to form two- and three-dimensional representations of patient anatomy. For a typical CT colonography examination, two separate passes of the CT scanner are obtained through the abdomen and pelvis, one in the supine (face up) and one in the prone (face down) position. For general diagnostic imaging, multi-pass CT scans of the abdomen and pelvis may deliver up to 30 mSv of radiation dose to the patient when detailed evaluation of anatomy is required. These studies are among the highest radia-

tion-dose examinations performed for medical diagnosis. While no large-scale epidemiological studies have been performed to show that such CT radiation doses actually harm patients, models of lifetime risk extrapolated from nuclear bomb survivor data have suggested that radiation exposure may increase the risk for cancer in later life, particularly for young patients. As such, there is much interest in reducing patients' exposure from medical imaging, and particularly from screening examinations performed on healthy patients.

The simple approach to dose reduction is to reduce the current delivered to the CT X-ray tube, thereby linearly reducing radiation dose. Preliminary studies have shown that a reduction of the tube current down to 50 mA (as opposed to 250 mA for a typical diagnostic CT of the abdomen) may give acceptable images for the purpose of identifying polyps; ongoing trials are evaluating whether even lower-dose CT may be acceptable.

Another approach to radiation dose reduction is to apply a more computationally intensive CT image reconstruction algorithm than is currently employed for clinical CT imaging. Iterative image reconstruction methods have been used for decades to generate improved images for nuclear scintigraphy examinations where images need to be generated from a relatively low amount of detected signal. When adapted to CT imaging, excellent image quality can be generated with a fraction of the radiation dose required for typical CT. However, these algorithms require much more



a polyp. Additional tagged stool is seen elsewhere in the sigmoid colon (arrowhead) (C) The same image, processed with digital subtraction of tagged stool, shows removal of the tagged stool from the image. (D) The corresponding 3D image after digital subtraction of tagged stool no longer shows the false polyp.

time to generate images (hours to days), particularly when very large stacks of thin images, as required for CT colonography, are being reconstructed. It is hoped that improvements in reconstruction heuristics, as well as faster parallel-processing computers, will bring this technology to clinical usage in the near future.

Non-cathartic CT Colonography

Patients who have undergone conventional colonography or barium enema typically remember the cathartic preparation as an uncomfortable, and perhaps undignified, portion of the screening examination. Unfortunately, a well-cleansed colon is critical for visualizing smaller colonic polyps using these screening methods, since retained stool may obscure the colonic mucosa. Similarly, for standard CT colonography, a dry, well-cleansed colon provides the best visualization of subtle mucosal abnormalities. However, this preparation may deter many patients from being screened for colon cancer.

Attempts to perform CT colonography screening in patients who have not had a colonic cleansing cathartic preparation have met with suboptimal results, with substantially reduced sensitivity and specificity for polyps in small populations of patients. An alternative technique for a “non-cathartic” CT colonography examination is to give patients oral CT contrast material with meals on the days prior to imaging. As the CT contrast material mixes with undigested food in the bowel it “tags” the stool, allowing the interpreting radiologist to distinguish a suspicious polyp or cancer from normal enteric contents. This approach can be made more user-friendly by computerized digital subtraction of high-attenuation tagged material from the colon lumen (Figure 1). Such software is available from multiple vendors. While early studies have been promising, the success of this approach depends

on excellent stool tagging. Since poorly or moderately tagged stool may introduce artifacts that simulate or obscure true lesions. Furthermore, some CT contrast material may also adhere to the colonic mucosa, further complicating image interpretation.

Dual-Energy CT

An alternative method to distinguish intraluminal stool from colonic polyps is to exploit differences in the X-ray attenuation profile of stool compared to soft tissue. We know that tissue contrast will change based on the maximum tube potential setting of the X-ray tube, and that these settings can be adjusted to optimize visualization of abdominal findings. Dual-energy CT obtains images of the object of interest using two different maximum X-ray tube potentials, typically 80 or 100 kVp versus 140 kVp. The resultant X-ray spectra interact with the molecules of the imaged object and are absorbed with a characteristic profile that depends on the atomic composition and configuration of its component molecules. In other words, based on the amount of X-rays absorbed at each of the two CT tube potential

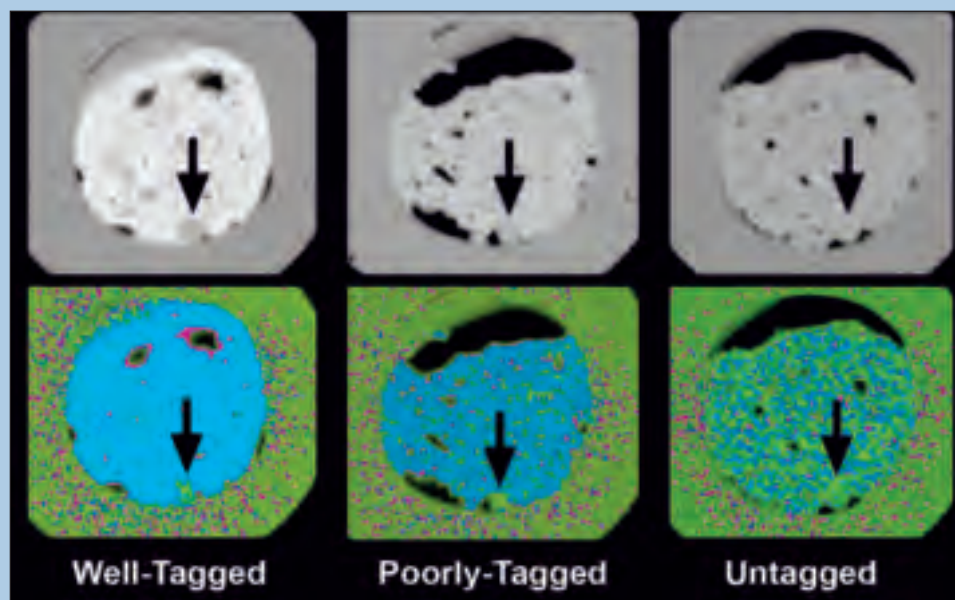


Figure 2. Dual-energy CT electronic stool subtraction. An experimental colon model with an 8 millimeter polyp (arrow) was scanned three times using the dual-energy CT colonography technique and with well-tagged, poorly tagged, or untagged stool (top row). At regular CT colonography, it is difficult to identify the polyp when the stool is poorly or untagged. The bottom row shows dual-energy CT stool maps where soft tissue is color-coded green, and stool is color-coded blue. With the dual-energy CT overlay, the polyp can be more confidently seen with the poorly tagged and untagged scans. Some image noise is present due largely to the use of a low-radiation dose CT imaging technique.

settings, the materials within the imaged object can be “decomposed” and differentiated.

UCSF was among the first to study the clinical application of dual-energy imaging in the 1970s. However, only recently have CT scanners become capable of near-simultaneous dual-energy CT imaging. These advances in CT now allow for practical material decomposition with routine scanning, such that contrast material can be electronically and qualitatively distinguished from soft tissues and bone.

A natural extension of this technology is to utilize dual-energy scanning to electronically subtract stool away from CT colonography images, thereby emphasizing polyps and cancers. Prior to clinical testing, this method needs to be validated. At UCSF, we constructed a durable colonic simulation “phantom” that resembles the CT X-ray attenuation of the colon and polyps. This phantom enabled us to rigorously test dual-energy CT imaging using a range of luminal tagging, from non- to poorly to well-tagged contents on identical colon phantoms (Figure 2). The result of this experiment showed that reader confidence and accuracy for detecting polyps improved for colon phantoms with non-tagged and poorly tagged contents. Since the accuracy was quite high for moderately and well-tagged contents, a statistically significant difference was not seen for these latter categories. This phantom model paves the way for dual-energy CT to be used in clinical trials, and in particular, shows that it may be of most benefit when stool tagging is suboptimal.

Osteoporosis Screening

A potential benefit of CT colonography is its ability to evaluate structures outside of the colon that may affect patient health. In fact, new, clinically relevant extracolonic diagnoses are found in up to 2.5% of adults undergoing CT colonography screening. At UCSF, ongoing studies are underway to validate the usefulness of CT colonography to screen for osteoporosis, a leading preventable cause of morbidity and mortality. Work conducted at the San Francisco Veterans Administration Hospital and presented at the 2009 Radiological Society of North America, confirmed that CT colonography images can be used as a check for evidence of osteoporosis and that there is excellent

agreement between DEXA bone mineral density scores and the spine quantification scores from the CT colonography exams. Both tests identified similar levels of osteoporosis in the study population. Refinement and further validation of the measurement techniques are underway and may potentially allow early detection and treatment monitoring of osteoporosis.

Conclusion

While colorectal carcinoma is a common and deadly malignancy that can be prevented by effective population screening, current methods are not utilized by large segments of the population. Potentially, the development of improved screening methods that are acceptable to both patients and insurance carriers will reduce the mortality of this disease. CT colonography, which has already shown proven effectiveness for colon cancer screening, continues to be refined as CT technology evolves. In particular, the radiation dose of CT colonography will decrease as new CT reconstruction algorithms improve, the colonic preparation will become less onerous as stool tagging and dual-energy CT become integrated, and the benefits of non-colonic CT screening, such as for osteoporosis, will provide added value.

Gaurav S. Desai, MBBS, was a junior specialist in the Department of Radiology and Biomedical Imaging; Benjamin M. Yeh, MD, is an associate professor and assistant chief of Diagnostic Radiology at the San Francisco Veterans Affairs Medical Center; Rizwan Aslam, MB, ChB, is an associate professor and chief of CT Imaging at the San Francisco VAMC; Yanjun Fu, PhD, is an assistant research scientist in the UCSF Department of Radiology and Biomedical Imaging, Center for Pharmaceutical and Molecular Imaging; John A. Shepherd, PhD, is an assistant adjunct professor in residence in the UCSF Department of Radiology and Biomedical Imaging; Judy Yee, MD, is professor and vice chair of Diagnostic Radiology at UCSF and chief of Diagnostic Radiology at the San Francisco VAMC.

NEW AGENTS FOR HYPERPOLARIZED ^{13}C METABOLIC IMAGING

By David M. Wilson, MD, PhD; Kayvan R. Keshari; Peder E. Z. Larson, PhD; Simon Hu; Ilwoo Park; Ralph E. Hurd, PhD; Sarah Nelson, PhD; Daniel Vigneron, PhD; John Kurhanewicz, PhD

Introduction

Hyperpolarized magnetic resonance metabolic imaging using dynamic nuclear polarization (DNP) is unprecedented in its ability to probe metabolic fluxes in real time by providing ~50,000-fold signal enhancement for specific ^{13}C enriched compounds. Studies employing the DNP prototype $[1-^{13}\text{C}]$ pyruvate have demonstrated altered metabolism in animal tumors, allowing cancers to be detected and graded *in vivo*, as well as monitoring response to therapy. In addition, the agents used in hyperpolarized ^{13}C MRI have other important advantages over contrast agents currently in clinical use. Since endogenous molecules are utilized, these agents are expected to have little or no toxicity in humans, even at relatively high concentrations. This feature is particularly appealing given recent concerns about contrast nephropathy associated with iodinated CT contrast, as well as nephrogenic systemic fibrosis (NSF) seen in patients receiving gadolinium chelate contrast agents for MRI. Recent studies at UCSF have focused on expanding the arsenal of available hyperpolarized ^{13}C agents. These latest advances include the hexose probe $[2-^{13}\text{C}]$ fructose, techniques for simultaneous multi-agent polarization, and the pyruvate prodrug $[1-^{13}\text{C}]$ ethyl pyruvate for metabolic imaging of the brain.

Hyperpolarized Fructose: A New DNP Substrate for *In Vivo* Metabolic Imaging

The short T_1 relaxation of ^{13}C glucose carbons (< 1 sec) render it a poor probe for hyperpolarized ^{13}C imaging. In contrast, the $[2-^{13}\text{C}]$ fructose carbon was found to have a sufficiently long T_1 relaxation rate (≈ 16 sec) allowing high signal-to-noise (SNR) metabolic studies at 3T. The one-step metabolism via hexokinase to the phosphorylated fructose-6-phosphate is analogous to the first step of glycolysis, in which glucose is phosphorylated to glucose-6-phosphate. The metabolic flux to fructose-6-phosphate in the cell is related to downstream glycolytic metabolic events, as well as activity of upstream pentose phosphate pathway (PPP). The PPP is responsible for the predominant amount of nucleotide synthesis (which is increased at high turnover rates) and has also been postulated as a source of regeneration of NADPH in cancer cells, making them more resistant

to oxidative stress and allowing them to replenish glutathione. Furthermore, cellular uptake of fructose is implicated in the pathogenesis of specific types of cancer. Fructose also can be metabolized to the fructose-1-phosphate via fructokinase, a reaction that takes place primarily in the liver. Hepatic uptake is via the GLUT5 transporter, which demonstrates relative specificity for fructose. Expression of this transporter may be an important biomarker for disease in extrahepatic tissues. For example, GLUT5 is highly expressed in breast cancer cell lines, but not by normal breast tissue.

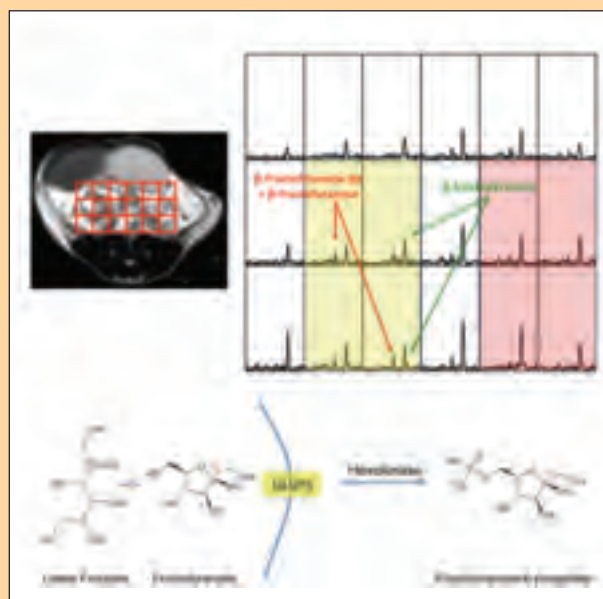


Figure 1. ^{13}C spectroscopic image of a prostate tumor (TRAMP) model, showing differential uptake and metabolism of fructose within the tumor as compared to surrounding benign tissues. Resonances corresponding to the β -fructopyranose and composite β -fructofuranose-6-phosphate and β -fructofuranose are shown. The yellow area demonstrates a region of diffuse tumor, compared to the benign red area (another lobe of the mouse prostate). Fructose is primarily transported into cells by GLUT5 and metabolized to fructofuranose-6-phosphate by hexokinase.

For animal studies at 3T, a concentrated [2- ^{13}C] fructose preparation was polarized to a high level (approximately 12%) using a Hypersense DNP polarizer. Figure 1 demonstrates metabolic studies following injection of 80mM of hyperpolarized fructose into a mouse prostate tumor (TRAMP) model. Spectroscopic imaging was performed 15s post-injection using a modified spin-echo sequence and 0.135cc voxels. The MRSI data demonstrated that the resonance corresponding to the composite β -fructofuranose and β -fructofuranose-6-phosphate were higher in the regions of tumor as compared to adjacent benign tissues. In turn, the ratio of this resonance to the β -fructopyranose resonance is increased relative to the surrounding tissues. This new hyperpolarized MR agent is exciting from the standpoint that cancer could be discriminated from normal prostate and surrounding tissues based on the detection of hyperpolarized β -fructofuranose-6-phosphate in this transgenic prostate cancer model. The enzymatic conversion of hyperpolarized fructose allows important changes in glycolytic metabolism upstream of pyruvate to be probed, including upregulated hexose uptake, hexokinase activity, and changes in flux through the pentose phosphate pathway.

Multi-Agent Hyperpolarization Allows Simultaneous Assessment of Multiple Enzymatic Pathways *In Vivo*

Most hyperpolarized ^{13}C studies to date have focused on the last step of glycolysis in which [1- ^{13}C] pyruvate is enzymatically converted to a number of products, including [1- ^{13}C] lactate mediated by the activity of lactate dehydrogenase (LDH). This pathway is associated with the Warburg effect, which postulates enhanced aerobic glycolysis to lactate in tumor cells relative to normal tissue. Additional agents showing promise in animals or perfused heart models include [2- ^{13}C] pyruvate, and [1- ^{13}C] lactate itself. As the number of useful DNP agents continues to expand, the ability to probe multiple pathways and mechanisms simultaneously may provide valuable metabolic “signatures” associated with specific tumor types and other non-oncogenic pathologies. ^1H MRS is well established as a means to establish metabolic profiles in diseased tissue *in vivo*, but hyperpolarized MR has the additional capacity to provide kinetic information. A particular hyperpolarized ^{13}C signature in diseased tissue may aid in targeting regions of pathology for biopsy or focal therapy. It might also better characterize the extent or aggressiveness of disease present before or after treatment.

Methods for simultaneously polarizing multiple ^{13}C -enriched metabolites were developed to probe several enzymatic pathways and other physiologic properties *in vivo*, using a single intravenous bolus. ^{13}C bicarbonate

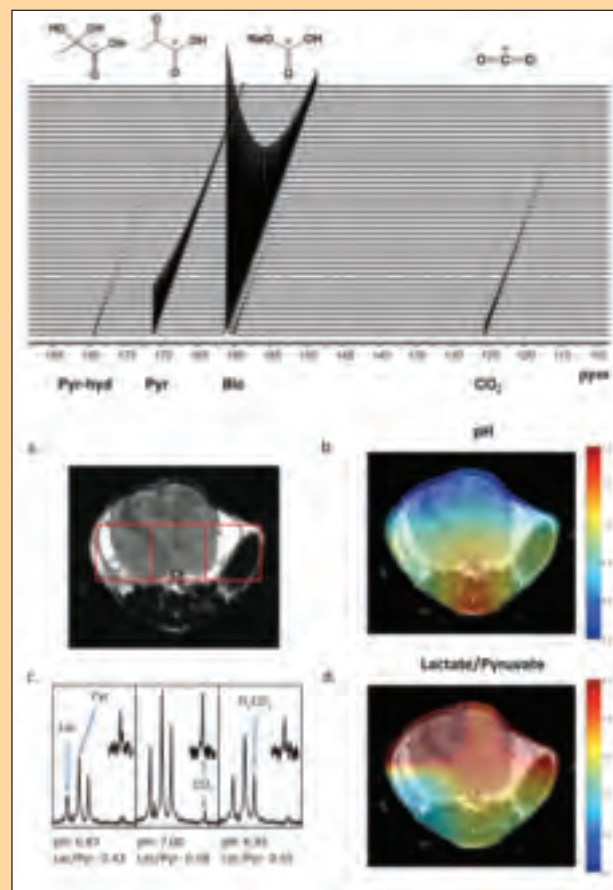


Figure 2. Injection of co-polarized ^{13}C bicarbonate and [1- ^{13}C] pyruvate into a prostate tumor (TRAMP) model at 3T. A T_2 weighted anatomic image (A), pH image of the same slice demonstrating the distribution of pH calculated (B), spectra for the corresponding voxels shown in the T2 weighted image (C) and the lactate/pyruvate ratio image (D) are shown. The pH for individual voxels was calculated using the Henderson-Hasselbalch equation and pK_a of 6.17 at 37°C . The peak ratios of observed ^{13}C lactate to ^{13}C pyruvate are shown beneath the corresponding spectra. Regions of the CO_2 resonance have been scaled up to demonstrate the signal-to-noise achieved in each voxel.

and [1- ^{13}C] pyruvate were polarized to a high level (16% and 18% respectively) and injected into normal mice and a TRAMP model at 3T, with the results shown in Figure 2. Integration of ^{13}C bicarbonate and ^{13}C CO_2 peaks, and application of the Henderson-Hasselbalch equation allowed calculation of pH on a voxel-by-voxel basis and the creation of pH images, as well as the corresponding hyperpolarized lactate images. In TRAMP mice, high levels of hyperpolarized lactate ($\text{Lac/Pyr} = 0.43$ to 0.58) and more acidic pH values ($\text{pH} = 6.87$ to 7.00 , Figure 3) were observed in the region of the prostate tumor as compared to surrounding benign abdominal tissues ($\text{pH} = 7.20$ to 7.49).

The co-polarization technique was extended to polarize four ^{13}C -labeled agents providing simultaneous information on pH, metabolism, necrosis, and angiogenesis, namely $[1-^{13}\text{C}]$ pyruvic acid, ^{13}C sodium bicarbonate, $[1,1-^{13}\text{C}]$ fumaric acid, and $[1-^{13}\text{C}]$ urea with high levels of solution-state polarization (10 to 20%)

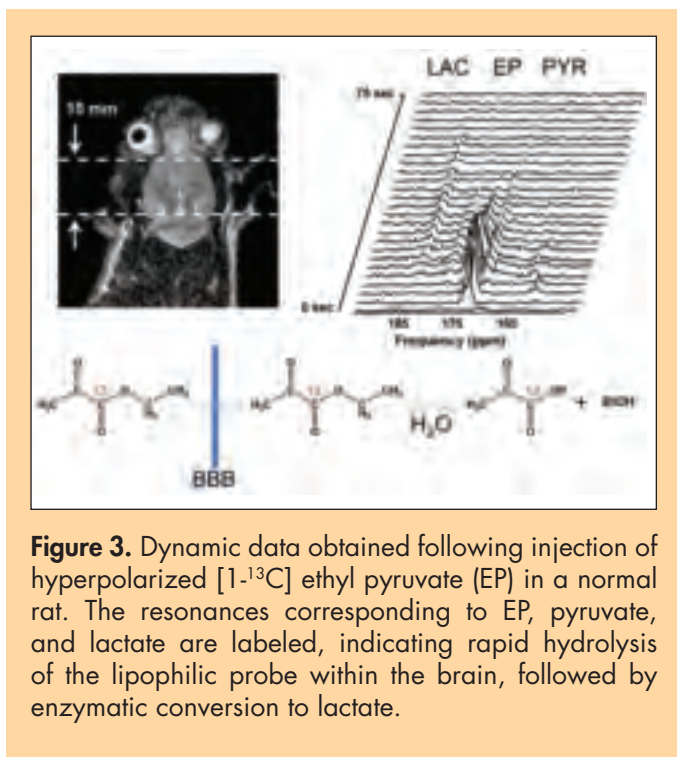


Figure 3. Dynamic data obtained following injection of hyperpolarized $[1-^{13}\text{C}]$ ethyl pyruvate (EP) in a normal rat. The resonances corresponding to EP, pyruvate, and lactate are labeled, indicating rapid hydrolysis of the lipophilic probe within the brain, followed by enzymatic conversion to lactate.

and spin-lattice relaxation values (30 to 50s) similar to those obtained with polarization of the individual hyperpolarized probes. Hyperpolarized ^{13}C urea has already been employed as an intravascular angiographic agent, and could be used in the described agent combination to assess tissue perfusion. $[1-^{13}\text{C}]$ fumarate represents a point of entry into the citric acid cycle. It has recently been shown to be a marker of treatment response through increased detection of hyperpolarized malate due to increased cellular necrosis after therapy. Simultaneous evaluation of enzymatic pathways and other physiologic properties is not easily achieved using other imaging methods including PET, optical imaging, or other targeted MR methods. In addition, concerns about toxicity have limited the proliferation of other intravenous imaging agents, while the endogenous ^{13}C agents included in this multi-polarization approach are anticipated to have no adverse effects in humans. As additional new ^{13}C agents are developed, multi-agent polarization will be a powerful method of probing multiple metabolic pathways and other physiologic properties simultaneously, in a single MR scan lasting only seconds.

Ethyl Pyruvate: A Lipophilic Pyruvate Precursor for Metabolic Imaging of the Brain

MR studies employing hyperpolarized $[1-^{13}\text{C}]$ pyruvate in a rat glioma model have revealed striking conversion to $[1-^{13}\text{C}]$ lactate, consistent with the ^1H MRS spectra seen in aggressive tumors. However, these hyperpolarized studies rely on a leaky blood-brain-barrier (BBB) for pyruvate entry into the brain. The brain uptake index (BUI, a measure of metabolite in brain vs. blood), as reported for pyruvate in a normal anesthetized rat brain 10s after an arterial injection, suggests that even at the very highest intravascular doses possible, less than 1mM pyruvate would be transported into brain tissue.

An alternative approach is to use ethyl pyruvate (EP), a lipophilic analogue of pyruvate that is expected to transport faster across the blood-brain barrier. Ethyl pyruvate is a food additive and an anti-inflammatory compound with therapeutic potential, which has been shown to attenuate kainic acid-induced neuronal cell death in the mouse hippocampus and to reduce the impact of stroke. Under conditions of slow IV infusion, both animals and humans tolerate large doses of EP.

Figure 3 presents initial animal data at 3T. $[1-^{13}\text{C}]$ EP was polarized to approximately 20% and injected at 50mM into a normal rat, with dynamic spectra obtained every 3s through the brain. As anticipated, high SNR spectra EP were observed initially, followed by conversion to $[1-^{13}\text{C}]$ pyruvate by 9s and subsequent metabolism to $[1-^{13}\text{C}]$ lactate. These studies are consistent with rapid entry of EP into the brain, followed by hydrolysis to the desired endogenous metabolite. Future studies will focus on improved metabolic characterization of infiltrating glioma, stroke, and inflammatory conditions such as multiple sclerosis, diseases for which the BBB is highly variable and often intact.

David M. Wilson, MD, PhD, is a clinical fellow in the Neuroradiology Section; Kayvan R. Keshari is a staff research associate; Peder Larson, PhD, is a post-doctoral scholar and Simon Hu is a graduate student in the MRI/MRS Specialized Resource Group. Il-Woo Park is a graduate student researcher; Ralph E. Hurd, PhD, is chief scientist, and director Biochemical Imaging Laboratory GE Healthcare; Sarah J. Nelson, PhD, is the Margaret Hart Surbeck distinguished professor in Advanced Imaging and director, Surbeck Laboratory; Daniel Vigneron, PhD, is a professor in residence; John Kurhanewicz, PhD, is a professor in residence and co-director, Prostate Cancer Research Interest Group in the Department of Radiology and Biomedical Imaging.

PREOPERATIVE MAPPING OF FUNCTIONALLY ELOQUENT REGIONS WITH DIFFUSION MRI AND MSI

By Roland G. Henry, PhD; Bagrat Amirbekian, BS; Jeffrey I. Berman, PhD; Monica Bucci, MD; Anne M. Findlay, MA; Christopher Nguyen, BS; Mitchel S. Berger, MD; Srikantan S. Nagarajan, PhD

Structural and functional connectivity are emerging as important tools for oncological neurological imaging. In particular, brain tumor patients have benefited from surgical treatment guided by functional and structural neurological imaging. More recently, diffusion magnetic resonance imaging (dMRI) has emerged as a vital tool for surgeons using intra-operative electrical stimulation (IES) to map eloquent white-matter pathways to be spared during tumor resection. Magnetic source imaging (MSI) has been used to inform mapping over cortical areas. New exciting methods to predict which areas may be safely removed without postoperative deficits are being developed in the Department of Radiology and Biomedical Imaging at UCSF. Our goals are to improve preoperative delineation of cortical regions and their subserving white-matter pathways vital to functionality, and to use functional and structural connectivity to predict the relation of these pathways to potential motor deficits.

Improving and Quantifying the Accuracy and Precision of Preoperative Diffusion Fiber Tracking

At UCSF, we pioneered the use of dMRI fiber tracking for preoperative mapping of motor pathways in brain tumor patients. A UCSF research program between Radiology (Roland G. Henry, PhD, and Jeffrey I. Berman, PhD) and Neurological Surgery (Mitchel S. Berger, MD) that started almost a decade ago was successfully translated to a clinical service. This unique service began offering state-of-the-art preoperative mapping of motor pathways long before

such functionality was available commercially. Even now, this rapidly progressing area continually surpasses the commercial products; nonetheless, our program provides these improved methods for neurosurgeons at UCSF. Similarly, Sri Nagarajan, PhD, and colleagues continue to develop novel and powerful algorithms for MSI that enable high-fidelity reconstructions of videos of brain activity in awake, behaving humans. These algorithms have vastly improved the reliability and resolution of brain activity reconstructions and associated functional connectivity, and the capability of preoperative MSI to predict “eloquent cortex,” the regions of the brain that subserve language function. (Functional connectivity refers to the correlated activity across different brain regions that defines common distributed brain networks underlying different behavioral functions.)

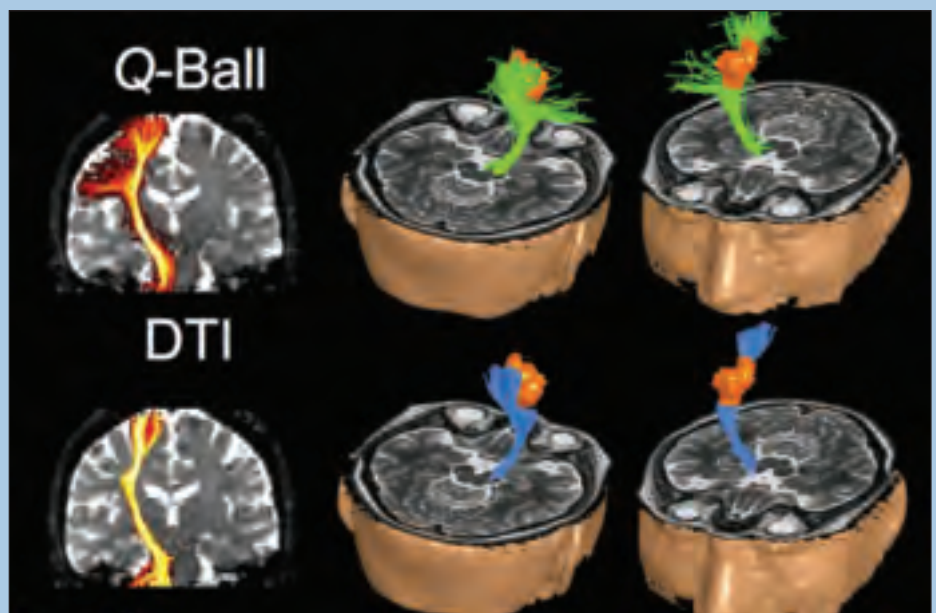


Figure 1. Comparison of HARDI/Q-Ball (green) and DTI (blue) fiber tracking of the CST in a brain tumor patient. The tumor is shown in gold. Note that the lateral motor pathways are delineated with the HARDI/Q-Ball but not the DTI fiber tracking. The red to yellow colors of the fiber tracks represent increasing number of streamlines.

Below, we present recent advances in combining preoperative mapping with dMRI and MSI. The maps of at-risk white-matter pathways are provided preoperatively and used both in planning resections (i.e., identifying the manner of displacement of white-matter pathways) and as a guide to mapping these pathways during surgery with intraoperative electrical stimulation. Without the dMRI fiber tracking data, IES motor mapping is an extremely laborious activity, which requires periodically stimulating the tissue to investigate the presence of white-matter motor pathways. After each bit of tissue is resected, this procedure must be repeated across a grid (1cm spacing) to ensure that the margin of resection does not include vital white-matter pathways. With dMRI predictions, the neurosurgeon can more quickly, and safely find the white-matter motor pathways with IES, thereby improving the efficiency and accuracy of intraoperative mapping. In the end, the presence and location of at-risk motor pathways in the white matter is determined by the IES, not by the preoperative diffusion MRI fiber tracks, and the stimulation is generally used to determine the safe margin of a resection.

Despite tremendous advances in acquisition and post-processing algorithms, there is still substantial need for improvement in preoperative fiber tracking with dMRI. Conventional deterministic diffusion tensor imaging (DTI) algorithms are not useful in delineating the lateral portions of the corticospinal tract (CST) serving motor function, due to the complexity of the white-matter structure leading to these areas. We can reconstruct more complicated diffusion profiles pres-

ent with crossing fibers, by employing probabilistic and high-angular resolution dMRI data. We have developed fiber tracking based on the HARDI reconstruction and these new methods dramatically improve the mapping of lateral CST pathways (Figure 1).

Another area of improvement in preoperative fiber tracking comes from combining functional information to identify regions that may be difficult to identify in patients with brain tumor. These regions are used to constrain the fiber tracks, therefore lending greater confidence to the results. Recent work from Sri Nagarajan's lab indicates that utilizing the unique temporal resolution MSI enables highly sensitive and specific localization of the motor cortex.

An ongoing collaboration between the laboratories of Drs. Henry and Nagarajan recently showed that incorporating preoperative motor MSI increases our ability to confidently delineate the CST with dMRI fiber tracking. A retrospective study demonstrated that by identifying cortical motor regions using MSI, we significantly improved delineation of the corticospinal motor tracts (Figure 2). These data also demonstrate the advantage of using HARDI fiber tracking methods rather than DTI. In this figure, we show the fraction of successful tracking with seed regions in the cerebral peduncle targeted to the motor cortex, compared to seeding at the MSI-indicated cortical region targeted to the cerebral peduncle. The figure also shows the results for HARDI compared to DTI fiber tracking, which demonstrates the improved accuracy of tracking with HARDI fiber tracking, especially when MSI-identified motor areas are present.

Another aspect of validating preoperative fiber tracking comes from retrospectively comparing the preoperative maps with intraoperative stimulation points. These stimulation points provide a gold standard for the presence of functional motor areas. We have used these data to determine the subcortical accuracy and precision of preoperative fiber tracks by comparison with IES points in the deep white matter. Cortical IES points are also used to determine the false negative rate of the preoperative fiber tracking (much as in Figure 2 with preoperative MSI). The accuracy of the IES points relative to preoperative dMRI is affected by the current spreads and tissue shifts. However, we are concerned less with absolute accuracy, than with the information that enables more efficient intraoperative stimulation mapping. Our previously published data showed that, even including the effects of tissue shifts and the current spread, DTI deterministic fiber tracking predicted the location of the at-risk white-matter fiber tracks with an offset of 9 ± 3 mm. This 9mm offset indeed points to current spread and tissue shifts as affecting the absolute accuracy; however, there is very little variance (± 3 mm)

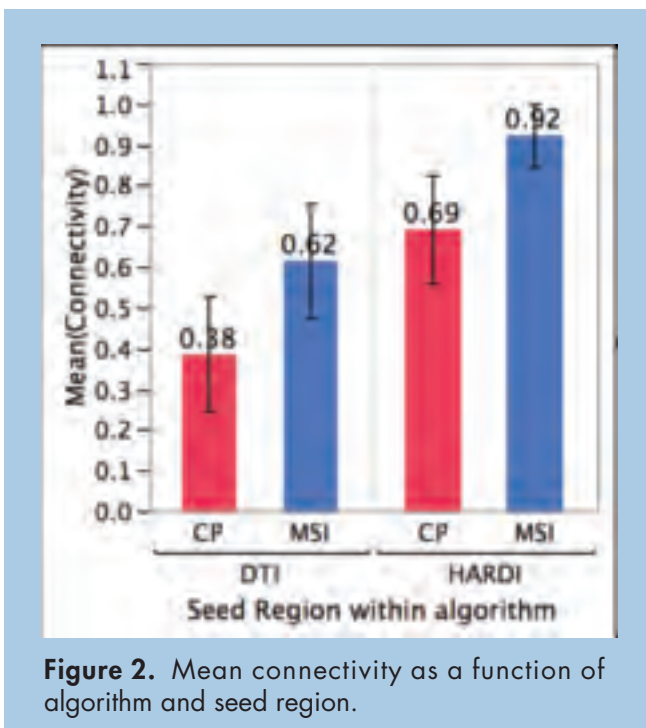


Figure 2. Mean connectivity as a function of algorithm and seed region.

in the distance between the preoperative dMRI fiber tracks and IES stimulation points. This measure already includes the current spread from the electrodes and the tissue shifts. Therefore, the surgeon knows that when the resection approaches 1cm of the fiber tracks on the preoperative MRI, a positive stimulation is predicted. This is precisely the manner in which the preoperative data can be useful during resection of deep white matter where the margins are close to motor fibers. Clearly, precision is an important determinant of preoperative fiber tracking.

Resting-State MSI Predicts Surgical Deficits

Recent developments in structural and functional connectivity analyses now promise even greater poten-

tial for their use in determining the functional impact of these regions. Recent work in the Nagarajan lab indicates the ability of preoperative, resting-state MSI measures of functional connectivity to predict those cortical network disruptions that may lead to postoperative deficit. Based on the hypothesis that damaged brain tissue is disconnected in the physiological interactions from healthy areas, this study aimed to map the functionality of brain areas according to their functional connectivity with other areas. Magnetoencephalographic (MEG) recordings during resting state were obtained from 15 consecutively analyzed patients with focal brain lesions and from 14 healthy controls. Neural activity at each voxel in the brain was estimated from the recordings of all MEG channels using adaptive spatial

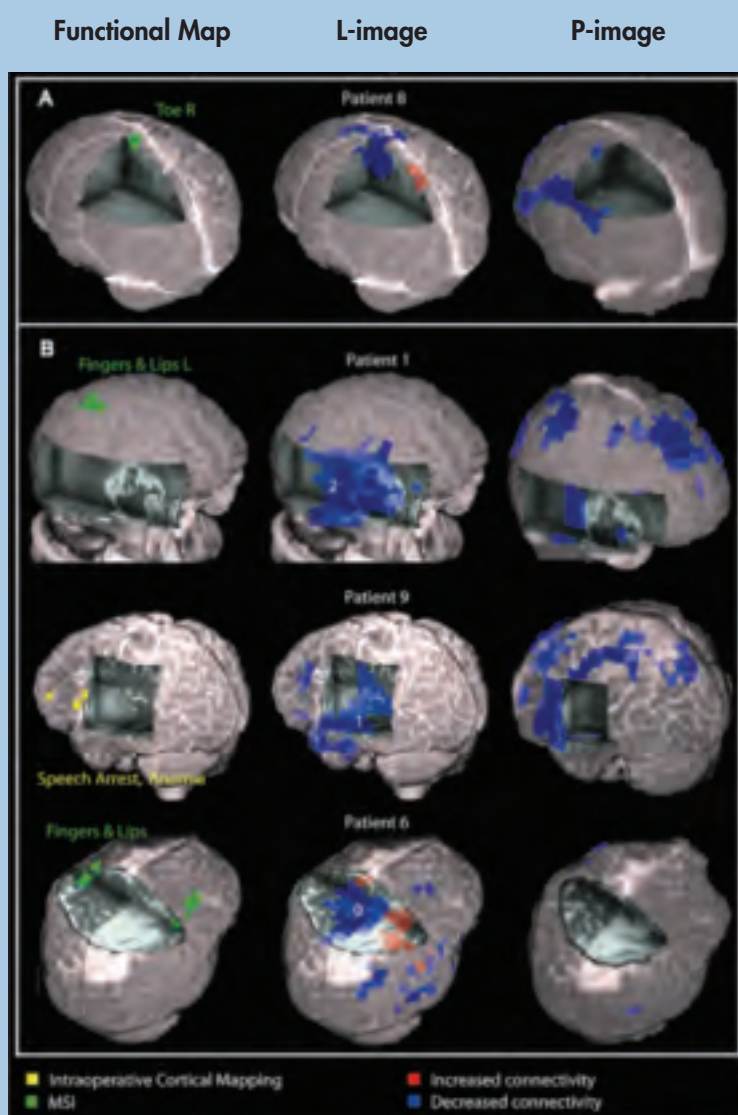


Figure 3. Functional maps obtained with magnetic source imaging or intraoperative cortical mapping as well as two different kinds (L and P) of images of functional connectivity in 4 patients with brain tumors superimposed over their 3D-rendered individual brain. The L, or lesion-specific image, of connectivity (middle column) is normalized to contralateral regions and the P, or patient-specific image, of connectivity (right column) is normalized to like regions in normal controls. (A) Twenty-five-year old woman with a central paresis of the right foot due to an astrocytoma WHO grade III that infiltrated the left medial sensorimotor cortex. Note that the L-image displays a corresponding decrease in functional connectivity in the sensorimotor cortex of the right foot. (B) The L-images of these 3 tumor patients without pre-surgical functional deficits indicate functional disconnection (in blue) of different proportions of the corresponding tumor tissue (graded 0-2, with 0 indicating smallest proportion with disconnection). In agreement with the L-images and the clinical status, functional cortex was mapped outside of disconnected (blue) areas by MSI and cortical mapping in all patients. In addition, L-images predicted the functional status after radical surgery: whereas patient 6 suffered from post-surgical sensible deficits in the left arm and leg, no deficits were observed in patients 1 and 9. P-images show diffuse or scattered areas with significantly lower connectivity estimates than a healthy control population, but these areas are unrelated to tumor location and brain regions with functional deficits.

filtering techniques. The functional connectivity of each brain voxel was then estimated by calculating the mean imaginary coherence of all its connections. The magnitude of imaginary coherence was greatest in the alpha frequency range corresponding to the human idling rhythm. In healthy subjects, functionally critical brain areas such as the somatosensory cortex and language areas were associated with the largest functional connectivity estimates in the alpha range. Patients with lesion-induced functional deficits displayed decreased connectivity estimates in the corresponding brain area, as compared to contralateral intact tissue. In tumor patients without neurological deficits, brain areas showing decreased functional connectivity estimates could be surgically resected without the occurrence of post-surgical deficits. When compared to healthy controls, all lesion patients had diffuse or scattered brain areas with decreased functional connectivity (see Figures 3 and 4). Therefore, non-invasive measures of functional connectivity during resting state can map the functionality of brain tissue and can offer valu-

able information for the pre-surgical management of patients with brain lesions, as well as for research into structural-functional relationships in normal subjects.

We are now seeking to extend this remarkable result by combining it with dMRI fiber tracking to identify the subserving pathways, with the goal of providing a more complete characterization of at-risk regions based on preoperative functional status.

Roland Henry, PhD, is an associate professor in residence; Bagrat Amirbekian, BS, was a staff research associate; Jeffrey I. Berman, PhD, is a postdoctoral fellow, Monica Bucci, MD, is a junior specialist, Anne Findlay, MA, is a staff research associate, Christopher Nguyen, BS, is a staff research associate, Mitchel S. Berger, MD, is professor and chairman, Department of Neurological Surgery and director of the Brain Tumor Surgery Program, UCSF. Srikantan S. Nagarajan, PhD, is a professor in residence and co-director of the Brain Behavior Research Interest Group, Department of Radiology and Biomedical Imaging.

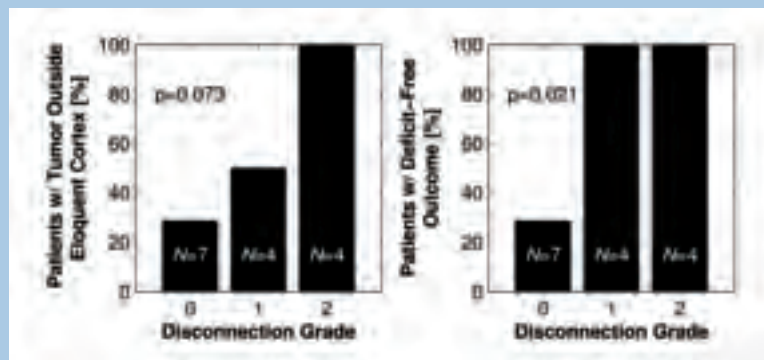


Figure 4. Bar plots illustrating the percentage of patients without critical tissue within the tumor area and without functional deficits after tumor resection, in relation with the functional disconnection score derived from L-images.

EVALUATING RISK FACTORS FOR NEPHROGENIC SYSTEMIC FIBROSIS IN A RAT MODEL

Thomas A. Hope, MD; Philip E. LeBoit, MD; and Robert C. Brasch, MD

Nephrogenic systemic fibrosis (NSF) is a debilitating systemic fibrosing disorder that occurs uniquely in patients with renal failure. Although first described in 2000 in an article co-authored by Philip E. LeBoit, MD, it was little known to most clinicians until 2006 when an apparent link between gadolinium-containing contrast medium administration and the development of

NSF was discovered. This led to a change in practice for the use of contrast-enhanced magnetic resonance imaging (CE-MRI) in patients with severe renal failure. Renal function is now calculated in the majority of patients undergoing CE-MRIs; those patients with severe renal failure and/or on dialysis often forgo the CE-MRI examination that might have been performed only four years ago. Though NSF has substantially changed the way radiologists image renal failure patients, little is known about the disease process and risk factors.

In addition to renal failure, other risk factors have been implicated with the development of NSF: stability of gadolinium chelate used, dose and frequency of gadolinium administration, the presence of venous thrombosis, surgery and other pro-inflammatory states including infection. Our group at UCSF has been particularly interested in erythropoietin (Epo) and intravenous (IV) iron. Both are used frequently in dialysis patients and their use increased dramatically in 1997, perhaps incidentally the first year a patient is known to have developed NSF, and the year when anemia guidelines for dialysis patients were revised recommending aggressive use of both Epo and iron. Additionally, there are mechanistic reasons why these two medications may be involved:

- Epo has been associated with an increased fibroblastic response to wound healing and also results in the release of bone-marrow-derived fibrocytes that are thought to be involved in NSF development.
- IV iron has been implicated in the fibrotic response seen in the development of ARDS, likely because it promotes the creation of free radicals. It may also result in the release of free gadolinium from its chelate through the process of transmetallation.

There have been reports of lesions similar to NSF in high-dose, Gd-contrast agent rat models. Therefore, we decided to test if Epo or IV iron worsen NSF skin lesions in an NSF rat model.

Methods

Twenty-four wild-type male Hannover-Wistar rats were randomly separated into four groups of six animals (Groups A, B, C, and D).

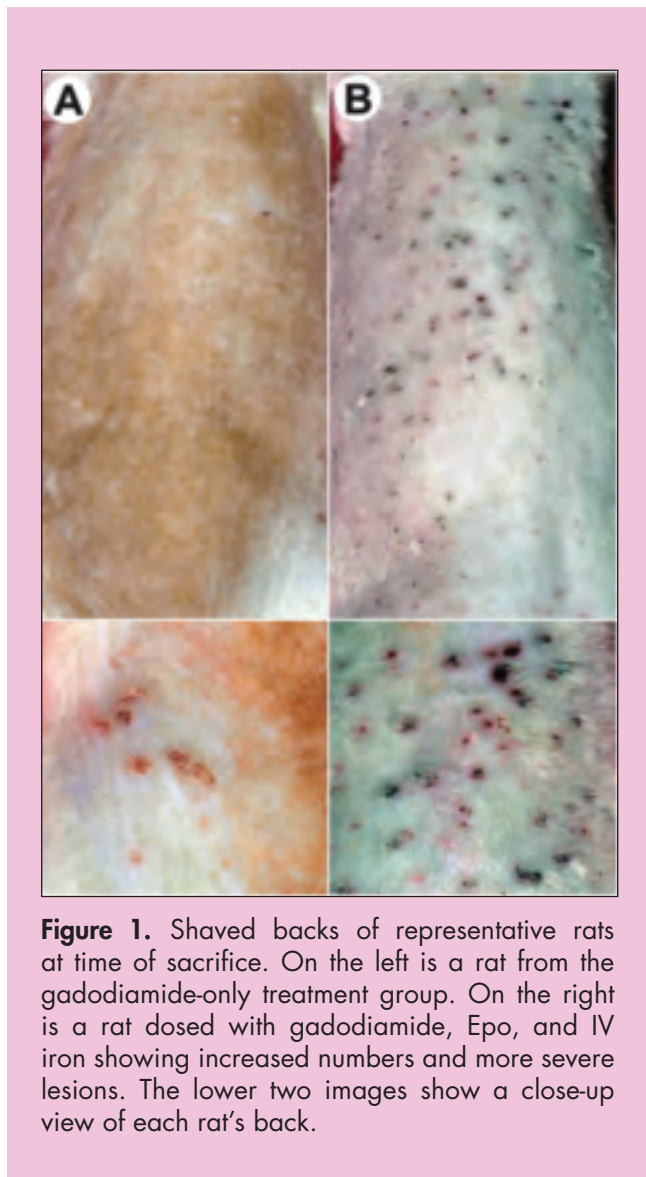


Figure 1. Shaved backs of representative rats at time of sacrifice. On the left is a rat from the gadodiamide-only treatment group. On the right is a rat dosed with gadodiamide, Epo, and IV iron showing increased numbers and more severe lesions. The lower two images show a close-up view of each rat's back.

- Group A was dosed with gadodiamide alone
- Group B with gadodiamide and Epo
- Group C with gadodiamide and IV iron
- Group D with gadodiamide, Epo, and IV iron

All groups received 2.5 mmol per kg of gadodiamide (Omniscan) for 20 consecutive weekdays over four weeks. Group B received 100 units per kg of Epoetin alfa (Procrit™) three days a week for five weeks starting one week prior to the first dose of gadodiamide. Group C received 2 mg per kg of iron dextrose (Dexferrum™) five days a week for two weeks starting the first day of gadodiamide injections. Group D received both IV iron and Epo.

All rats were sacrificed seven days after the final injection of gadodiamide. The backs of all animals were shaved to better visualize skin changes, and skin biopsies were taken from each animal's back. Hematocrits were measured prior to sacrifice.

For histologic analysis, two samples from each rat were embedded in paraffin and stained with hematoxylin and eosin. Nuclei counts were performed in both superficial and deep dermal regions where the highest level of cellularity was noted. Inductively coupled plasma mass spectrometry (ICP-MS) was used to measure the amount of deposited gadolinium (Gd), iron (Fe), aluminum (Al), calcium (Ca) Copper (Cu), and zinc (Zn) in the rat skin tissue.

Results

Macroscopic skin findings showed an increased number of skin lesions in Group D rats that were exposed to gadodiamide, and both Epo and IV iron compared to the other three groups (Figure 1). Histopathology showed increased dermal cellularity in rats treated with gadodiamide, Epo and IV iron (Figure 2: cell count per region of interest: A = 42.3 ± 22.7 ; B = 56.1 ± 20.0 , $p = 0.79$; C = 80.2 ± 41.9 , $p = 0.11$; D = 106.6 ± 38.5 , $p = 0.004$). Gd levels were lower in rats treated with gadodiamide and Epo, while they were relatively elevated in the rats receiving gadodiamide, Epo, and IV iron compared to rats treated only with gadodiamide (A = $1109 \mu\text{g Gd} / \text{g tissue}$; B = 822 , $p = 0.049$; C = 1192 , $p = 0.82$; D = 1466 , $p = 0.012$). Iron and calcium deposition in tissues mirrored levels of gadolinium deposition.

Discussion

We demonstrated that the combination of Epo and intravenous iron worsens the severity of skin lesions in rats receiving high, repeated doses of gadodiamide. The mechanism of action by which Epo and IV

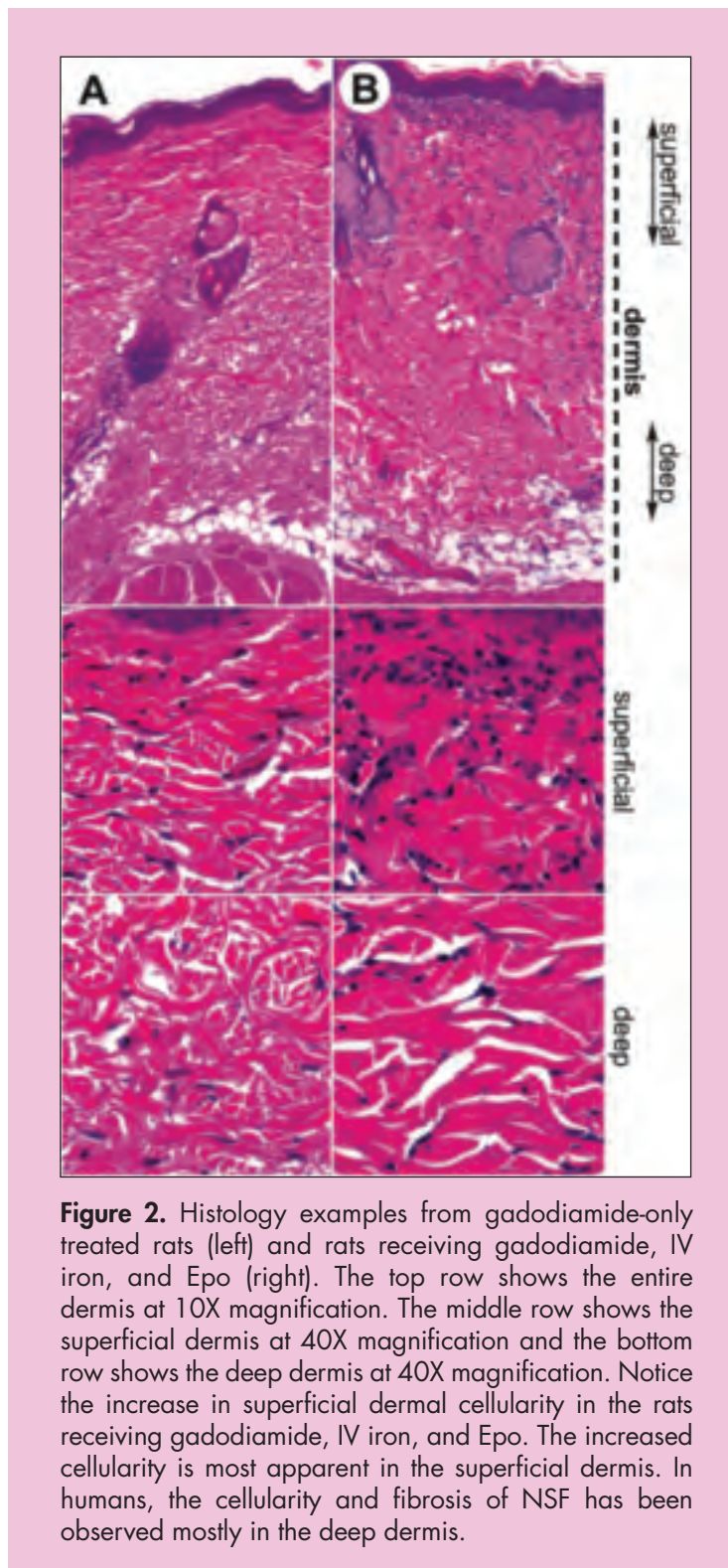


Figure 2. Histology examples from gadodiamide-only treated rats (left) and rats receiving gadodiamide, IV iron, and Epo (right). The top row shows the entire dermis at 10X magnification. The middle row shows the superficial dermis at 40X magnification and the bottom row shows the deep dermis at 40X magnification. Notice the increase in superficial dermal cellularity in the rats receiving gadodiamide, IV iron, and Epo. The increased cellularity is most apparent in the superficial dermis. In humans, the cellularity and fibrosis of NSF has been observed mostly in the deep dermis.

iron results in increased lesion severity is not clear (Figure 3 describes possible interactions). Unexpectedly, Epo- and gadolinium-treated rats had lower deposited gadolinium, while IV-iron- and gadolinium-treated

rats had relatively unaffected gadolinium deposition. These results suggest that iron does not result in transmetallation, although it may promote a worsening of fibrotic lesions, perhaps through increased oxidative tissue damage.

Of note, calcium deposition appears to mirror gadolinium deposition. Prior studies have shown that calcium deposition increases with higher levels of deposited gadolinium in patients with NSF, and that calcium appears to be deposited in the dermis in association with detected gadolinium. Possibly, gadolinium activates a cytokine pathway normally mediated by calcium through cytokines such as osteopontin.

Our results are potentially limited because the animal model chosen may not accurately model human NSF. There have been extensive discussions on the relationship between the high-dose rat model and NSF as it occurs in humans. Although the pathology seen in rats is slightly different than that seen in humans, we accept the rat model as an adequate surrogate for disease severity in human NSF.

Future Directions

These early experimental results suggest many new questions of mechanism and the NSF disease process, as well as the body's more general handling

and response to heavy metal exposure. To date, little is known about why the body apparently responds to deposited gadolinium with fibrosis. Other studies have shown that fibroblasts and macrophages secrete cytokines associated with fibrosis when incubated with gadolinium chelates. We hypothesize that the process is related to activation of the same pathway tied to normal wound healing, and that intravenous iron may result in oxidative stress that, in turn may stimulate fibrosis.

In the coming months, we plan a series of cell culture experiments to explore these hypothesized mechanisms of fibrosis induction. The NSF rat model provides an attractive system in which to study what has been regarded as the wound healing/fibrosis pathway. We hope to more fully understand the process of NSF while considering the more general problem of pathologic fibrosis, regardless of specific disease. NSF may provide a useful new window into the broad process of fibrosis and its regulation.

Thomas A. Hope, MD, is a PGY 3 Diagnostic Radiology resident. Philip E. LeBoit, MD, is a professor in the Department of Pathology. Robert C. Brasch, MD, is a professor of radiology in residence in the Department of Radiology and Biomedical Imaging.

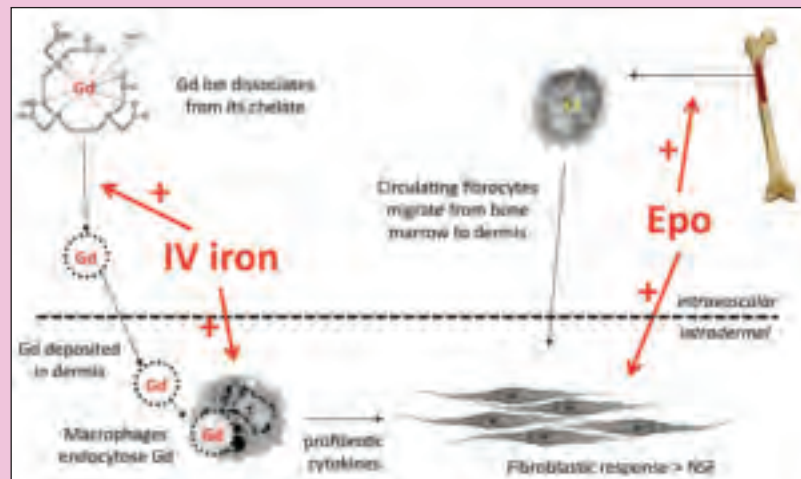


Figure 3. Potential interplay between Epo, IV iron, and NSF development. Chelated gadolinium is administered and deposited in the dermis, either in chelated or ionic form. IV iron may increase the amount of free gadolinium through transmetallation. The gadolinium is likely endocytosed by macrophages, resulting in a profibrotic cytokine response. IV iron may potentiate the macrophage response by creating oxidative stress. At the same time, circulating fibrocytes are released from the bone marrow, a process known to be potentiated by Epo. It is hypothesized that these cells then migrate to the dermis and lead to the fibrosis seen in NSF, in a process mediated by macrophage-released cytokines, as well as Epo.

NEUROIMAGING-BASED APPROACHES TO ESTIMATE HIP FRACTURE RISK

By Wenjun Li, PhD; John Kornak, PhD; Ying Lu, PhD; and Thomas F. Lang, PhD

According to the National Osteoporosis Foundation, approximately 1 in 2 women and 1 in 4 men over age 50 will have an osteoporosis-related bone fracture in their remaining lifetime. Bone fracture risk is conventionally assessed by bone mineral density (BMD), which can be measured by dual-energy X-ray absorptiometry (DXA) and quantitative computed tomography (QCT). Under current public health management, pharmacological treatment is advised for elderly people diagnosed with osteoporosis (with BMD T-scores ≤ -2.5). However, BMD alone does not adequately predict fracture risk. In fact, the majority of bone fractures have occurred in the osteopenia population (T-scores between -1 and -2.5). Treating everyone in this much larger group is unaffordable. Therefore, more accurate fracture risk prediction techniques are in high demand.

BMD does not fully capture bone fragility features. It is an average measure of bone mineral in relatively large volumes of bone tissues that contain sub-volumes with fundamentally different biomechanical roles in resisting fracture forces. A study comparing hip QCT images of young and elderly subjects (Mayhew 2005, *Lancet*) demonstrated spatial variation in patterns of changes in the proximal femur.

During aging, bone structures with less mechanical stimulation, such as the superior cortex of the femoral neck, could undergo much more dramatic bone loss. While such structures experience relatively small mechanical loading in daily physical activities, they could experience much stronger transient forces in falls, which are thought to be associated with 90% of hip fractures.

Lang's group has used QCT to measure compartmental and sub-regional BMD coupled with geometric assessments, combining these measures in statistically based prediction models, or into simple biomechanically based strength indices. With magnetic resonance imaging (MRI), Majumdar, Link, and collaborators have been investigating bone micro-architecture. With the 7 Tesla MRI system installed at the Mission Bay campus, high-resolution *in vivo* imaging of the proximal femur and other musculoskeletal systems have been demonstrated (Krug 2008, *Images*). Another highly promising

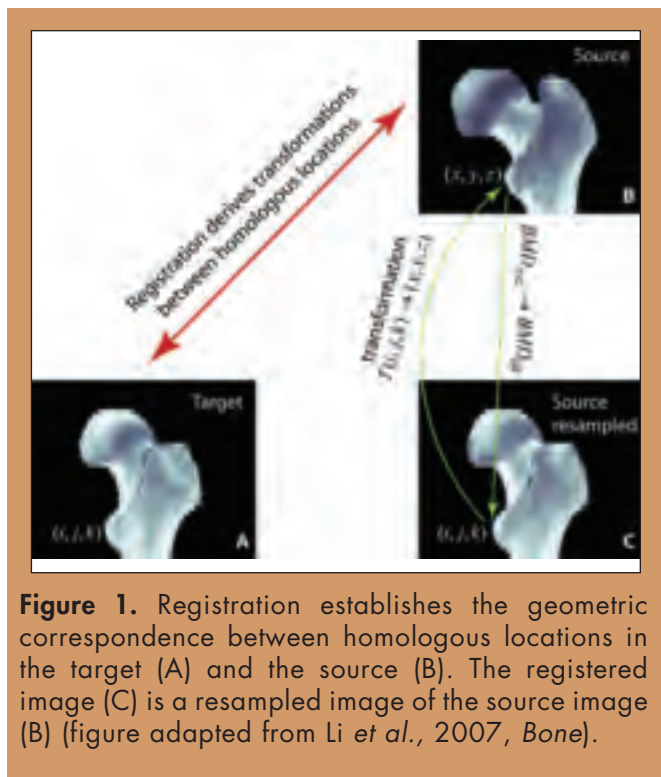
approach to estimating bone strength is patient-specific finite element modeling (FEM), which maps CT image units to estimates of material mechanical properties. The clinical application of FEM entails challenges such as using CT numbers to refine and validate the relationships that define mechanical properties.

In our laboratory, we recently adapted neuroimaging techniques to predict fracture risk at the hip. Our approaches are based on the idea that features of proximal femora at high risk for fracture can be detected. To identify these features, we compared the structural bone differences between patients who developed hip fractures and age-matched controls. We also identified bone changes in patients under drug treatments and in astronauts who experienced bone loss due to long-duration spaceflights.

The fundamental technique to achieve three-dimensional structural comparison is to transform the hip images to a common reference space, so the homologous tissue elements can be compared directly. One of the original neuroimaging applications of this approach was a study on the hippocampus brain structure of London taxi drivers (Maguire et al, 2000, *Proceedings of the National Academy of Sciences*). It was shown that the back part of the hippocampus was, on average, larger in the taxi drivers compared to control subjects. This has been attributed to London taxi drivers needing good spatial navigational skills. Below we describe our methods for studying the hip structure using these neuroimaging-based techniques, and extensions that we have developed.

Hip Analysis in a Common Reference Space: Three-Dimensional Comparison of Homologous Structures (Image Registration, Voxel-Based Morphometry)

Three-dimensional comparison of homologous structures is achieved by image registration. Briefly speaking, with image registration, images from different subjects, or from the same subject at different time points, or from different image modalities, are transformed to a common reference space so that homologous structures are resampled to the same coordinates,



and can be compared. Recently in our laboratory we adapted this technique to the study of bone structures (Figure 1). The image registration algorithm we adapted was originally developed for brain MRI images at the Montreal Neurological Institute.

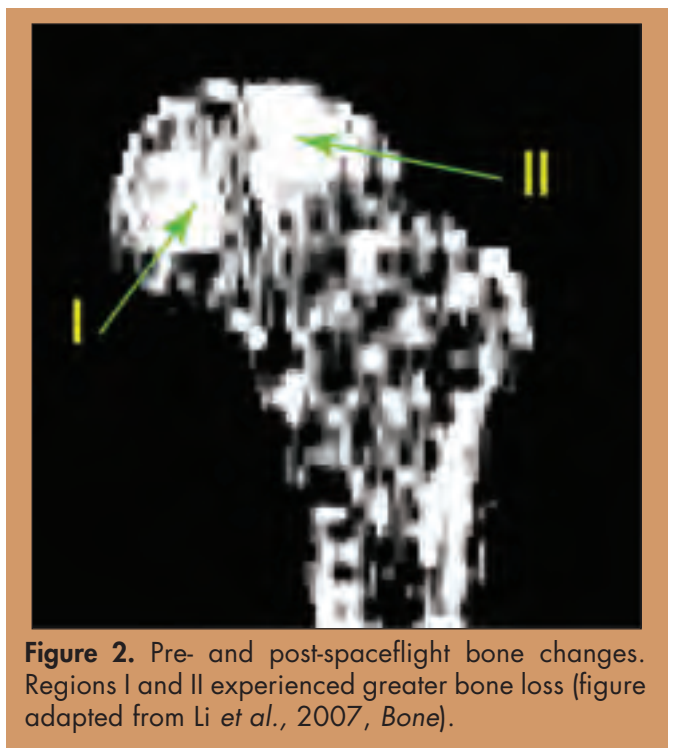
Once multiple scans are transformed (spatially normalized) to the common hip space, they form an image atlas. The homologous tissue elements can then be compared and statistically analyzed to study spatially localized, cohort-based outcome effects.

In the neuroimaging literature, the voxel-wise comparison of the local concentration of gray matter between two groups of subjects is referred to as voxel-based morphometry (VBM). Below we present our experience in applying the VBM technique to compare the bone mineral distribution in the proximal femur and illustrate how such studies have prompted further exploration of 3D bone-fragility features.

Identifying Regions with Most Accelerated Bone Loss Due to Weightlessness

It is well known that astronauts lose bone during spaceflights. Studies employing quantitative CT have been recently carried out by Lang and collaborators (Lang *et al.*, 2004 and 2006, *JBMR*). However, how the bone loss is distributed three-dimensionally is less clear. Identifying the most effective countermeasures against such bone loss remains as a major challenge for NASA and other space agencies.

Based on the VBM technique, we have identified regions inside the proximal femur that experienced the strongest bone loss due to long-duration spaceflight (Li *et al.*, 2007, *Bone*). QCT scans were acquired from 16 crewmembers of International Space Station missions who experienced spaceflights of approximately half a year. Pre- and post-flight QCT images were acquired using a helical CT scanner at Baylor College of Medicine. For the 16 pre- and post-spaceflight scan pairs, in the atlas space, we performed voxel-by-voxel t-tests over the total proximal femur, and identified voxels with statistically significant bone changes. False discovery rate was performed to correct for multiple comparisons. Regional variation of bone loss is shown in Figure 2. It is noticeable that regions marked by I and II showed greater magnitudes in bone loss compared to the rest.



Identifying the Spatial Distribution of Drug Response

We have applied femur atlas analysis to identify drug-induced spatial changes in bone structure. For 121 subjects treated with TPTD (20 $\mu\text{g/d}$ SQ) for 12 months, QCT images of the hip were obtained at baseline and 12 months. As shown in Figure 3, a group of voxels showing negative BMD changes clustered in the inferior cortex, and a group of voxels showing positive changes clustered in dense trabecular bone. This approach to visualizing therapy effects may aid in interpreting the effect of drug therapies on hip fracture risk by better showing how the regions of strongest response correlate to the regions where fractures are most likely to occur.

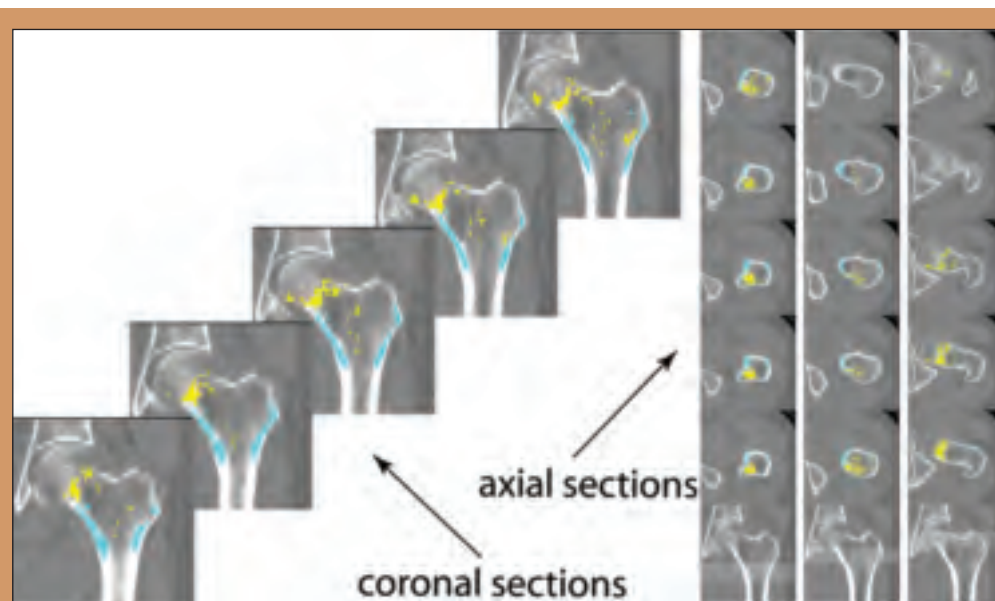


Figure 3. Blue and yellow bands, respectively, show regions of statistically significant negative and positive changes (figure adapted from Li *et al.*, 2008, *ASBMR*).

Identifying Fracture-Critical Regions by Comparing Hip QCT Scans of Fractured Patients and Controls

Thirty-seven women aged 65 or older with atraumatic hip fractures were recruited from the emergency room at Beijing's Ji Shui Tan Hospital. Thirty-eight women over 65 years old in good health were invited from the surrounding community to participate in the study as controls. Figure 4 shows the regional variation of bone mineral differences between the fractured patients and the controls, as represented by the t-statistic map using the VBM technique.

We then randomly divided the subjects into two groups: the Training Group and the Test Group. Using the scans from the Training Group, we compared the images between the patients and the controls and generated a t-statistic map. We applied a t-statistic threshold to select the 10% voxels inside the proximal femur that had the highest t values. Such voxels formed clusters, which were referred to as the fracture-driven region of interest, the F-ROI (Li *et al.*, 2009a, *Bone*). We used the BMD in the F-ROI to discriminate the scans of fractured patients and controls in the Test Group, and performed ROC analysis to estimate the discrimination efficacy. The AUC (area under curve) for the F-ROI approach, 0.92, was higher than the AUC values using anatomic ROIs, which ranged between 0.78 and 0.87. BMD measurement based on the fracture-driven region of interest showed improved fracture prediction power.

Although we have demonstrated the improvement of fracture risk estimation obtained by

identifying fracture-critical regions, taking the average BMD inside such regions still averages out potentially useful 3D feature information. To quantitatively represent such 3D inhomogeneous information, and to use these features to improve fracture risk prediction, we developed approaches to capture the 3D bone-fragility features. Some preliminary studies are described below.

Principal Components Analysis (PCA)

In PCA, a vector in a multi-dimensional space is represented as a linear combination

of eigen vectors. For image analysis, an image can be represented as a combination of eigen images, namely, the principal components (PCs). We have used PCs (instead of individual voxels) to characterize bone fragility features.

For this study, the subjects were the same as those used in the previous fracture discrimination study. The subjects were divided randomly and equally into Group I and Group II, one served as the Training group and the

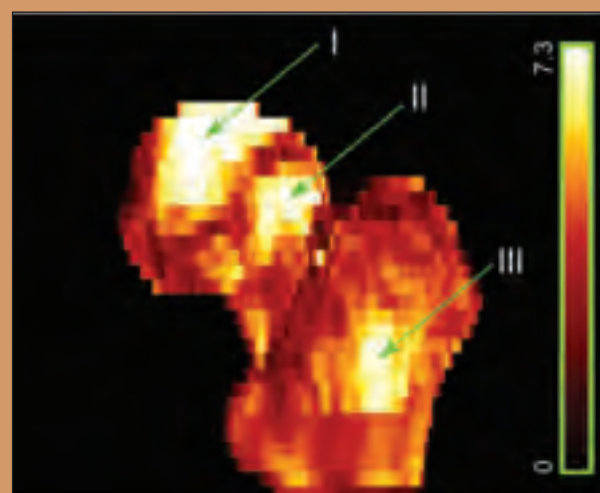


Figure 4. t-statistic map (3D rendering) illustrates regional bone mineral differences between fractured patients and controls, where I, II, and III are regions with the most significant differences (figure adapted from Li *et al.*, 2009a, *Bone*).

other as the independent Test group. After constructing the hip atlas, we performed PCA on the training scans to obtain a set of PCs. For each PC, we compared the eigen values between the fractured patients and the controls to determine whether that PC was associated with fracture. We then constructed a linear hip fracture risk model, based on the PCs associated with fracture. This model was then used to estimate the fracture risk based on the PC coefficients of a hip image.

To test our model, we used the estimated fracture risk values to perform hip fracture discrimination for the test scans. When using scans from Group I as the training set and Group II as the test set, the AUC value was 0.880, comparable to (slightly higher than) the AUC values obtained using bone densitometry methods in different ROIs, which ranged between 0.782 and 0.871. By switching the training and test groups, the AUC value for the PCA approach was 0.839, again comparable to those obtained by bone densitometry methods, which had AUC values ranging between 0.767 and 0.807.

Image Similarity Measures

Another approach is based on image similarity. Our main idea is that if the hip image of a given subject is more similar to hip images of fractured patients than to hip images of controls, that subject is likely to have high fracture risk. The image similarity measures used are adapted from image registration.

The 75 scans (as described above) were randomly separated into Group I and Group II. First, Group I served as the Model Group and Group II served as the Test Group, then their roles were switched. We classified the test scans based on whether a test scan was, on average, more similar to the model scans of fractured patients or to the model scans of controls. Figure 5 shows the fracture discrimination results when using mutual information as the image similarity measure. By combining BMD and image similarity measures, fracture discrimination significantly improved compared to using BMD alone (AUC values increasing from 0.84 to 0.92). (Details about this study are described in Li et al., 2009b, *Bone*).

Summary and Future Directions

In conclusion, we have applied inter-subject image registration to construct femur atlases to compare hip QCT images. Based on atlas analysis, we have been able to identify the regions inside the proximal femur most responsive to weightlessness, drug treatment, and bone differences between fractured patients and controls. Using BMD inside the fracture-driven region of interest, we improved fracture discrimination. We have further developed quantitative measures for characterizing 3D

fragility features. The preliminary evidence of our PCA and image-similarity-based approaches shows promise for improving discrimination of fractured patients from controls.

For future studies, we plan to apply our methods to a larger data cohort involving more fracture patients, and potentially generalize such methods for other imaging modalities for bone structures. We expect that with the more in-depth understanding of the 3D determinants of bone fragility, more cost-effective prophylactic diagnosis and treatment solutions can be reached.

Wenjun Li, PhD, is an associate specialist; John Kornak, PhD, is an assistant professor; Ying Lu, PhD, was a professor in residence and Director of the Biostatistics and Outcomes Research Specialized Resource Group; and Thomas F. Lang, PhD, is a professor in residence in the Department of Radiology and Biomedical Imaging.

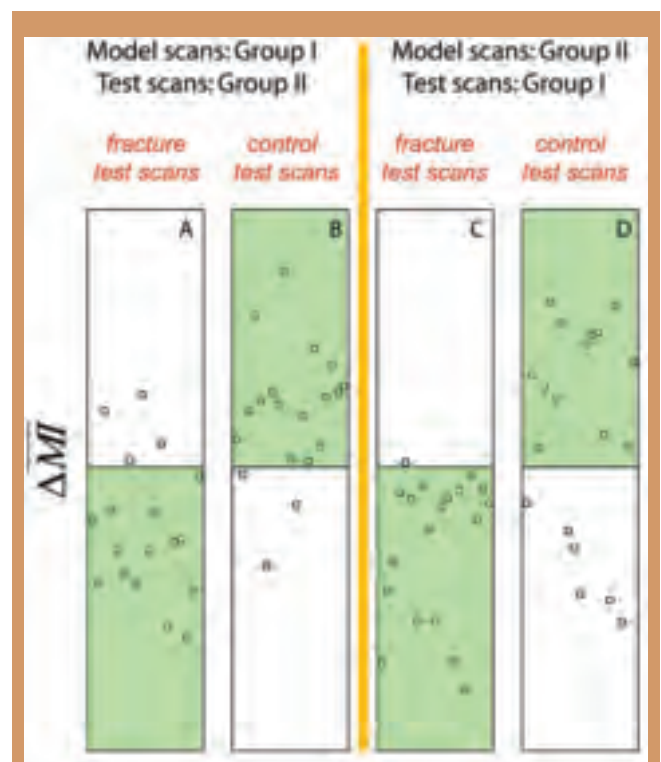


Figure 5. Subject classification based on image-similarity measures. The cases falling to the green regions are those that matched the expectations (figure adapted from Li et al., 2009b, *Bone*).

A BIG YEAR

By Robert G. Gould, ScD

The Department completed many capital projects within the past year, greatly increasing its MR capacity and replacing old equipment. Indeed as this is written, there are no active construction projects within Radiology, a situation that is both rare and short-term, as we are awaiting state approval on a project to replace two body interventional rooms within Moffitt. We also are in the bid process for construction that will remodel the mammographic reading room at Mt. Zion.

MRI Expansion

This was the year in which Radiology experienced its greatest expansion in MR capacity ever. We installed a total of four magnets, two inpatient and two outpatient, all 3T units. On the inpatient side, two 32-channel, GE HD750 systems were installed in Moffitt 3 North, a space new to Radiology. The space comprises nearly 3,700 sq. ft., and the cost of equipment and construction topped \$12 million. To complete this project, the entire infrastructure in this part of Moffitt Hospital had to be improved, including air handling, electrical capacity, and the data networks. A large chiller was installed on the roof. The floor had to be strengthened not just under the magnet locations, but also under the path for transporting the magnets to their locations. This necessitated closing the cafeteria, which is under the magnets, for several months. The new magnet space

was designed to support patients requiring anesthesia during their procedures and was carefully developed to assure safety within the magnet area. The magnets sit side by side, requiring substantial shielding to prevent interference between them. With the addition of these two magnets, the longstanding 1.5T magnet in a trailer located outside the emergency room entrance was finally shut down.

The third magnet added to Radiology is located in the Medical Office Building on Post Street near Mt. Zion Hospital, on the ground floor adjacent to a 64-slice CT scanner. Patient reception and changing areas are shared with CT, improving efficiency. The magnet is a Siemens Verio 3T, the first such magnet installed in Northern California. This system features a 70 cm bore and a table supporting 550 pounds. The magnet is a 32-channel system configured for all types of imaging. This magnet will be used to further develop breast imaging in collaboration with Siemens, using a Sentinelle breast coil.

The fourth magnet, also a 32-channel GE HD750, is located in a new building near the Mission Bay Campus within the recently opened Orthopedic Institute. This facility is nearly 50,000 sq. ft. and is now where most of UCSF's orthopedic work is done. Radiology has a bone reading room on-site and staffs the equipment, which also includes two GE Definium digital radio-

graphic rooms and a Philips EasyDiagnost R/F room. The latter has both a table and a wall-mounted digital detector. Other imaging equipment at the Orthopedic Institute includes a portable X-ray unit, a C-arm portable fluoro unit, and a Fuji CR. All imaging systems connect to Radiology's PACS.

The magnet count at UCSF is now 10 clinical magnets, six 1.5T systems and four 3Ts. In addition the Department has three research magnets for human studies, two 3Ts and a 7T.



The new 3T magnets located on the third floor of Moffitt Hospital. The space also includes a patient prep and holding area.

Parnassus Campus

While the 3 North MRI addition was being worked on, Radiology was also building in several other areas. Equipment replacement in the Moffitt radiographic/fluoroscopic rooms was completed with the installation of two Siemens Luminos units. We also completed installation of Neurointerventional's second Siemens, flat-panel, biplane angiographic room. This major project took nearly two years to complete and required expanding the room space by relocating two offices and closing a darkroom. The neurointerventional project replaced the sole remaining piece of equipment installed when Long Hospital was built in 1986.

Some new equipment at Moffitt/Long did not require construction. The ultrasound section acquired three new GE Logiq E9 US machines. These couple to a new ultrasound miniPACS implemented in May 2009, made by Imorgon. After years of frustration with the old display system, the Imorgon miniPACS was eagerly awaited.

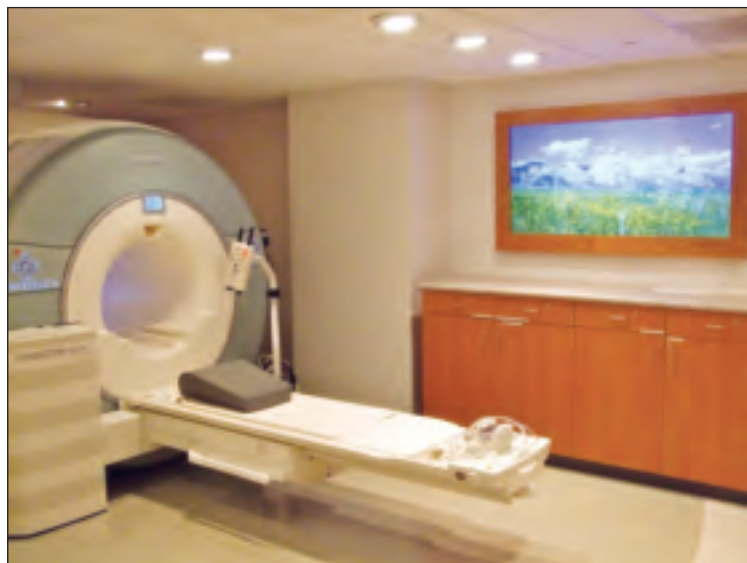The Department acquired new portable X-ray equipment that enables digital acquisition of images at the bedside. Two GE Definium X-ray units with a digital detector tethered to the unit are now in use. Because these units communicate wirelessly, a patient worklist is available to the technologist and images are sent to PACS without connecting to a network port. The Department soon will receive three portable systems from Fuji called CR Go units. These portables use CR, but the CR reader is part of the portable unit. They will also function wirelessly.

Mt. Zion Campus

In addition to the new magnet, most of the activities at Mt. Zion involved mammography. With the closure of the mammographic rooms within the ACC building on Parnassus, all mammography is now done in the Women's Pavilion or within the Cancer Center at Mt. Zion. All remaining analog units have been replaced with Hologic Selenia systems, bringing the total number of these systems at UCSF to six. All film processors within mammography are now gone. The mammographic reading room will begin a remodel in September and a dedicated miniPACS for mammography made by Sectra is on order. Mammography has also acquired a new mammographic reporting system made by a local company, Jambayang Research.

China Basin

With the expansion of imaging equipment, the Department's Agfa Impax PACS system has had to expand. PACS core components have been installed in a computer room at China Basin, including data



The new Siemens Verio 3T magnet installed on first floor of the Post Street Medical Office Building. The MR facility is adjacent to a 64-slice CT scanner and includes the magnet room, a patient prep area, a patient consult room, and a reading room.

storage devices and, importantly, a redundant database server. The latter component eliminates a single point of failure that previously existed. In the coming year, we have been given resources to fully implement a backup system at this site for disaster recovery and business continuity.

China Basin has become the site for most outpatient nuclear medicine studies. A nuclear cardiac stress lab is fully operational. We are exploring the possibility of adding more nuclear cameras in this location.

The Future

The Department will continue to replace old equipment in the upcoming year. We have been approved to replace the body interventional angiographic room at Mt. Zion. Also at Mt. Zion, we have approval to add a radiographic room. This is greatly needed, as Mt. Zion now has only a single, non-digital radiographic room, requiring use of CR and causing problems in the event of any downtime. Within Moffitt/Long construction will occur as we install the new interventional rooms, a CT scanner, and at least one nuclear camera. All of these projects were approved in previous years and are finally ready for work to begin.

Robert G. Gould, ScD, is a professor of radiology in residence and vice-chair for Technology and Capital Projects. He oversees the purchase of the department's capital equipment.

ASLAM ASSUMES CHIEF OF CT POSITION AT SF VAMC



Rizwan Aslam, MD

Rizwan Aslam, MD, associate clinical professor of Radiology and Biomedical Imaging, accepted the newly created position of chief of computed tomography at the San Francisco Veterans Affairs Medical Center on January 1, 2009.

Aslam received his medical degree from the University of Aberdeen, Scotland, UK. He completed his medical residency at the University of Sheffield, UK, followed by a radiology residency at the University of Manchester, Manchester, UK, completed in 2002. Aslam finished his abdominal imaging clinical fellowship in

the UCSF Department of Radiology in 2003. That July, Aslam joined the Department of Radiology and Biomedical Imaging's Abdominal Imaging Section. He received the Excellence in Teaching Award in 2008 from the Haile Debas Academy of Medical Educators. His research interests are in the areas of CT colonography and 3D imaging.

"Dr. Aslam has provided excellent CT services to both the VAMC and UCSF Medical Center," said Ron Arenson, MD, chairman. "Please join me in congratulating Dr. Aslam on his new leadership role in the department."

NELSON TO CO-CHAIR NEW DEPARTMENT

In February 2009, Sarah J. Nelson, PhD, professor of radiology and director of the Margaret Hart Surbeck Laboratory of Advanced Imaging, became co-chair of a new UCSF department, Bioengineering and Therapeutic Sciences (BTS). Led by Nelson and Co-Chair Kathy M. Giacomini, PhD, BTS marks the first UCSF department across two schools, as it comprises the former Department of Biopharmaceutical Sciences in the School of Pharmacy and the Program of Bioengineering in the School of Medicine. According to Giacomini, "It's a marriage of scientists who are expert in building biological tools, with those who look for ways to understand and interrupt the mechanisms of disease."

"Today's approach to developing and evaluating medical devices and potential medicines through the point

when they are approved for use by patients is painfully slow, inefficient, and expensive," Nelson said. "We aim to change this by combining new biological discoveries with cutting-edge technology."

According to Nelson, this is the first department of its kind in the country. "We're acting on our belief that in order to excel, we have to approach science in wholly new ways, through new and unexpected relationships, including those with government and industry. The BTS structure is critical for recruiting faculty members who think outside the confines of traditional disciplines, and for promoting our PhD graduate programs," she concluded.



Sarah J. Nelson, PhD

©majedphoto.com

SOLLITTO TAKES ON EXPANDED ROLE IN CLINICAL OPERATIONS

In July 2009, Richard A. Sollitto, MD, professor of Radiology and Diagnostic Imaging, assumed an expanded role in clinical operations for the Department of Radiology and Biomedical Imaging.

Sollitto received his medical degree from the University of Pennsylvania, Philadelphia, Penn., and completed a year of residency in internal medicine at Thomas Jefferson University Hospital in Philadelphia before coming to UCSF, where he completed his residency in diagnostic radiology in 1982. He followed that residency with an additional year as chief resident in the Nuclear Medicine Section. In 1983, Sollitto joined the UCSF faculty, and in 2003 was named Radiol-

ogy Chief at Mt. Zion. Since 2007, he has served as associate chair for Mt. Zion and Ambulatory Care, where he oversees clinical operations at Mt. Zion Hospital and the Ambulatory Care Center (ACC).

"Because Dr. Sollitto is a strong advocate for quality patient care, I have asked him to take on new responsibilities involving our clinical practices, including serving as a consultant to other sections," said Chairman Ron Arenson, MD. "I know we will all benefit from his focus on patients and referring physicians. Please join me in congratulating Richard on his added responsibilities in the area of practice development."



Richard A. Sollitto, MD

YEH APPOINTED ASSISTANT CHIEF OF RADIOLOGY AT SF VAMC



Benjamin M. Yeh, MD

In January 2009, Benjamin M. Yeh, MD, associate professor of Radiology in residence, accepted the position of assistant chief of radiology at the San Francisco Veterans Affairs Medical Center.

Yeh attended Duke University in Durham, North Carolina, receiving his medical degree in 1996. He completed a residency in diagnostic radiology at UCSF in 2001, followed by a one-year clinical fellowship in abdominal imaging. Yeh joined the UCSF faculty in 2002, as a member of the Abdominal Imaging Section.

From 2006-09, Yeh served as radiology fellowship advisor. His research interests focus on novel applications of abdominopelvic CT imaging.

"Over the years, Dr. Yeh has been very active in teaching and research," said Chairman Ron Arenson, MD. "His experience in our Abdominal Imaging Section, coupled with his leadership skills and teaching abilities will bring him success in his new position."

DIAGNOSTIC RADIOLOGY RESIDENCY PROGRAM 2009

This was a year of fine-tuning aspects of our residency program, including:

- Refining the core and physics curriculum
- Revamping hands-on junior resident training in ultrasound and fluoroscopy
- Developing a Web-based conference evaluation system
- Transitioning to the new night-float call system
- Launching the new education track, coordinated by Chief Resident David Naeger, MD
- Refining the process for research time, project definition, and mentor supervision


We also completed a site inspection by the national Radiology Residency Committee of the ACGME in March. The site visit was the culmination of months spent preparing the Program Information Form document. This large task was accomplished with the knowledgeable assistance of Terry (Rodden) Brosnan and Sandria Wong.

Group team-building events included football and soccer games against the Stanford residency. (The only thing that didn't go too well this year for us!) The residents enjoyed a "lychee martini evening" hosted by Program Director Aliya Qayyam, MBBS, at her home (fortunately it is still standing). The Margulis Society career evening hosted by Donna Hoghooghi, MD, (UCSF Radiology alumnus and past president of the Margulis Society) at her home provided an opportunity to socialize, network, and learn about career opportunities.

One Class Moves On, Another Moves In

Graduation was a truly joyful and lively event held at the St. Regis Hotel in downtown San Francisco. We are proud to graduate another stellar class of residents and superb outgoing chief residents, Natasha Brasic, MD, Jeremy Collins, MD, Yee-Li Sun, MD. The out-going and new in-coming chief residents Peter Jun, MD, Reema Munir, MD, David Naeger, MD, have established excellent working relationships with the program director and associate program directors David Avrin, MD, PhD, and Brett Elicker, MD. After the site visit, Dr. Elicker stepped down from associate program director to focus on his academic and educational pursuits.

All of the senior residents passed their final oral board examination, and most of the senior class will remain at UCSF for fellowships in a variety of sections.



Chief Residents 2009-10: David Naeger, MD, Reema Munir, MD, Peter Jun, MD

Akhilesh Sista, MD, has a unique one-year opportunity to participate in the Biodesign Program at Stanford. We wish them all continued success and happiness.

We were once again fortunate to have a large and impressive group of applicants for 2010, along with very gratifying match results. As you read this, the incoming 2009 class has already completed a significant portion of its first-year rotations, and we will be hard at work reviewing applications for the class to begin in 2011.

Resident Publications, Presentations, and Awards

Once again, our residents had an incredibly productive year, including publication of their research experiences and other honors.

- Ingrid Burger, MD, serves as a PGY3 resident representative on the Margulis Society board of directors. She published: Burger, I, Kass N, Sunshine J, Siegelman S. The Use of CT for Screening: A National Survey of Radiologists' Activities and Attitudes. *Radiology*. 2008 Jul;248(1):160-8; and Burger I, Kass N. Screening in the Dark: Ethical Considerations of Providing Screening Tests to Individuals When Evidence is Insufficient to Support Screening Populations. *Am J Bioeth*. 2009 Apr;9(4):3-14.
- Jeremy Collins, MD, participated in the Radiological Society of North America (RSNA) Trials Workshop in January. He was awarded the Elmer Ng Memorial Outstanding Resident Award by the UCSF Department of Radiology and Biomedical



Collins (right) accepts Elmer Ng Award

Imaging. He helped organize the AUR meeting, where he was a Brogdon panel speaker on the topic “Universal Healthcare and Healthcare Delivery Reform: Challenges and Opportunities for Radiology.” He is a Resident’s and Fellows Section (RFS) Executive Board member of the California Radiological Society, and he organized and assisted in running the RFS meeting in October 2008.

- Adam Farkas, MD, received aSIR resident in training scholarship for the SIR annual meeting in March.
- Thomas Hope, MD, published: Hope TA, Herfkens RJ. Imaging of the Thoracic Aorta with Time-Resolved Three-Dimensional Phase-Contrast MRI: A Review. *Semin Thorac Cardiovasc Surg*. 2008 Winter;20(4):358-64; Hope TA, Zarins CK, Herfkens RJ. Initial Experience Characterizing a Type I Endoleak From Velocity Profiles Using Time Resolved Three Dimensional Phase Contrast MRI. *J Vasc Surg*. 2009 Jun;49(6):1580-4; Hope TA, Herfkens RJ, Denianke KS, Leboit PE, Hung YY, Weil E. Nephrogenic Systemic Fibrosis in Patients With Chronic Kidney Disease Who Received Gadopentetate Dimeglumine. *Invest Radiol*. 2009 Jan 15.[Epub ahead of print]; Hope MD, Purcell DD, Hope TA, von Morze C, Vigneron DB, Alley MT, Dillon WP. Complete Intracranial Arterial and Venous Blood Flow Evaluation With 4D Flow MR Imaging. *AJNR Am J Neuroradiol*. 2009 Feb;30(2):362-6 and Hope MD, Meadows AK, Hope TA, Ordovas KG, Reddy GP, Alley MT, Higgins CB. Images In

Cardiovascular Medicine. Evaluation of Bicuspid-Aortic Valve and Aortic Coarctation With 4D Flow Magnetic Resonance Imaging. *Circulation*. 2008 May 27;117(21):2818-9.

He also presented at several conferences: Hope TA, Chaopathomkul B, LeBoit PE, High WA, Rogut VS, Herfkens RJ, Brasch RC. Effect of Intravenous Iron on Nephrogenic Systemic Fibrosis in Rats. ISMRM, April 2009. [accepted abstract]; Hope TA, Herfkens RJ, Weil E. The Incidence of Nephrogenic Systemic Fibrosis in Patients with Renal Failure Who Have Received Gadopentetate Dimeglumine. Joint Annual Meeting ISMRM-ESMRMB, May 2008; and Hope TA, Hope MD, Bammer R, Alley MT. Combination Of Parallel Imaging And Cut-Corner Acquisition For Neurovascular 4D-Flow. Joint Annual Meeting ISMRM-ESMRMB, May 2008. Hope also reviewed abstracts for the Contrast section of ISMRM and reviewed his first paper for *Magnetic Resonance Imaging*.

- Nazia Jafri, MD, published: Jafri NF, Ayyala RS, Ozonoff A, Jordan-Gray J, and Slanetz PJ. Screening Mammography: Does Ethnicity Influence Patient Preferences for Higher Recall Rates Given the Potential for Earlier Detection of Breast Cancer? *Radiology*. 2008 Dec;249(3):785-91.; and Jafri NF, Wu P, Stanfield L, Slanetz PJ. Use of Radiologic Imaging to Enhance Physical Diagnosis Instruction in the Preclinical Curriculum. *Acad Radiol*. 2008 Jul;15(7):942-7.
- Peter Jun, MD is a chief resident of the UCSF Department of Radiology and Biomedical Imaging.
- Maureen Kohi, MD, received the T32 Training grant and the Seed Grant from the Department of Radiology and Biomedical Imaging to fund her research. Her research was accepted at the 12th annual scientific session of the Society of Cardiovascular Magnetic Resonance (SCMR) in January 2009, where she made an oral presentation. Kohi’s poster, “Complications of Abdominopelvic Laparoscopic Surgery: Imaging Features” was accepted at the 2009 Society of Gastrointestinal Radiology meeting. Her presentation “The Ends Do Not Justify the Means: Aberrant Courses of The Coronary Arteries” won a Certificate of Merit at the 2008 RSNA meeting. She also presented at American Roentgen Ray Society (ARRS). Her fellow residents selected Kohi to attend the RSNA/Association of University Radiologists and the ARRS Introduction to Research Program.

- Sharon Kwan, MD, presented at the 34th Annual Society of Interventional Radiology Meeting: Kwan SW, Fidelman N, Durack JC, LaBerge JM, Gordon RL, Kerlan RK. "Evaluation of the Portal Venous System with Transarterial CT Portography: Indications, Technique, and Examples", San Diego, CA, March 7-12, 2009. Kwan received the ACR Health Services Research Fellowship. She serves as a PGY5 resident representative on the Margulis Society board of directors.
- Michael Lu, MD, was a member of the 2009 ARRS Scientific Program Subcommittee (cardiopulmonary section). He served as a consultant to the *New England Journal of Medicine* Horizons Conference, "to help NEJM push the boundaries of traditional medical publishing." Lu made several oral presentations at RSNA 2008: Lu MT, Levit NA, Demehri S, Whitmore A, Ersoy H, Cai T, Rybicki FJ. "Prediction of 30-day Mortality after Acute Pulmonary Embolism (PE) Using Interval Increase in RV/LV Diameter Ratio Obtained from any Prior Contrast-enhanced Chest CT." Proceedings of the 94th Scientific Assembly and Annual Meeting of the RSNA, Chicago, USA, Nov 30 – Dec 05, 2008, which was briefly featured in the *RSNA Daily Bulletin*; RSNA Daily Bulletin, December 4, 2008: 6A. http://rsna2008.rsna.org/upload/35650_RSNA_Daily_Bulletin_Thurs.pdf; and "Pulmonary Embolism a Focus of Chest," Series Presentations, RSNA News 2009; March;19(3):11. http://www.rsna.org/Publications/rsnanews/March-2009/upload/RSNA_News_March2009.pdf (see page 11).

He published: Lu MT, Levit NA, Demehri S, Whitmore A, Ersoy H, Cai T, Rybicki FJ. Prediction of 30-day mortality after acute pulmonary embolism (PE) using interval increase in RV/LV diameter ratio obtained from any prior contrast-enhanced chest CT. Proceedings of the 94th Scientific Assembly and Annual Meeting of the RSNA, Chicago, USA, Nov 30 – Dec 05, 2008, *International Journal of Cardiovascular Imaging*

- Ginger Merry, MD, received a SIR resident in training scholarship for the SIR annual meeting in March.
- Reema Munir, MD, is a chief resident of the UCSF Department of Radiology and Biomedical Imaging program.
- David Naeger, MD, is a chief resident of the UCSF Department of Radiology and Biomedical Imaging program; chair of American Alliance of Academic Chiefs Residents in Radiology (A3R2); and is a limited member on the Academic University Radiologists Board. He serves as the UCSF

Radiology Residency coordinator on the Clinical Educator Track Committee. Naeger was named a T32 Research Fellow, beginning July 2009.

- Judong Pan, MD, published two articles: Meniscal T1rho Obtained with 3.0T MRI is Increased Directly After and 3 Months After Running A Marathon. Christoph Stehling, Anthony Luke, Robert Stahl, Thomas Baum, Judong Pan, Thomas M. Link, 95th RSNA Scientific Assembly and Annual Meeting, November 29-December 4, 2009, Chicago, Illinois; and Identification Of A Novel Common Proviral Integration Site, Flit-1, in Feline Leukemia Virus Induced Thymic Lymphoma. Fujino Y, Liao CP, Zhao YS, Pan J, Mathes LE, Hayes KA, Ohno K, Tsujimoto H, Roy-Burman P. *Virology*. 2009 Mar 30;386(1):16-22.
- Rainer Poley, MD, received the UCSF Department of Radiology and Biomedical Imaging Seed Grant for his project "Detection Of Early Hepatocellular Carcinoma: Incremental Benefit of Diffusion-Weighted And Hepatocyte-Selective Gadolinium Contrast-Enhanced MR Imaging," Poley RN and Qayyum A. He presented Poley RN, Steinbach LS, Riley GM, "Labral Tear or Normal Vessel? Blood Vessels Mimicking Pathology in Musculoskeletal MRI" at the Education Exhibit RSNA 2008, ECR 2009. He published Poley RN, Ho J, Gooding GA. Sonographic Findings Of Systemic And Hepatic Venous Gas Associated With Hemodialysis. *J Ultrasound Med* 2009 Apr; 28:533-536. Outside of the lab, Poley's team placed 22 out of 200 in the Camp Pendleton 10K Mud Run.
- Victor Sai, MD, serves as a PGY2 resident representative on the Margulis Society board of directors.
- John (Gabe) Schneider, MD, conducted research with Benjamin Yeh, MD, using intravenous contrast timing bolus to optimize scan quality and lesion conspicuity in the late arterial and portal venous phases on liver CT. His presentation of these data in an abstract titled, Schneider JG, Wang ZJ, Coakley FV, Joe BN, Yang Z, Yeh BM. "Hyper- And Hypovascular Liver Lesion Conspicuity: Comparison of Fixed Scan Delays Versus Patient-Specific Scan Delays Determined by a Novel Timing Bolus Method" at the Society of Computed Body Tomography and Magnetic Resonance 31st Annual Course in Charleston, SC won a "Cum Laude" award.

Schneider also presented data regarding late arterial phase scan quality at the 108th Annual Meeting of the ARRS in Washington: DC: Schneider JG, Wang ZJ, Coakley FV, Joe BN, Yang Z, Yeh BM. "Quality of Late Arterial Phase Hepatic CT: Comparison Of

Patient-Specific Scan Delays Determined by a Timing Bolus with Fixed Scan Delays.”

- **Fabio Settecase, MD**, was the presenting author at the American Society of Neuroradiology, 47th Annual Meeting: RS Desikan, HJ Cabral, F Settecase (presenting author), CP Hess, WP Dillon, CM Glastonbury, MW Weiner, NJ Schmansky, DN Greve, DH Salat, RL Buckner, B Fischl, and Alzheimer's Disease Neuroimaging Initiative, “Automated MRI Measures Of Regional Cortical Thickness And Gray Matter Volume Predict Progression From Mild Cognitive Impairment To Alzheimer's Disease”, Vancouver, Canada, May 17-21st, 2009. He also received a stipend/scholarship to attend the Introduction to Academic Radiology Program at the RSNA's 91st Scientific Meeting, Chicago, IL in 2008 and was the 2008-09 radiology resident representative to the UCSF Graduate Medical Education Committee.
- **Vinil Shah, MD**, serves as a PGY4 resident representative on the Margulis Society board of directors.
- **Timothy Shepherd, MD, PhD**, received the 2009 Margulis Society Research Grant and the 2009-10 T32 Fellowship, and was first author on: TM Shepherd, JJ Flint, PE Thelwall, GJ Stanisiz, TH Mareci, AT Yachnis, SJ Blackband. Postmortem Interval Alters the Water Relaxation and Diffusion Properties of Rat Nervous Tissue – Implications for MRI Studies Of Human Autopsy Samples. *Neuroimage* 2009;44(3):820-826; and TM Shepherd, PE Thelwall, GJ Stanisiz, SJ Blackband. Aldehyde Fixative Solutions Alter the Water Relaxation and Diffusion Properties of Nervous Tissue. *Magn. Res. Med.* (in press, 2009).
- **David Wilson MD, PhD**, published: Wilson DM, Hurd RE, Keshari K, Van Criekinge M, Chen AP, Nelson SJ, Vigneron DB, Kurhanewicz J. Generation of hyperpolarized substrates by secondary labeling with [1,1-¹³C] acetic anhydride. *Proc Natl Acad Sci.* 2009 Apr 7;106(14):5503-7.

In press are: Keshari, KR, Wilson DM, Chen, AP, Bok, R, Larson, PEZ, Hu, S, Macdonald, JM, Vigneron, DB and Kurhanewicz J “Hyperpolarized [2-¹³C]-Fructose: A New DNP Substrate for *In Vivo* Metabolic Imaging” and Keshari K, Kurhanewicz J, Wilson DM, Jeffries RE, Dewar BJ, Van Criekinge M, Vigneron DB, Macdonald JM. “Hyperpolarized ¹³C Spectroscopy and a Novel NMR-Compatible Bioreactor System For Investigation Of Real-Time Cellular Metabolism”.

His abstracts include: Wilson DM, Keshari K, Chen

A, Hu S, Larson P, Vigneron D, Kurhanewicz J. “Co-Polarization Of (1-¹³C) Pyruvate And ¹³C Sodium Bicarbonate by Dynamic Nuclear Polarization Allows Simultaneous Assessment of *In Vivo* Ph and Tumor Metabolism.” (ISMRM 2009, accepted for poster presentation); Wilson DM, Hurd RE, Keshari K, Van Criekinge M, Chen AP, Nelson SJ, Vigneron DB, Kurhanewicz J. “Generation Of Hyperpolarized Substrates by Secondary Labeling with [1,1-¹³C] Acetic Anhydride.” (ISMRM 2009, accepted for oral presentation); Wilson DM, Keshari K, Chen A, Hu S, Van Criekinge M, Larson P, Vigneron D, Kurhanewicz K. “Hyperpolarized [2-¹³C] Fructose: A New Probe for Dynamic Nuclear Presentation.” (ENC 2009, accepted for poster presentation); Wilson DM, Chen A, Hurd RE, Bok R, Park I, Kurhanewicz J, Nelson S, Vigneron D. “Hyperpolarized 1-[¹³C]- Ethyl Pyruvate: A New Probe For Metabolic Imaging of the Brain.” (ASNR 2009, accepted for oral presentation); Keshari K, Wilson DM, Chen A, Vigneron D, Kurhanewicz J. “Multimetabolite Spectroscopy using Dynamic Nuclear Polarization.” (ISMRM 2009, accepted for poster presentation); and Chen A, Cunningham CH, Wilson DM, Kohler SJ, Vigneron DB, Hurd RE. “Secondary Substrate Assisted Dynamic Nuclear Polarization.” (ISMRM 2009, accepted for poster presentation); and Chen A, Hurd RE, Wilson D, Gu Y, Wright G, Cunningham. “¹³C MRI Reporter Probe System With Dynamic Nuclear Polarization.” (ISMRM 2009, accepted for poster presentation).

Wilson was awarded both the departmental seed grant and the NIH training grant (NIBIB T32) for 2008 and the Margulis Society Resident Research Award.

- **Dorota Wisner, MD, PhD**, was the 2009 recipient of the AAWR Lucy Frank Squire Distinguished Resident Award in Diagnostic Radiology. She participated in several presentations: Jakubowski Wisner D, Chang B, Flowers C, Lessing J, Hwang S, Joe B, Hylton N, “Preoperative Breast MRI Accuracy for the Estimation Of DCIS Grade, Extent, and Occult Invasive Disease,” *Fifth Annual UCSF Imaging Research Symposium*, San Francisco, CA, 9/2008; Jakubowski Wisner D, Chang B, Flowers C, Joe B, Lessing J, Gibbs J, Itakura K, Hwang S, Hylton N, “Preoperative Breast MRI For Prediction Of Occult Invasive Disease,” *American Roentgen Ray Society Annual Meeting*, Boston, Mass., 4/2009; and Jakubowski Wisner D, Chang B, Tso H, Joe B, Lessing J, Gibbs J, Itakura K, Hwang S, Hylton N, “Kinetics and Morphology of Biopsy-Proven DCIS on Preoperative MRI: Can We Predict Occult Invasive Disease?,” *International Society of Magnetic Resonance in Medicine Annual Meeting*, Honolulu, Hawaii, April, 2009.

NUCLEAR MEDICINE RESIDENCY EXPANDS KNOWLEDGE BASE

In 2010, UCSF will graduate its first group of nuclear residents trained under the new, three-year requirements of the Accreditation Council for Graduate Medical Education. THE UCSF Nuclear Medicine Residency Program trains residents as experts in interpreting nuclear medicine imaging studies and the therapeutic application of radioisotopes. The 2009-10 nuclear medicine residents, David Carlson, MD, and Nhan Nguyen, MD, both in their final year as PGY4s will graduate with a full 12 months of computer tomography (CT), as well as wide exposure to future directions in molecular imaging, bio-medical physics, and cross-sectional imaging.

While many nuclear medicine residencies count PET/CT toward meeting the newer requirements, UCSF sets itself apart by having nuclear residents rotate through Chest and Abdominal Imaging for dedicated training in diagnostic CT, separate from PET/CT. Nuclear medicine residents complete their UCSF training competent in interpreting PET, PET/CT, SPECT, SPECT/CT, and all gamma camera studies.

A Daily Presence at China Basin

Nguyen and Carlson are the first nuclear medicine residents to have a daily presence at China Basin. They work with an attending physician using the state-of-the-art equipment available there. For example, the China Basin cyclotron enables production of radioisotopes not otherwise available due to their short half-lives. "Our nuclear medicine residents may be the only ones in the country able to learn how to do stress myocardial perfusion imaging using radio-labeled N-13 ammonia, thanks to our cyclotron," said Randall A. Hawkins, MD, PhD, who directs the residency program. "They also are able to use the China

Basin SPECT/CT camera. Examples of the techniques nuclear residents are able to perform using SPECT/CT include parathyroid sestamibi. This is not being done in very many places."

The residents have also learned how to:

- Use SPECT/CT lymphoscintigraphy for melanoma and breast cancer patients, providing surgeons with the exact anatomic location of sentinel nodes
- Perform lymph injections for breast surgeons; lymphoscintigraphy continues to be the only imaging modality able to confidently identify sentinel lymph nodes preoperatively
- Perform whole body SPECT/CT with I-123 MIBG for patients with neuroendocrine tumors, enabling clinicians to identify recurrence at an earlier stage, and to determine the best response to treatment with an increased confidence

Resident Presents at Professional Meetings

Nuclear Medicine Resident Dr. David Carlson presented an education exhibit at RSNA 2008 titled, "Making SUVs Work for You: Proper Use of SUVs in PET/CT Image Interpretation and Reporting." He also was invited to speak at the 2009 Northern California Society of Nuclear Medicine Chapter Meeting on "Thyrogen and Therapy." This discussion focused on the use of recombinant human TSH in preparing thyroid cancer patients for I-131 ablative treatment

following a total thyroidectomy. He co-presented a scientific poster at the 2009 Society of Nuclear Medicine Annual Meeting titled, "16 slice SPECT/CT May Decrease the Number of In-111 Labeled Antibodies anti-PSMA Scans Considered Inconclusive for Definitive Disease and Provide More Confidence on Positive Findings."



Nuclear Medicine Residents: David M. Carlson, MD, (left) and Nhan T. T. Nguyen, MD (right)

INCOMING DIAGNOSTIC RADIOLOGY RESIDENTS 2009

FIRST YEAR



Marjan S. Bolouri, MD

MD 2008 Baylor College of Medicine, Houston, Texas

2008-2009 Baylor College of Medicine, Houston, Texas

Internal Medicine Internship

Research:

2002-2003 Massachusetts Institute of Technology, Cambridge, Mass.

Publications:

Donnelly R, Bolouri MS, Prashad SJ, Coverdale JH, Hays JR, Kahn DA. Comorbid Capgras and Diogenes syndromes. *J Psychiatr Pract.* 2008 Sep;14(5):312-7.

Mootha VK, Bunkenborg J, Olsen JV, Hjerrild M, Wisniewski JR, Stahl E, Bolouri MS, Ra HN, Sihag S, Kamal M, Patterson N, Lander ES, Mann M. Integrated analysis of protein composition, tissue diversity, and gene regulation in mouse mitochondria. *Cell.* 2003 Nov 26; 115(5):629-40.



Matthew Bucknor, MD

MD 2008 Stanford University, School of Medicine, Palo Alto, Calif.

2008-2009 Kaiser Permanente, San Francisco, Calif.

Internal Medicine Internship

Research:

2008-2009 Kaiser Permanente, San Francisco, Calif.

2006-2007 University of California San Francisco, Cardiac Imaging and Interventional MRI Sections

2004-2005 Stanford University, School of Medicine; Palo Alto, Calif.

2002 Harvard Medical School, Department of Social Medicine, Boston, Mass.

Publications:

Hepworth EJ, Bucknor M, Patel A, and Vaughan WC. Nationwide survey on the use of image-guided functional endoscopic sinus surgery. *Otolaryngol Head Neck Surg.* 2006; 135:68-73.

Jacquier A, Bucknor M, Do L, Robert P, Corot C, Higgins CB, Saeed M. P846, a new gadolinium based low diffusion magnetic resonance contrast agent, in characterizing occlusive infarcts, reperfused ischemic myocardium and reperfused infarcts in rats. *MAGMA.* 2008 May;21(3):207-18.

Saeed M, Martin A, Jacquier A, Bucknor M, Saloner D, Do L, Ursell P, Su H, Kan YW, Higgins CB. Permanent coronary artery occlusion: cardiovascular MR imaging is platform for percutaneous transendocardial delivery and assessment of gene therapy in canine model. *Radiology.* 2008 Nov;249(2):560-71.

Saeed M, Martin A, Ursell P, Do L, Bucknor M, Higgins CB, Saloner D. MR assessment of myocardial perfusion, viability, and function after intramyocardial transfer of VM202, a new plasmid human hepatocyte growth factor in ischemic swine myocardium. *Radiology.* 2008 Oct;249(1):107-18.



Abby E. Deans, MD

MD 2008 New York University School of Medicine, New York

PhD 2008 New York University School of Medicine, New York

2008-2009 St. Mary's Medical Center, San Francisco, Calif.

Preliminary Medicine Intern

Research:

8/2002-5/2008 New York University School of Medicine, New York

Publications:

Deans AE, Wadghiri YZ, Bernas LM, Yu X, Rutt BK, Turnbull DH. Cellular MRI

contrast via coexpression of transferrin receptor and ferritin. *Magn Reson Med.* 2006 Jul;56(1):51-9.

Moy L, Ponzo F, Noz ME, Maguire GQ Jr, Murphy-Walcott AD, Deans AE, Kitazono MT, Travascio L, Kramer EL. Improving specificity of breast MRI using prone PET and fused MRI and PET 3D volume datasets. *J Nucl Med.* 2007 Apr;48(4):528-37.

Yang X, Liu H, Li D, Zhou X, Jung WC, Deans AE, Cui Y, Cheng L. Digital optical imaging of green fluorescent proteins for tracking vascular gene expression: feasibility study in rabbit and human cell models. *Radiology.* 2001 Apr;219(1):171-5.



Thor Johnson, MD, PhD

MD 2008 Indiana University School of Medicine, Indianapolis, Ind.
PhD 2007 Indiana University, Bloomington, Ind.
2008-2009 St. Vincent Hospital, Indianapolis, Ind.
Medicine Internship

Research:

2004-2006 National Heart, Lung, and Blood Institute, National Institutes of Health, Laboratory of Cardiac Energetics, Bethesda, Maryland

2004-2006 Indiana University, School of Medicine, Department of Biochemistry and Cell Biology, Indianapolis, Ind.

Publications:

Aponte AM, Phillips D, Harris RA, Blinova K, French S, Johnson DT, Balaban RS. 32P labeling of protein phosphorylation and metabolite association in the mitochondria matrix. *Methods Enzymol.* 2009;457:63-80.

Aponte AM, Phillips D, Hopper RK, Johnson DT, Harris RA, Blinova K, Boja ES, French S, Balaban RS. Use of (32)P to study dynamics of the mitochondrial phosphoproteome. *J Proteome Res.* 2009 Jun;8(6):2679-95.

Hopper RK, Carroll S, Aponte AM, Johnson DT, French S, Shen RF, Witzmann FA, Harris RA, Balaban RS. Mitochondrial matrix phosphoproteome: effect of extra mitochondrial calcium. *Biochemistry.* 2006 Feb 28;45(8):2524-36.

Johnson DT, Harris RA, Blair PV, Balaban RS. Functional consequences of mitochondrial proteome heterogeneity. *Am J Physiol Cell Physiol.* 2007 Feb;292(2):C698-707.

Johnson DT, Harris RA, French S, Aponte A, Balaban RS. Proteomic changes associated with diabetes in the BB-DP rat. *Am J Physiol Endocrinol Metab.* 2009 Mar;296(3):E422-32.

Johnson DT, Harris RA, French S, Blair PV, You JS, Bemis KG, Wang M, and Balaban RS. Tissue heterogeneity of the mammalian mitochondrial proteome. *Am J Physiol Cell Physiol.* 2007 Feb;292(2):C689-97.



Lauren A. Kahn, MD

MD 2008 Duke University, Durham, N.C.
2008-2009 Lenox Hill Hospital, New York, N.Y.
Internal Medicine Internship

Research:

2006-2007 Duke University Medical Center, Douglas Tyler Surgical Oncology Laboratory, Durham, N.C.

2003-2004 Duke University Medical Center, Bruce Klitzman Plastic Surgery Laboratory, Durham, N.C.



Alexander W. Keedy, MD

MD 2008 University of California Irvine School of Medicine, Irvine
2008-2009 Kaiser Permanente, Oakland, Calif.
Internal Medicine Internship

Research:

2006-2009 University of California, San Francisco, Department of Radiology and Biomedical Imaging

2002-2003 Santa Clara University, Santa Clara, Calif.

2001-2003 Galileo Laboratories, Santa Clara, Calif.

Publications:

Keedy A. An overview of intracranial aneurysms. *McGill J Med.* 2006 Jul;9(2):141-6.

Keedy A, Westphalen AC, Qayyum A, Aslam R, Rybkin AV, Chen MH, Coakley FV. Diagnosis of cirrhosis by spiral computed tomography: a case-control study with feature analysis and assessment of interobserver agreement. *J Comput Assist Tomogr.* 2008 Mar-Apr;32(2):198-203.

**Kevin Koo, MD**

MD 2008 University of California, Los Angeles, David Geffen School of Medicine, Los Angeles
 2008-2009 Santa Clara Valley Medical Center, San Jose, Calif.
 Internal Medicine Internship

Research:

2007-2008 University of California, Los Angeles, Department of Radiological Sciences
 2007 University of California, Los Angeles, Departments of Pediatrics and Radiology
 2006 University of California, Los Angeles, Department of Pediatrics and Surgery
 2005 University of California, Los Angeles, Department of Cardiothoracic Surgery

**John Mongan, MD**

MD 2008 University of California, San Diego, San Diego
 PhD 2008 University of California, San Diego, San Diego
 2008-2009 Kaiser Permanente, Oakland, Calif.
 Internal Medicine Internship

Publications:

Hamelberg D, Mongan J, McCammon JA. Accelerated molecular dynamics: a promising and efficient simulation method for biomolecules. *J Chem Phys.* 2004 Jun 22;120(24):11919-29.

Lewis JA, Mongan J, McCammon JA, Cohen SM. Evaluation and binding-mode prediction of thiopyrone-based inhibitors of anthrax lethal factor. *ChemMedChem.* 2006 Jul;1(7):694-7.

Mongan J, Case DA. Biomolecular simulations at constant pH. *Curr Opin Struct Biol.* 2005 Apr;15(2):157-63.

Mongan J, Svrcek-Seiler WA, Onufriev A. Analysis of integral expressions for effective Born radii. *J Chem Phys.* 2007 Nov 14;127(18):185101.

Swanson JM, Mongan J, McCammon JA. Limitations of atom-centered dielectric functions in implicit solvent models. *J Phys Chem B.* 2005 Aug 11;109(31):14769-72.

**Victor F. Sai, MD**

MD 2008 University of California, Los Angeles, David Geffen School of Medicine, Los Angeles
 2008-2009 University of Hawai'i, Manoa Internship
 2007 Alpha Omega Alpha

Research:

2005-2008 University of California, Los Angeles, David Geffen School of Medicine, Department of Radiology, Los Angeles

2004 Massachusetts Institute of Technology/Harvard, Division of Health Sciences and Technology, Cambridge, Mass.

Publications:

Pope WB, Kim HJ, Huo J, Alger J, Brown MS, Gjertson D, Sai V, Young JR, Tekchandani L, Cloughesy T, Mischel PS, Lai A, Nghiemphu P, Rahmanuddin S, Goldin J. Recurrent glioblastoma multiforme: ADC histogram analysis predicts response to bevacizumab treatment. *Radiology.* 2009 Jul;252(1):182-9.

**Ronnie A. Sebro, MD, PhD**

MD 2008 University of California San Francisco, School of Medicine, San Francisco
 PhD 2007 Harvard University, Graduate School of Arts and Sciences, Cambridge, Mass.

Research:

2003-05 Stanford University, Department of Genetics, Palo Alto, Calif.
 1999-2001 Harvard Medical School/McLean Hospital, Boston, Mass.

Publications:

Berretta S, Lange N, Bhattacharyya S, Sebro R, Garces J, Benes FM. Long-term effects

of amygdala GABA receptor blockade on specific subpopulations of hippocampal interneurons. *Hippocampus.* 2004;14(7):876-94.

Stone DJ, Walsh JP, Sebro R, Stevens R, Pantazopoulos H, Benes FM. Effects of Pre- and Post-natal Corticosterone Exposure on the Rat Hippocampal GABA System *Hippocampus.* 2001;11(5):492-507.

Urban TJ, Sebro R, Hurowitz EH, Leabman MK, Badagnani I, Lagpacan LL, Risch N, Giacomini KM. Functional genomics of membrane transporters in human populations. *Genome Res.* 2006 Feb;16(2):223-30.



Leo P. Sugrue, MD, PhD

MD 2007 Johns Hopkins University,
School of Medicine, Baltimore, Maryland
PhD 2008 Stanford University, School of
Medicine, Palo Alto, Calif.
2007-2008 Stanford University Hospital
and Clinics, Palo Alto, Calif.
Internal Medicine Internship

Research:

2008-2009 Stanford University, Howard
Hughes Medical Institute, Palo Alto, Calif.
2004-2007 Max Planck Institute for
Biological Cybernetics, Laboratory of Nikos
Logothetis, Tübingen, Germany

Publications:

Corrado GS, Sugrue LP, Seung HS, Newsome
WT. Linear-Nonlinear-Poisson models of
primate choice dynamics. *J Exp Anal Behav*.
2005 Nov;84(3):581-617
Sugrue LP, Corrado GS, Newsome WT.
Choosing the greater of two goods: neural
currencies for valuation and decision making.
Nat Rev Neurosci. 2005 May;6(5):363-75.
Sugrue LP, Corrado GS, Newsome WT.
Matching behavior and the representation of
value in the parietal cortex. *Science*. 2004 Jun
18;304(5678):1782-7.



S. Jarrett Wrenn, MD, PhD

MD 2008 Stanford University School of
Medicine, Medical Scientist Training Program,
Palo Alto, Calif.
PhD 2008 Stanford University School of
Medicine, Medical Scientist Training Program,
Palo Alto, Calif.
2008-2009 Kaiser Permanente-San
Francisco, San Francisco, Calif.
Internal Medicine Preliminary Internship

Research:

2000-2008 Stanford University School of
Medicine, Department of Biochemistry, Palo
Alto, Calif.

Publications:

Wrenn SJ, Harbury PB. Chemical evolution
as a tool for molecular discovery. *Annu Rev
Biochem*. 2007;76:331-49. Review.
Wrenn SJ, Weisinger RM, Halpin DR,
Harbury PB. Synthetic ligands discovered by
in vitro selection. *J Am Chem Soc*. 2007 Oct
31;129(43):13137-43.



Etay Ziv, MD

MD 2008 Columbia University, College of Physicians & Surgeons, New York, N.Y.

PhD 2006 Columbia University Department of Biomedical Engineering, New York, N.Y.

2008-2009 Mt. Sinai Hospital, New York, N.Y.

Internal Medicine Internship

Research:

2006 Lawrence Berkeley National Laboratory, Berkeley, Calif.

2002-2006 Columbia University Departments of Biomedical Engineering and Applied Mathematics, New York, N.Y.

Publications:

Dotan I, Ziv E, Dafni N, Beckman JS, McCann RO, Glover CV, Canaani D. Functional conservation between the human, nematode, and yeast CK2 cell cycle genes. *Biochem Biophys Res Commun*. 2001 Nov 2;288(3):603-9.

Middendorf M, Ziv E, Wiggins CH. Inferring network mechanisms: the *Drosophila melanogaster* protein interaction network. *Proc Natl Acad Sci U S A*. 2005 Mar 1;102(9):3173-4.

Mugler A, Ziv E, Nemenman I, Wiggins CH. Serially regulated biological networks fully realise a constrained set of functions. *IET Syst Biol*. 2008 Sep;2(5):313-22.

Ziv E, Koytcheff R, Middendorf M, Wiggins C. Systematic identification of statistically significant network measures. *Phys Rev E Stat Nonlin Soft Matter Phys*. 2005 Jan;71(1 Pt 2):016110.

Ziv E, Middendorf M, Wiggins CH. Information-theoretic approach to network modularity. *Phys Rev E Stat Nonlin Soft Matter Phys*. 2005 Apr;71(4 Pt 2):046117.

Ziv E, Nemenman I, Wiggins CH. Optimal signal processing in small stochastic biochemical networks. *PLoS One*. 2007 Oct 24;2(10):e1077.

SECOND YEAR



Vishal K. Agarwal, MD

MD 2009 University of California, Los Angeles, David Geffen School of Medicine, Los Angeles

2007-2008 Olive View-UCLA Medical Center, Sylmar, Calif.

Internal Medicine Internship

Research:

9/2005-2009 University of California, Los Angeles, Department of Radiology, Los Angeles

6/2004 - 2009 Cedars-Sinai Medical Center, Department of Pediatrics and Medical Genetics, Los Angeles, Calif.

2001 - 2004 University of California, Los Angeles, Department of Radiology, Department of Microbiology and Immunology, Los Angeles, Calif.

Publications:

Agarwal VK, Lachman RS, Rimoin DL, Wilcox WR. Spondylo-mega-epiphyseal dysplasia with prominent upper limb mesomelia, punctate calcifications, and deafness. *Am J Med Genet A*. 2005 Jul 30;136(3):233-41.

Ronni T, Agarwal V, Haykinson M, Haberland ME, Cheng G, Smale ST. Common interaction surfaces of the toll-like receptor 4 cytoplasmic domain stimulate multiple nuclear targets. *Mol Cell Biol*. 2003 Apr;23(7):2543-55.

SECOND, THIRD AND FOURTH YEAR DIAGNOSTIC RADIOLOGY RESIDENTS 2009-2010

Second Year Residents

Vishal Agarwal, MD
Ingrid Burger, MD, PhD
Renu Chundru, MD
Thomas Hope, MD
Nazia F. Jafri, MD
Marc A. Laberge, MD
Michael T. Lu, MD
Ginger Merry, MD, MPH
Michael A. Ohliger, MD, PhD
J. Gabe Schneider, MD
Ania J. Szary, MD
Jason F. Talbott, MD, PhD
Kiarash Vahidi, MD

Third Year Residents

Gloria Chia-Yi Chiang, MD
Jose Juan Diaz-Hernandez, MD
Adam Farkas, MD
Jeffrey J. Hom, MD
K. Pallav Kolli, MD
Moiria A. O'Riordan, MD
Judong Pan, MD, PhD
Maria Parayno, MD
Andrew Phelps, MD
Fabio Settecasse, MD
Vinil N. Shah, MD
Timothy M. Shepherd, MD, PhD
Divya Sridhar, MD
Andrew G. Taylor, MD, PhD
Max Chang Wu, MD, PhD

Fourth Year Residents

Peter Jun, MD, Chief
Nayela N. Keen, MD
Maureen P. Kohi, MD
Shilpa R. Kumbhani, MD
Sharon W. Kwan, MD
Heather G. Moreno, MD
Reema M. Munir, MD, Chief
David M. Naeger, MD, Chief
Rainer N. Poley, MD
Lauren B. Rahe, MD
Katherine J. To'o, MD

NUCLEAR MEDICINE RESIDENTS 2009-2010

David M. Carlson, MD

Nhan T. T. Nguyen, MD

CLINICAL FELLOWS/INSTRUCTORS IN RADIOLOGY 2009-2010

Letizia Antonietti, MD
Neurointerventional

Courtney Bloomer, MD
Neuroradiology

Natasha Brasic, MD
Ultrasound/Women's Imaging

Peter Chuang, MD
SFGH

Jesse Courtier, MD
Pediatrics

Hamed Fared, MD
Neurointerventional

Cormac Farrelly, MD
Interventional

Zachary Fisher, MD
Musculoskeletal

Eugene Hagiwara, MD
Interventional

Heidi Henslee, MD
SFGH

Richard Hong, MD
Musculoskeletal

Michael Hope, MD
Cardiac and Pulmonary Imaging

Sapna Jain, MD
Neuroradiology

Adam Jung, MD, PhD
Abdominal Imaging

Zina Kellow, MD
Ultrasound/Women's Imaging

James Kim, MD
Abdominal Imaging

Joseph Kim, MD
SFGH

Warren Kim, MD
Neuroradiology

Stephen Kralik, MD
Neuroradiology

Pamela Mallari, MD
Interventional

Anna Meyerson, MD
Women's Imaging

Thomas Nguyen, MD
Abdominal Imaging

Robin Olander, MD
VAMC

Eleanor Ormsby, MD
Abdominal Imaging

Joseph Park, MD
Interventional

Nandini Patel, MD
Neuroradiology

Ramin Saket, MD
Neuroradiology

Robert Shih, MD
Neuroradiology

Ravi Singh, MD
Musculoskeletal

Yee-Li Sun, MD
Abdominal Imaging

James Tatum, MD
Neurointerventional

Thomas Urbania, MD
Cardiac and Pulmonary Imaging

Alina Uzelac, DO
Neuroradiology

Jessica Walls, MD
Abdominal Imaging

David Wilson, MD, PhD
Neuroradiology

Dorota Wisner, MD, PhD
Women's Imaging

Sun Young, MD
Neuroradiology

RADIOLOGY RESIDENT GRADUATES CLASS OF 2009

Congratulations to our 2009 graduates. We wish them success in their new positions.

Natasha Brasic, MD

Fellowship in Ultrasound and Women's Imaging, UCSF

Jeremy D. Collins, MD

Clinical Cardiovascular Fellowship, Northwestern Memorial Hospital, Chicago, Ill.

Michael D. Hope, MD

Fellowship in Cardiac and Pulmonary Imaging, UCSF

Sapna K. Jain, MD

Fellowship in Neuroradiology, UCSF

Amita Kamath, MD

Fellowship in Body MR/Cardiovascular Imaging, New York University, New York, N.Y.

Jafi A. Lipson, MD

Fellowship in Breast Imaging, Stanford University, Palo Alto, Calif.

Anna F. Meyerson, MD

Fellowship in Women's Imaging, UCSF

Michael D. Ringler, MD

Fellowship in Musculoskeletal Imaging & Intervention, Mayo Clinic, Rochester, Minn.

Akhilesh K. Sista, MD

Stanford Biodesign Fellowship, Palo Alto, Calif.

Yee-Li Sun, MD

Fellowship in Abdominal Imaging, UCSF

Thomas H. Urbania, MD

Fellowship in Cardiac and Pulmonary Imaging, UCSF

David M. Wilson, MD, PhD

Fellowship in Neuroradiology, UCSF

Dorota Jakubowski Wisner, MD, PhD

Fellowship in Women's Imaging, UCSF



2009 Diagnostic Radiology Resident Graduates: (l-r) Yee-Li Sun, MD, Akhilesh K. Sista, MD, Michael D. Ringler, MD, David M. Wilson, MD, PhD, Thomas H. Urbania, MD, Michael D. Hope, MD, Jafi A. Lipson, MD, Natasha Brasic, MD, Amita Kamath, MD, Dorota Jakubowski Wisner, MD, PhD, Anna F. Meyerson, MD, Jeremy D. Collins, MD (Sapna K. Jain, MD, not pictured).

BLUMENKRANZ, LARSON, AND PARK EARN YOUNG INVESTIGATORS' AWARDS FROM THE SURBECK LABORATORY OF ADVANCED IMAGING

By Hillie Cousart, PhD

On May 1, Gabby Blumenkrantz, Peder Larson, PhD, and Ilwoo Park presented the research papers that earned them Young Investigator awards from the INDNJC Foundation. The director of the Surbeck Laboratory of Advanced Imaging, Professor Sarah J.

Nelson, PhD, moderated the mini-symposium along with Richard Gowen, PhD, president of the Board of the INDNJC Foundation. The audience in Byers Auditorium in Genentech Hall included members of the UCSF research community, representatives of the INDNJC Board, and friends of Margaret Hart Surbeck.

The Margaret Hart Surbeck Laboratory of Advanced Imaging is dedicated to improving high-field imaging to advance our understanding of a wide range of diseases and to assess emerging treatments. The primary focus is on maximizing the potential to use imaging in evaluating and treating cancer, neurologic, and musculoskeletal diseases. Each year, approximately 30 postdoctoral fellows and graduate students receive training under the guidance of the lab's principal investigators. This year, these young scholars submitted 22 articles in the competition for awards established through the INDNJC Foundation in honor of Margaret Hart Surbeck. The awards provide small grants for career development.

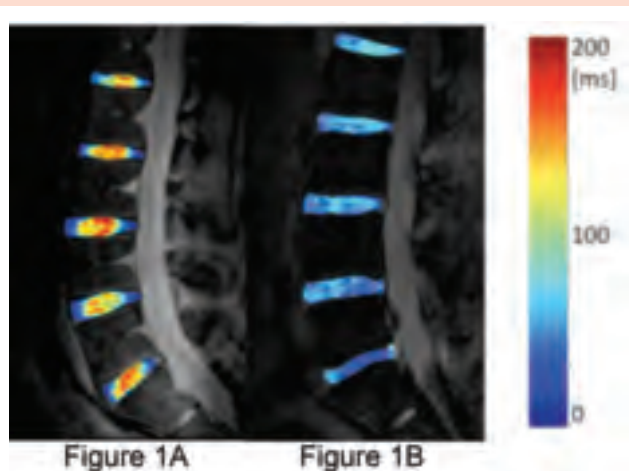


Figure 1: A representative T1ρ color map of a healthy subject (1A) and a subject with disc degeneration (1B). The T1ρ values in the healthy discs are greater than those in the degenerative discs

First Place Study of Clinical Symptoms of Intervertebral Disc Degeneration

Top honors went to Gabby Blumenkrantz for “*In Vivo* 3 Tesla Magnetic Resonance T1ρ and T2 Relaxation Mapping in subjects with Intervertebral Disc Degeneration and Clinical Symptoms,” Blumenkrantz G, Zuo J, Li X, Kornak J, Link TM, Majumdar S. *Magnetic Resonance in Medicine* 2009, submitted.

Despite the high prevalence of intervertebral disc degeneration (IVDD) worldwide, diagnosis in the early stages of symptomatic disease is elusive in clinical practice. Recent studies have proposed that MRI T1ρ and T2 relaxation times are associated with early degenerative changes in the extracellular matrix of the disc. This study evaluated the relationship between T1ρ and T2 relaxation time and degenerative grade in intervertebral discs using *in vivo* MR imaging at 3 Tesla, and investigated the relationship between T1ρ and T2 relaxation time and clinical findings as quantified by the SF-36 questionnaire

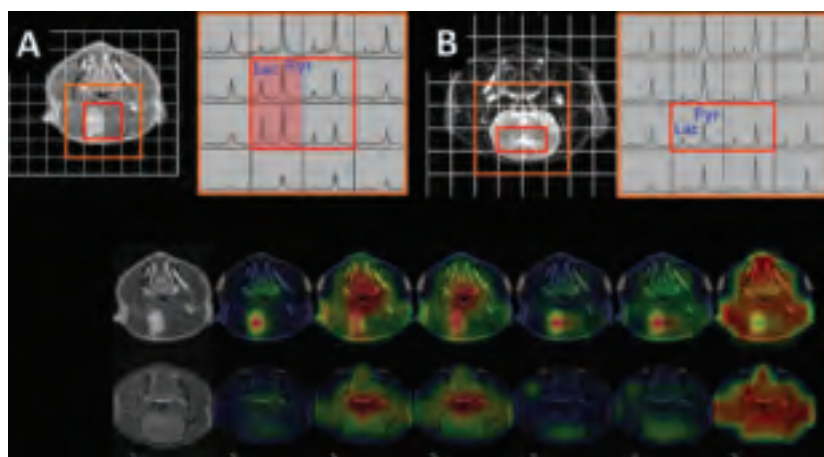


Figure 2: Comparison between hyperpolarized carbon-13 spectra and the corresponding anatomical images between a rat with intracranial tumor (A) and a control rat (B). Carbon-13 spectra in the contrast-enhancing lesion of the rat with tumor show highly elevated lactate and pyruvate peak. Metabolic maps of carbon-13 imaging parameters (C) also show significant differences between a rat with tumor and a control rat.

(physical health) and Oswestry Disability Index (ODI). The 16 participants in the study completed SF-36 and ODI questionnaires. *In vivo* 3.0 Tesla MRI T1r and T2 mapping was performed to quantify T1r and T2 relaxation times in the nucleus of the intervertebral disc and T2-weighted images were acquired for Pfirrmann grading (degenerative grade). The study demonstrated a negative relationship between Pfirrmann grade and relaxation time. In addition, T1r relaxation time was significantly associated with clinical symptoms, quantified using the SF-36 and ODI questionnaires. This study suggests that T1r relaxation time may be sensitive to early degenerative changes and clinical symptoms in intervertebral disc degeneration. (See Figure 1)

Blumenkrantz is a PhD candidate in the UCSF/UCB Joint Graduate Group in Bioengineering. She works in the Musculoskeletal and Quantitative Imaging Research Group directed by Sharmila Majumdar, PhD, and Thomas Link, MD, PhD. Blumenkrantz received her BS in Mechanical Engineering from UC Berkeley.

Tumor Hyperpolarized Pyruvate Dynamics

Peder Larson's paper "Investigation of Tumor Hyperpolarized [1-13C]-Pyruvate Dynamics using Time-Resolved Multiband RF Excitation Echo-planar MRSI" Larson PEZ, Bok R, Kerr AB, Lustig M, Hu S, Chen AP, Nelson SJ, Pauly JM, Kurhanewicz J, Vigneron DB. IEEE Transactions on Medical Imaging 2009, submitted, took second place.

Hyperpolarized 13C-labeled pyruvate allows for rapid *in vivo* imaging of cellular metabolism, which has a great potential for improved assessment of prostate tumors by monitoring conversion to lactate. This study applied a new, time-resolved MR spectroscopic imaging method to a prostate tumor mouse model to

improve characterization of tumor tissue. This new method, also developed by the authors, uses a novel RF excitation pulse to acquire dynamic data, and a rapid sampling scheme. The method provided information on tissue uptake, perfusion, and vascularization, as well as metabolism, enabling a more complete tissue characterization. The prostate tumors were found to have distinct lactate dynamic parameters as well as varying degrees of vascularization.


Larson is a postdoctoral scholar with working with Daniel Vigneron, PhD, on technical developments for hyperpolarized Carbon-13. Larson received his PhD in Electrical Engineering from Stanford University.

Applying Hyperpolarized 13C MR Metabolic Imaging to Brain Tumors

The third award was given to Ilwoo Park for "Hyperpolarized 13C MR Metabolic Imaging: Application to Brain Tumors," Park I, Larson PEZ, Zierhut ML, Hu S, Bok R, Ozawa T, Kurhanewicz J, Vigneron DB, VandenBerg SR, James CD, Nelson SJ. Neuro-Oncology 2009, In Press.

Dynamic nuclear polarization and the recent development of a dissolution process enable the real-time investigation of *in vivo* metabolism with a more than 10,000-fold signal increase over conventional 13C spectroscopic methods. This study aimed to explore, for the first time, the feasibility of using 13C MR spectroscopic imaging (MRSI) with hyperpolarized [1-13C]-pyruvate as a substrate for brain tumor and to compare 13C imaging parameters with results from pathological analysis between U-251 MG and U-87 MG tumor models. Statistical tests showed significant differences in all 13C imaging parameters between the malignant glioma tissue and normal brain. The amount of lactate, pyruvate, and total carbon differed between two tumor types, consistent with inherent differences in the molecular characteristics found in the pathology of these tumors. These results suggest that hyperpolarized MR metabolic imaging may be valuable for assessing prognosis and monitoring response to therapy for patients with brain tumors. (See Figure 2)

Park is a PhD candidate in the UCSF/UCB Joint Graduate Group in Bioengineering. He works in Nelson's group developing MR biomarkers for evaluating prognosis and response to therapy in brain tumor patients. Park received his BS in Bioengineering from University of California, Berkeley.



Left to right: Ilwoo Park, Gabby Blumenkrantz, Peder Larson

NEW FACULTY APPOINTMENTS

Joseph C. Giaconi, MDAssistant Clinical Professor
Musculoskeletal Imaging

Joseph C. Giaconi received his medical degree in 2003 from the University of Southern California, Los Angeles. In 2004 he completed a one-year internship at the University of Hawai'i, Honolulu. Giaconi finished a four-year diagnostic radiology residency in 2008 at the University of Southern California. This was followed by a one-year fellowship in the musculoskeletal section at UCSF. Giaconi's interests include musculoskeletal MRI, specifically ACL graft integrity. He is also interested in radiology education. Giaconi accepted an assistant clinical professor of radiology position in the Musculoskeletal section in July 2009.



Joseph C. Giaconi, MD

Galatea J. Kazakia, PhDAssistant Professor in
Residence
Musculoskeletal and
Quantitative Imaging
Research Group
China Basin

In 2004, Galatea J. Kazakia received her PhD in mechanical engineering, with her major fields being bioengineering and materials. Kazakia joined UCSF Radiology and Biomedical Imaging's Musculoskeletal and Quantitative Imaging Research Group (MQIR) in 2004 as a postdoctoral scholar. She was awarded the Young Investigator Award at the 36th International Sun Valley Workshop on Skeletal Biology in 2006, and received an Excellence in Research Award from MQIR the same year. She was awarded a National Institutes of Health (NIH) National Research Service Award for 2006-08. In April 2009, Kazakia accepted the position of assistant professor in residence in the MQIR group.

Kazakia's main research interest is the characterization



Galatea J. Kazakia, PhD

of bone structure and composition in osteoporosis and other diseases using both *ex vivo* and *in vivo* high-resolution imaging techniques. Her work focuses on developing techniques in micro-computed tomography (microCT), high-resolution peripheral quantitative CT (HR-pQCT), Fourier transform infrared (FTIR) imaging, and 3D histology for the assessment of bone quality.

Jane Kim, MDAssistant Professor of
Clinical Radiology
Neuroradiology
San Francisco General
Hospital

Jane J. Kim received her medical degree in 2003 from the University of California, San Francisco, followed by a one-year internship in internal medicine at Mount Sinai Hospital in New York, N.Y. Returning to UCSF, Kim completed her diagnostic radiology residency in 2008 and a neuroradiology fellowship in 2009. Kim's research interests include CT angiography (CTA) and CT perfusion (CTP) for patients with acute cerebrovascular events (stroke or transient ischemic attack). In July 2009, she accepted the position of assistant professor of clinical radiology.



Jane Kim, MD

Alexander P. Nguyen, MDAssistant Clinical Professor
Abdominal Imaging
San Francisco Veterans
Affairs Medical Center

Alexander P. Nguyen received his MD from the University of New Mexico, School of Medicine in 2002, followed by a one-year internship in internal medicine at the University of New Mexico Health Sciences Center in Albuquerque. In 2008, he completed a four-year diagnostic radiology residency at Drexel College of Medicine in Pittsburgh, Penn. He completed a one-year fellowship in abdominal imaging at UCSF in June 2009. Kim accepted the position of assistant clinical professor in the Department of Radiology and Biomedical Imaging in July 2009.



Alexander P. Nguyen, MD

Miguel Hernandez Pampaloni, MD, PhD

Assistant Professor in Residence
Nuclear Medicine

In 1990, Miguel Hernandez Pampaloni received his medical degree from Complutense University of Madrid, in Madrid, Spain. He completed his training in nuclear medicine at San Carlos Hospital, Complutense University of Madrid in 1996, followed by a PhD in radiological sciences in 1998. From 1998-2002, Hernandez Pampaloni was a postdoctoral fellow in PET Imaging in the Department of Molecular and Medical Pharmacology, at the David Geffen School of Medicine, University of California, Los Angeles. In 2002-03 Hernandez Pampaloni served as a clinical research fellow in PET Cardiology at Imperial College of Medicine, London, U.K. Hernandez Pampaloni completed a nuclear medicine residency at the University of Pennsylvania, Philadelphia in 2008. He finished a postdoctoral fellowship at the same institution in 2008, followed by a clinical instructorship. In February 2009, Hernandez Pampaloni accepted the position of assistant professor in residence in the Nuclear Medicine Section.



Miguel Hernandez Pampaloni, MD, PhD

John Van Uden, MD, PhD

Assistant Clinical Professor
Thoracic Imaging
San Francisco General
Hospital

John Van Uden completed the Medical Scientist Training Program at the University of California, San Diego, where he earned a PhD in Biomedical Sciences in 2001, followed by an MD in 2003. In 2004, he completed an internal medicine internship at UCSD, followed by a diagnostic radiology residency at UCSF from 2004-08. Van Uden completed a one-year clinical fellowship in the sections of Abdominal Imaging and Cardiac and Pulmonary Imaging at UCSF in 2009. Van Uden accepted the position of assistant clinical professor at SFGH in July 2009.



John Van Uden, MD, PhD

Stefanie Weinstein, MD

Assistant Clinical Professor
Abdominal Imaging
San Francisco Veterans
Affairs Medical Center

Stefanie Weinstein received her MD in 2000 from Cornell University, Weill Medical College in New York, New York. She completed an internship in Internal Medicine at Lenox Hill Hospital, New York, in 2001. In 2005, Weinstein finished a four-year diagnostic radiology residency at Stanford University Medical Center, Palo Alto, Calif., serving as chief resident in 2003-04. This was followed by a one-year body imaging fellowship at Stanford University Medical Center. From 2006-09 she worked at the Santa Clara Valley Medical Center, Department of Radiology where she served as section chief of the Musculoskeletal Imaging division. In September 2009, Weinstein accepted the position of assistant clinical professor in the VAMC's Abdominal Imaging section.



Stefanie Weinstein, MD

Esther L. Yuh, MD, PhD

Assistant Professor in
Residence
Neuroradiology

In 1995, Esther L. Yuh received her PhD in Physics from the University of California, Santa Barbara. At Stanford University, Palo Alto, Calif., she completed a postdoctoral fellowship in physics (1996), followed by a postdoctoral fellowship in Radiology (1998). Yuh received her medical degree from Stanford University in 2002, followed by an internship in internal medicine, also at Stanford. Yuh completed a diagnostic radiology residency in 2007. She completed a neuroradiology fellowship in 2008 and was appointed a clinical instructor in 2008-09. Her areas of interest include head trauma, stroke, and computer-aided detection. In July 2009, Yuh accepted an assistant professor in residence position in Neuroradiology at UCSF.



Esther L. Yuh, MD, PhD

FACULTY ON THE MOVE

Ashley Aiken, MD, former assistant professor in the Neuroradiology section, departed in June to accept a position at Emory University, Neuroradiology Department, in Atlanta, Ga.

Ying Lu, PhD, former professor in residence and director of the Biostatistics/Outcomes Specialized Resources Group, departed in June to accept a position as professor of Biostatistics, Department of Health Research and Policy, and Director, Veterans Affairs Cooperative Studies Program at Stanford University, Palo Alto, Calif.

Sven Prevrhal, PhD, former assistant adjunct professor in the Musculoskeletal and Quantitative Imaging Research Interest Group departed in June to accept a position as a research scientist at Philips Medical Systems in the San Francisco Bay Area.

Hilda Tso, MD, former assistant clinical professor in the Women's Imaging section will depart in November to accept a position as director of women's imaging at John Peter Smith Hospital in Fort Worth, Tex.

Max Wintermark, MD, former assistant professor in residence in the Neuroradiology section, departed in October to accept a position as chief of neuroradiology at the University of Virginia, in Charlottesville, Va.

FACULTY ROSTER

Chairman

Ronald L. Arenson, MD
Alexander R. Margulis Distinguished Professor

Executive Vice-Chair

William P. Dillon, MD
Professor of Radiology
Elizabeth A. Guillaumin Chair in Neuroradiology

Vice-Chairs

David E. Avrin, MD, PhD
Professor of Clinical Radiology
Vice-Chair, Informatics

Fergus V. Coakley, MD
Professor in Residence
Vice-Chair, Clinical Affairs

Robert G. Gould, ScD
Professor in Residence
Vice-Chair, Technology and Capital Projects

Sharmila Majumdar, PhD
Professor in Residence
Vice-Chair, Research

Susan D. Wall, MD
Professor Emeritus
Vice-Chair, Academic Affairs

Mark W. Wilson, MD
Professor in Residence
Vice-Chair, San Francisco General Hospital

Judy Yee, MD
Professor in Residence
Vice-Chair, Veterans Affairs Medical Center

Abdominal Imaging

Rizwan Aslam, MD
Associate Clinical Professor

David E. Avrin, MD, PhD
Professor of Clinical Radiology

Seerat Aziz, MD
Assistant Clinical Professor

Fergus V. Coakley, MD
Professor in Residence and Chief

Bonnie N. Joe, MD, PhD
Associate Professor in Residence

Liina Poder, MD
Assistant Professor of Clinical Radiology

Aliya Qayyum, MBBS
Associate Professor in Residence
Director, Residency Program

Richard Sollitto, MD
Clinical Professor

Ruedi E.-L. Thoeni, MD
Professor in Residence

Z. Jane Wang, MD
Assistant Professor in Residence

Emily (Emma) M. Webb, MD
Assistant Professor of Clinical Radiology

Stefanie Weinstein, MD
Assistant Clinical Professor

Antonio C. Westphalen, MD
Assistant Professor in Residence

Benjamin M. Yeh, MD
Associate Professor in Residence

Ambulatory Care Center

Helen B. Galvin, MD
Clinical Professor

Steven H. Ominsky, MD
Clinical Professor Emeritus

Richard A. Sollitto, MD
Clinical Professor and Chief

Biomagnetic Imaging Laboratory

Srikantan S. Nagarajan, PhD
Professor in Residence and Director

Biostatistics/Outcomes Specialized Resources Group

Valerie Cardenas-Nicholson, PhD
Assistant Adjunct Professor

John Kornak, PhD
Assistant Professor In Residence

Rebecca Smith-Bindman, MD
Professor in Residence

Karl Young, PhD
Assistant Adjunct Professor

Brain Behavior Research Interest Group

Linda Chao, PhD
Associate Adjunct Professor

Roland G. Henry, PhD
Associate Professor in Residence

Christopher P. Hess, MD, PhD
Assistant Professor in Residence

Tracy Luks, PhD
Assistant Adjunct Professor

Pratik Mukherjee, MD, PhD
Associate Professor in Residence and Co-Director

Srikantan S. Nagarajan, PhD
Professor in Residence and Co-Director

Brain Cancer Research Interest Group

Soonmee Cha, MD
Associate Professor In Residence and Co-Director

Roland G. Henry, PhD
Associate Professor in Residence

Tracy R. McKnight, PhD
Associate Professor In Residence

Sarah J. Nelson, PhD
Professor of Radiology and Co-Director
Margaret Hart Surbeck Distinguished Professor
in Advanced Imaging

Sabrina M. Ronen, PhD
Associate Professor in Residence

Breast Cancer Research Interest Group

Belinda Chang, MD
Assistant Professor of Clinical Radiology

Chris I. Flowers, MBBS
Associate Clinical Professor

Nola M. Hylton, PhD
Professor in Residence and Co-Director

Bonnie N. Joe, MD, PhD
Associate Professor in Residence and Co-Director

John A. Shepherd, PhD
Assistant Professor in Residence

Cardiac and Pulmonary Imaging

Brett M. Elicker, MD
Assistant Professor of Clinical Radiology

Charles B. Higgins, MD
Professor of Radiology and Interim Chief

Alison Meadows, MD, PhD
Assistant Professor of Clinical Radiology and Pediatrics

Karen Ordovás, MD
Assistant Professor in Residence

Center for Imaging of Neurodegenerative Disease—VAMC

Linda L. Chao, PhD
Associate Adjunct Professor

Dieter J. Meyerhoff, PhD
Professor in Residence

Susanne G. Mueller, MD
Assistant Adjunct Professor

Norbert Schuff, PhD
Adjunct Professor

Colin Studholme, PhD
Associate Professor in Residence

Michael W. Weiner, MD
Professor in Residence and Director

Karl Young, PhD
Assistant Adjunct Professor

Center for Pharmaceutical and Molecular Imaging

Robert C. Brasch, MD
Professor in Residence and Director

Contrast Agent Research Group

Heike E. Daldrup-Link, MD, PhD
Associate Professor in Residence and Director
Michael F. Wendland, PhD
Adjunct Professor

Earl Miller Radiologic Imaging Laboratory

Michael F. Wendland, PhD
Adjunct Professor and Director

Goldberg Center for Advanced Imaging Education

Richard S. Breiman, MD
Clinical Professor and Director
Marcia J. McCowin, MD
Clinical Professor and Associate Director

Informatics and Image Processing/Display Specialized Resource Group

Ronald L. Arenson, MD
Alexander R. Margulis Distinguished Professor
David E. Avrin, MD, PhD
Professor of Clinical Radiology and Director
Jeremy Durack, MD
Assistant Professor of Clinical Radiology
Robert G. Gould, ScD
Professor in Residence
Colin Studholme, PhD
Associate Professor in Residence
Judy Yee, MD
Professor in Residence
Karl Young, PhD
Assistant Adjunct Professor

Interventional Magnetic Resonance Imaging

Charles B. Higgins, MD
Professor of Radiology
Alastair J. Martin, PhD
Associate Adjunct Professor
Maythem Saeed, PhD
Adjunct Professor

David A. Saloner, PhD
Professor in Residence and Director

Mark W. Wilson, MD
Professor in Residence

Interventional Radiology

David E. Avrin, MD, PhD
Professor of Clinical Radiology
Miles Conrad, MD
Assistant Clinical Professor
Jeremy Durack, MD
Assistant Professor of Clinical Radiology
Nicholas Fidelman, MD
Assistant Professor of Clinical Radiology
Roy L. Gordon, MD
Professor in Residence
Associate Chair, Quality Care and Patient Safety
Robert K. Kerlan, Jr., MD
Professor of Clinical Radiology and Chief
Jeanne M. LaBerge, MD
Professor in Residence
Ernest Ring, MD
Professor Emeritus
Rajiv Sawhney, MD
Clinical Professor
Mark W. Wilson, MD
Professor in Residence

Mount Zion Medical Center

Philip A. Brodey, MD
Clinical Professor
Belinda Chang, MD
Assistant Professor of Clinical Radiology
Helen B. Galvin, MD
Clinical Professor
Bonnie N. Joe, MD, PhD
Associate Professor in Residence
Robert K. Kerlan, Jr., MD
Professor of Clinical Radiology
Steven H. Ominsky, MD
Clinical Professor Emeritus
Edward A. Sickles, MD
Professor Emeritus
Richard A. Sollitto, MD
Clinical Professor and Chief
Associate Chair, Radiology, Mt. Zion Medical Center

MR/CT Contrast Agent Development Specialized Resource Group

Robert C. Brasch, MD

Professor in Residence

Heike E. Daldrup-Link, MD, PhD

Associate Professor in Residence

Michael F. Wendland, PhD

Adjunct Professor and Co-Director

Benjamin M. Yeh, MD

Associate Professor in Residence and Co-Director

MRI/MRS Specialized Resource Group

Nola M. Hylton, PhD

Professor in Residence

John Kurhanewicz, PhD

Professor In Residence

Sharmila Majumdar, PhD

Professor in Residence

Alastair J. Martin, PhD

Associate Adjunct Professor

Sarah J. Nelson, PhD

Margaret Hart Surbeck Distinguished Professor in
Advanced Imaging

Sabrina Ronen, PhD

Associate Professor in Residence

David A. Saloner, PhD

Professor in Residence

Daniel B. Vigneron, PhD

Professor in Residence and Director

Michael F. Wendland, PhD

Adjunct Professor

Duan Xu, PhD

Assistant Professor in Residence

Xiaoliang Zhang, PhD

Associate Professor in Residence

Musculoskeletal and Quantitative Imaging

Joseph C. Giaconi, MD

Assistant Clinical Professor

Thomas F. Lang, PhD

Professor in Residence

Xiaojuan Li, PhD

Assistant Adjunct Professor

Thomas M. Link, MD, PhD

Professor in Residence and Co-Director

Sharmila Majumdar, PhD

Professor in Residence and Co-Director

Musculoskeletal Imaging

Joseph C. Giaconi, MD

Assistant Clinical Professor

Thomas M. Link, MD, PhD

Professor in Residence and Chief

Lynne S. Steinbach, MD

Professor of Clinical Radiology

Neurointerventional Radiology

Christopher F. Dowd, MD

Clinical Professor

Van V. Halbach, MD

Clinical Professor

Steven W. Hetts, MD

Assistant Professor in Residence

Randall T. Higashida, MD

Clinical Professor and Chief

Neurodegenerative Diseases Research Interest Group

Valerie Cardenas-Nicholson, PhD

Associate Adjunct Professor

Linda Chao, PhD

Associate Adjunct Professor

Timothy Durazzo, PhD

Assistant Adjunct Professor

Christopher P. Hess, MD, PhD

Assistant Professor in Residence

Dieter J. Meyerhoff, PhD

Professor in Residence

Susanne G. Mueller, MD

Assistant Adjunct Professor

Norbert Schuff, PhD

Adjunct Professor and Co-Director

Michael W. Weiner, MD

Professor in Residence and Co-Director

Karl Young, PhD

Assistant Adjunct Professor

Wang Zhan, PhD

Assistant Adjunct Professor

Neuroradiology

A. James Barkovich, MD

Professor In Residence

Soonmee Cha, MD

Associate Professor In Residence

Cynthia T. Chin, MD

Associate Professor of Clinical Radiology

William P. Dillon, MD
Professor and Chief

Alisa D. Gean, MD
Clinical Professor

Christine Glastonbury, MD
Associate Professor of Clinical Radiology

Orit A. Glenn, MD
Associate Professor in Residence

Christopher P. Hess, MD, PhD
Assistant Professor in Residence

Jane Kim, MD
Assistant Professor of Clinical Radiology

Pratik Mukherjee, MD, PhD
Associate Professor in Residence

David Norman, MD
Clinical Professor Emeritus

Esther L. Yuh, MD, PhD
Assistant Professor in Residence

Neurovascular/Neurointerventional Research Interest Group

William P. Dillon, MD
Professor

Christopher F. Dowd, MD
Clinical Professor

Van V. Halbach, MD
Clinical Professor

Steven W. Hetts, MD
Assistant Professor in Residence

Randall T. Higashida, MD
Clinical Professor

Alastair J. Martin, PhD
Associate Adjunct Professor

David A. Saloner, PhD
Professor in Residence and Co-Director

Nuclear Medicine

Elias H. Botvinick, MD
Professor in Residence

Michael W. Dae, MD
Professor in Residence

Randall A. Hawkins, MD, PhD
Professor and Chief

Carina Mari Aparici, MD
Assistant Professor in Residence

Eugene T. Morita, MD
Clinical Professor Emeritus

Miguel Hernandez Pampaloni, MD, PhD
Assistant Professor in Residence

Nuclear-Optical Specialized Resource Group

Stephen Bacharach, PhD
Adjunct Professor

Elias H. Botvinick, MD
Professor in Residence

Michael W. Dae, MD
Professor in Residence

Robert G. Gould, ScD
Professor in Residence

Randall A. Hawkins, MD, PhD
Professor

Jiang He, PhD
Assistant Adjunct Professor

Ella Fung Jones, PhD
Assistant Adjunct Professor

Carina Mari Aparici, MD
Assistant Professor in Residence

Miguel Hernandez Pampaloni, MD, PhD
Assistant Professor in Residence

Henry F. VanBrocklin, PhD
Professor in Residence and Director

Youngho Seo, PhD
Assistant Adjunct Professor

Pediatric Radiology

Robert C. Brasch, MD
Professor In Residence

Pierre-Alain Cohen, MD
Clinical Professor

Heike E. Daldrup-Link, MD, PhD
Associate Professor in Residence and Interim Chief

Pediatric/Fetal Research Interest Group

A. James Barkovich, MD
Professor in Residence and Director

Heike E. Daldrup-Link, MD, PhD
Associate Professor in Residence

Vickie A. Feldstein, MD
Professor of Clinical Radiology

Orit A. Glenn, MD
Associate Professor in Residence

Ruth B. Goldstein, MD
Professor and Chief

Roland G. Henry, PhD
Associate Professor in Residence

Pratik Mukherjee, MD, PhD
Associate Professor in Residence

Colin Studholme, PhD
Associate Professor in Residence

Daniel B. Vigneron, PhD
Professor in Residence

Duan Xu, PhD
Assistant Professor in Residence

Prostate Cancer Research Interest Group

Fergus V. Coakley, MD
Professor in Residence and Co-Director

John Kurhanewicz, PhD
Professor In Residence and Co-Director

Susan Noworolski, PhD
Assistant Adjunct Professor

Aliya Qayyum, MBBS
Associate Professor in Residence

Sabrina Ronen, PhD
Associate Professor in Residence

Daniel B. Vigneron, PhD
Professor in Residence

Antonio C. Westphalen, MD
Assistant Professor in Residence

San Francisco General Hospital

Richard S. Breiman, MD
Clinical Professor

Miles Conrad, MD
Assistant Clinical Professor

Pierre-Alain Cohen, MD
Clinical Professor

Alisa D. Gean, MD
Clinical Professor

Steven W. Hetts, MD
Assistant Professor in Residence

Jane Kim, MD
Assistant Professor of Clinical Radiology

Terry C.P. Lynch, MD
Clinical Professor

Hideyo Minagi, MD
Clinical Professor Emeritus

Sujal M. Nanavati, MD
Assistant Clinical Professor

Ernest Ring, MD
Professor Emeritus

Alexander V. Rybkin, MD
Assistant Clinical Professor

Mathem Saeed, PhD
Adjunct Professor

Lori M. Strachowski, MD
Associate Clinical Professor

Ruedi E.-L. Thoeni, MD
Professor in Residence

John Van Uden, MD, PhD
Assistant Clinical Professor

Thienkhai Vu, MD, PhD
Assistant Clinical Professor

W. Richard Webb, MD
Professor Emeritus

Mark W. Wilson, MD
Professor in Residence and Chief

Esther L. Yuh, MD, PhD
Assistant Professor in Residence

Surbeck Laboratory for Advanced Imaging

Robert Bok, MD, PhD
Assistant Adjunct Professor

Christopher P. Hess, MD, PhD
Assistant Professor in Residence

Douglas Kelley, PhD
Associate Adjunct Professor

John Kurhanewicz, PhD
Professor in Residence

Sharmila Majumdar, PhD
Professor in Residence

Sarah J. Nelson, PhD
Margaret Hart Surbeck Distinguished Professor in
Advanced Imaging and Director

Sabrina M. Ronen, PhD
Associate Professor in Residence

Daniel B. Vigneron, PhD
Professor in Residence

Duan Xu, PhD
Assistant Professor in Residence

Xiaoliang Zhang, PhD
Associate Professor in Residence

Ultrasound

Seerat Aziz, MD
Assistant Clinical Professor

Peter W. Callen, MD
Professor in Residence

Vickie A. Feldstein, MD
Professor of Clinical Radiology

Roy A. Filly, MD
Professor Emeritus

Ruth B. Goldstein, MD
Professor and Chief

Liina Poder, MD
Assistant Professor of Clinical Radiology

Rebecca Smith-Bindman, MD
Professor in Residence

Lori M. Strachowski, MD
Associate Clinical Professor

Vascular Imaging Research Center—VAMC

David A. Saloner, PhD
Professor in Residence and Director

Veterans Affairs Medical Center

Rizwan Aslam, MD
Associate Clinical Professor and Chief of CT

Linda L. Chao, PhD
Associate Adjunct Professor

Timothy Durazzo, PhD
Assistant Adjunct Professor

Christine M. Glastonbury, MBBS
Associate Professor and Chief of Neuroradiology

Virginia J. Griswold, MD
Associate Clinical Professor

Carina Mari Aparici, MD
Assistant Professor in Residence

Marcia J. McCowin, MD
Clinical Professor

Dieter J. Meyerhoff, PhD
Professor in Residence

Susanne Mueller, MD
Assistant Adjunct Professor

Alexander P. Nguyen, MD
Assistant Clinical Professor

David A. Saloner, PhD
Professor in Residence

Rajiv Sawhney, MD
Clinical Professor

Norbert Schuff, PhD
Adjunct Professor

Colin Studholme, PhD
Associate Professor in Residence

Michael W. Weiner, MD
Professor in Residence

Stefanie Weinstein, MD
Assistant Clinical Professor

Judy Yee, MD
Professor in Residence and Chief

Benjamin M. Yeh, MD
Associate Professor in Residence and Assistant Chief

Karl Young, PhD
Assistant Adjunct Professor

Wang Zhan, PhD
Assistant Adjunct Professor

Women's Imaging at Mt. Zion

Belinda Chang, MD
Assistant Professor of Clinical Radiology

Bonnie N. Joe, MD, PhD
Associate Professor in Residence and Chief

Chris I. Flowers, MBBS
Associate Clinical Professor

Edward A. Sickles, MD
Professor Emeritus

Helen B. Galvin, MD
Clinical Professor

HONORS AND AWARDS

Rizwan Aslam, MD
Promoted to Associate Clinical Professor

Richard S. Breiman, MD
Elected secretary of the Alliance of Medical Student Educators in Radiology

Christopher F. Dowd, MD
President, Western Neuroradiological Society, 2009-10

Heike E. Daldrop-Link, MD, PhD
Senior author on a publication that received the Berdon Award from the Society for Pediatric Radiology, recognizing the best basic science paper published in *Pediatric Radiology* in 2008
Elected to Board of Directors, Society of Pediatric Radiology Research and Education Foundation
Member, Society for Pediatric Radiology Publication Committee

Brett M. Elicker, MD

Recipient, Hideyo Minagi Outstanding Teacher Award, 2009

Christine Glastonbury, MBBS

Recipient, Excellence in Teaching Award, the Haile T. Debas Academy of Medical Educators, UCSF

Charles A. Gooding, MD

Awarded the Society of Pediatric Radiology Gold Medal, 2009

Bonnie N. Joe, MD, PhD

Promoted to Associate Professor in Residence

Robert K. Kerlan, Jr., MD

Journal of Vascular and Interventional Radiology
Distinguished Reviewer Award, 2008
Dotter Lecturer, Western Angiographic and Interventional Society, September 2009



Jeanne M. LaBerge, MD

Jeanne M. LaBerge, MD

Elected as trustee to the American Board of Radiology

Thomas F. Lang, PhD

Selected as a member of the Skeletal Biology Structure and Regeneration Study Section, Center for Scientific Review, National Institutes of Health

Thomas M. Link, MD, PhD

The 2009 Founder's Lecturer of the International Skeletal Society, Washington, D.C.
Radiology Editor's Recognition Award with Distinction
Appointed to the Editorial Board, *European Radiology*
Top Cited Award 2006-2008, *Osteoarthritis and Cartilage* (co-author of one of the Top 10 cited papers)

Carina Mari Aparici, MD

Recipient, Excellence in Teaching Award, the Haile T. Debas Academy of Medical Educators, UCSF

Pratik Mukherjee, MD, PhD

Recipient, GE Healthcare's MR Thought Leader Award at the 17th Annual Meeting of the International Society for Magnetic Resonance in Medicine

Sujal Nanavati, MD

Recipient, Excellence in Teaching Award, the Haile T. Debas Academy of Medical Educators, UCSF

Rebecca Smith-Bindman, MD

Promoted to Professor In Residence

Lynne S. Steinbach, MD

Radiology Editor's Recognition Award with Distinction
Appointed Deputy Editor, *Journal of Magnetic Resonance Imaging*

Lori M. Strachowski, MD

Recipient, Excellence in Teaching Award, the Haile T. Debas Academy of Medical Educators, UCSF

Daniel B. Vigneron, PhD

2009 International Society of Magnetic Resonance Fellowship Award

Emily (Emma) M. Webb, MD

Recipient, Excellence in Teaching Award, the Haile T. Debas Academy of Medical Educators, UCSF

Mark W. Wilson, MD


Promoted to Professor In Residence

Benjamin M. Yeh, MD

Co-recipient, Hounsfield Award, Society of Computed Body Tomography/Magnetic Resonance, 2009

Esther L. Yuh, MD, PhD

Recipient, Outstanding Fellow/Clinical Instructor Teaching Award, 2009



Chairman Ronald L. Arenson, MD presents the Outstanding Fellow/Clinical Instructor Teaching Award to Esther L. Yuh, MD, PhD

THE MARGULIS SOCIETY

“As the new president of the Margulis Society, I look forward to leading the Society in its mission to provide current and future generations of UCSF radiology trainees the support and opportunities they need to become superior radiologists and to expanding our network of active members to promote career opportunities and advancement among alumni,” said Christopher J. Schultz, MD, a 2000 graduate of UCSF’s radiology residency. “This year our focus is on increasing Society membership and contributions, while strengthening the bond among UCSF graduates, faculty, and trainees. I welcome your counsel and support in achieving these goals.”



Christopher J. Schultz, MD

Schultz’s two-year term follows that of Dr. Donna Hoghooghi who served as president from July 2007 to June 2009. After receiving his MD in 1995 from the University of Kansas, Kansas City, Kansas, Schultz completed a four-year radiology residency at UCSF, followed by a one-year fellowship in Magnetic Resonance Imaging and Ultrasound at the Mayo Clinic in Scottsdale, Ariz. Schultz works as a radiologist at Queen of the Valley Medical Center in Napa, Calif.

Schultz’s two-year term follows that of Dr. Donna Hoghooghi who served as president from July 2007 to June 2009. After receiving his MD in 1995 from the University of Kansas, Kansas City, Kansas, Schultz completed a four-year radiology residency at UCSF, followed by a one-year fellowship in Magnetic Resonance Imaging and Ultrasound at the Mayo Clinic in Scottsdale, Ariz. Schultz works as a radiologist at Queen of the Valley Medical Center in Napa, Calif.

Support for Resident Research

Each year, the Margulis Society selects a radiology resident who has accomplished noteworthy research to receive the Margulis Society Research Award. David M. Wilson, MD, PhD received the 2009 award at commencement in June.

During his residency, Wilson completed outstanding research in probe development utilizing hyperpolarized carbon 13. He was one of four residents to receive a T32 training grant in 2007-08 from the National Institute of Biomedical Imaging and Bioengineering. T32 grants are designed to give radiologists-in-training the skills required to become independent clinical scientific investigators and leaders in academic biomedical imaging. A 2009 graduate of the residency program, Wilson began a clinical fellowship in Neuroradiology in the Department of Radiology and

Biomedical Imaging in July 2009.

In addition, Timothy Shepherd, MD, PhD (PGY4) received the 2009 Margulis Society research grant for his project entitled “Diffusion Anisotropy Changes in the Human Hippocampus as an Improved MRI Surrogate Marker of Alzheimer’s Disease.”



The Margulis Society Outstanding Resident Research Award is presented: (l-r) Ronald L. Arenson, MD, David M. Wilson, MD, PhD (recipient), Donna Hoghooghi, MD

Career Conference 2009

The Margulis Society hosted its tenth annual career conference in July 2009 at the home of board member Dr. Donna Hoghooghi. Panelists included Jeffrey Dieden, MD, Donna Hoghooghi, MD, and Camilla E. Lindan, MD, from private practice and UCSF faculty members Aliya Qayyum, MBBS, and David E. Avrin, MD, PhD. Dr. Erik Gaensler directed the conference, which provided information about the career needs of residents and fellows. A question-and-answer session following the panelists’ presentation gave attendees the opportunity to learn about private practice and academic career options, as well as insights into the current radiology job market.

AFIP support

Thanks to underwriting from the Margulis Society, 11 diagnostic radiology residents attended the 6-week Armed Forces Institute of Pathology (AFIP) training course in Washington, DC during the 2008-09 academic year.

Residents who have attended the course over the years have been uniformly enthusiastic. One 2009

attendee, David Naeger, MD (PGY5) called AFIP, “an intense eight-hour-per-day, solid month of Radiology/Pathology correlation.” Naeger described the lectures as “top notch, covering even minute (but important!) topics in Radiology.

“AFIP reinforces and adds to the lectures we receive at UCSF and is an irreplaceable experience. We are immensely grateful to the Margulis Society and the Department for their support of our attendance here,” Naeger concluded.

Thank You to Our Alumni

In this time of economic downturn, the Margulis Society greatly appreciates the energy and involvement of alumni in support of radiology residency and fellow training at UCSF in a variety of ways.

“Many alumni contributed by teaching, whether by giving a single resident lecture or a series of board review case conferences. The material presented by our alumni is always a huge asset to our residency teaching program and we are extremely grateful,” said Dr. Aliya Qayyum, Margulis Society Board Member and Residency Program Director. “And the alumni seem to get as much out of it as the students.” Alumni who contributed by teaching residents include Drs. Miriam Bredella, Erik H.L. Gaensler, Christopher K. Hoffman, Joseph Hoxworth, Jessica Leung, Camilla Lindan, Howard Nelson, Gregory Sabo, and many others.

“We also extend our heartfelt gratitude to the many donors who fund the Margulis Society year after year,” said Schultz. “Your financial support is the base of our efforts. We are particularly pleased at the number of newly graduated residents and fellows who contributed to the Society. Their donations represent the future and will enable the programs that the Margulis Society funds to continue.”



The Margulis Society Career Evening 2009: Speakers included (l-r): Erik H.L. Gaensler, MD, David E. Avrin, MD, PhD, Aliya Qayyum, MBBS, Donna Hoghooghi, MD, Jeffrey D. Dieden, MD, and Ronald L. Arenson, MD

The Margulis Society Board of Directors

Christopher J. Schultz, MD, President

Diego E. Ruiz, MD, President-Elect

**Donna Hoghooghi, MD, Immediate
Past-President**

Ronald L. Arenson, MD

Jeffrey D. Dieden, MD

Erik H.L. Gaensler, MD

Christine M. Glastonbury, MBBS

Christopher K. Hoffman, MD

Camilla E. Lindan, MD

Vincent D. McCormick, MD

Peter S. Moskowitz, MD

Aliya Qayyum, MBBS

Gautham P. Reddy, MD, MPH

Volney F. Van Dalsem, III, MD

Mark W. Wilson, MD

Benjamin M. Yeh, MD

**Remember to set aside
the evening of**

Wednesday, March 17, 2010

for the first

Margulis Society Alumnus Lecture.

President of the Salk Institute,

William R. Brody, MD, PhD,

**(Diagnostic Radiology Residency
graduate, 1977),**

will be the featured speaker.

The lecture will be held at UCSF.

THE MARGULIS SOCIETY DONORS LIST

The Margulis Society gratefully acknowledges the following individuals for their generous contributions. This list reflects gifts made between July 1, 2008 and June 30, 2009.

Avanti Ambekar, MD
 Ronald L. Arenson, MD*
 David E. Avrin, MD, PhD
 John J. Baehr III, MD
 Gary H. Baker, MD*
 Irene Balcar, MD
 A. James Barkovich, MD
 Robert M. Barr, MD
 Susan Barrows, MD
 Miriam A. Bredella, MD
 Ben Maurice Brown, MD
 Thomas J. Bryce, MD
 Vincent D. Burke, MD
 Elizabeth S. Burnside, MD
 Marianna Caponigro, MD
 Michael A. Carducci, MD
 Margaret H. Chaffey, MD
 Krammie M. Chan, MD
 Frank S.H. Chang, MD
 Mark Z.K. Chen, MD
 Daryl M. Chen, MD
 James S. Chen, MD, PhD
 Chloe Chhor, MD
 Daryl H. Chinn, MD
 Iris B.S. Choo, MD
 Nathaniel A.H. Chuang, MD*
 Granville C. Coggs, MD, FACR
 Cirrelda Cooper, MD
 Geoffrey I. Criqui, MD
 Lawrence E. Crooks PhD*
 Roland D. DeMarco, MD
 Wm. James DeMartini, MD
 Jeffrey D. Dieden, MD
 William P. Dillon, MD
 Christopher F. Dowd, MD
 Terril A. Efird, MD
 Nazih Farah, MD
 Thomas H. Farquhar, MD
 Vickie A. Feldstein, MD
 Charles E. Fiske, MD
 Malcolm B. Friedman, MD
 Russell C. Fritz, MD
 Erik H.L. Gaensler, MD*
 Helen B. Galvin, MD

Christine Glastonbury, MBBS
 John S. Gletne, MD
 Ruth B. Goldstein, MD
 James L. Gorder, MD
 Roy L. Gordon, MD
 Michael B. Gotway, MD*
 Chris G. Goumas, MD
 Virginia J. Griswold, MD
 Elizabeth A. Guillaumin, MD*
 Lawrence P. Harter, MD
 Randall A. Hawkins, MD, PhD
 Christopher P. Hess, MD, PhD
 Steven W. Hetts, MD
 Daniel R. Hightower, MD
 Christopher K. Hoffman, MD*
 Donna Hoghooghi, MD
 Julian B. Holt, MD
 Joseph M. Hoxworth, MD
 Hedvig Hricak, MD, PhD
 Pamela S. Jensen, MD
 Bonnie N. Joe, MD, PhD
 James O. Johnston, MD
 Peter J. Julien, MD
 Carl Kalbhen, MD
 Leon G. Kaseff, MD
 Donald R. Kirks, MD
 Herbert Y. Kressel, MD
 Annie P.W. Lai, MD
 Faye C. Laing, MD
 Theodore C. Larson III, MD
 Edward A. Lebowitz, MD
 F. Chaney Li, MD
 Camilla Lindan, MD
 Jay C. Mall, MD
 Vincent D. McCormick, MD
 Marcia J. McCowin, MD
 Edward M. Miller, MD
 Hideyo Minagi, MD*
 James M. Moorefield, MD
 Peter S. Moskowitz, MD
 James A. Nelson, MD
 John D. Noonan, MD
 Steven H. Ominsky, MD
 Karen Ordovas, MD

Kent D. Pearson, MD
 Kathryn L. Pearson Peyton, MD
 Donald J. Ponec, MD
 Mark J. Popovich, MD
 Derk D. Purcell, MD
 Aliya Qayyum, MBBS
 Stanley B. Reich, MD
 Ernest J. Ring, MD
 Gregory Rogalski, MD
 Diego E. Ruiz, MD
 Gregory Sabo, MD*
 Charles Savoca, MD
 John D. Schrumpf, MD
 Christopher J. Schultz, MD
 Clark L. Searle, MD
 Robert Seveck, MD
 Gary T. Shaw, MD
 Edward A. Sickles, MD*
 Richard A. Solitto, MD
 D. Christian Sonne, MD
 Lynne S. Steinbach, MD
 Susan K. Stevens, MD
 Robert C. Taylor, DDS
 Ronald R. Townsend, MD
 Volney F. Van Dalsem, MD
 John Van Uden, MD, PhD
 Susan D. Wall, MD
 Z. Jane Wang, MD
 Nikunj P. Wasudev, MD
 Antonio Westphalen, MD
 Michael Williams, MD
 Mark W. Wilson, MD
 Benjamin M. Yeh, MD
 Kyle K. Yu, MD
 Gregory G. Zaharchuk, MD
 * **Donation of \$1,000 or more**

RETIRED IN 2009

Charles A. Gooding, MD


His retirement in June 2009 capped a stellar career in pediatric radiology for Charles A. Gooding, MD, including 40 years as chief of the UCSF Pediatric Radiology Section. Gooding received his MD from Ohio State University School of Medicine, completed his Radiology residency at Harvard's Brigham and Women's Hospital and fellowship training in Europe. During his service in the US Army Medical Corps, Gooding was acting chief of Radiology at Letterman General Hospital. He joined UCSF in 1967, serving as chief of Pediatric Radiology from 1968 to 2008. From 1979 to 1998, he was executive vice-chairman of Radiology at UCSF.

"I will remember Charles as an advisor, mentor, colleague, and friend," said Heike Daldrop-Link, MD, PhD. "He set high standards of moral probity for all who worked with him and fought relentlessly for the causes and the people he believed in. He will always be a source of energy and inspiration for us."

Gooding served the profession as president and chairman of the board of the Society for Pediatric Radiology. He also was editor of *Pediatric Radiology* for more than 20 years and he has authored or co-authored more than 200 publications.

Dr. Gooding was instrumental in advancing the care of children globally. He was the founder and president of the Radiology Outreach Foundation, which distributes equipment and educational material to developing countries. His international impact garnered him numerous awards and honors from radiological societies across the globe. In 1993, he received the UCSF Chancellor's Award for Public Service. Most recently, he received the Gold Medal of the Society of Pediatric Radiology for his contributions to pediatric radiology.

Gooding and his wife, Gretchen Gooding, MD, (see accompanying article) have three children: Gunnar, an attorney, Justin a radiologist, and Britta, a radiologist, and three grandchildren. Dr. Gooding's athletic pursuits are legendary: he has competed in the Ironman Triathlon World Championship in Hawaii, the United States Triathlon Series, and Escape from Alcatraz Triathlon, among others. He has been a member of the Board of Directors of the Marin Rowing Association and holds numerous medals in national and international rowing championships.




Charles A. Gooding, MD

Gretchen A.W. Gooding, MD

Gretchen A.W. Gooding, MD, professor of Radiology and Biomedical Imaging, has retired after more than 37 years in Radiology at the Veterans Affairs Medical Center and UCSF.

A graduate of the Ohio State University College of Medicine, Gooding completed her residency at UCSF. She joined the faculty in 1975, achieving the rank of professor in 1986. From 1987-2003, Gooding served as vice-chair of the department and chief of radiology at the San Francisco VAMC.



Gretchen A.W. Gooding, MD

"When Dr. Gooding chose radiology as her specialty, she may not have realized that she would become a role model and mentor for the increasing number of women who have joined the field in more recent years," said Chairman Ron Arenson, MD. "We are fortunate to have benefited from her tremendous leadership, years of service, and inspiration."

Gooding was a recognized expert in all aspects of ultrasound, with major academic contributions in vascular ultrasound, intraoperative ultrasound, and abdominal imaging. She served as president of the Bay Area Ultrasound Society, the San Francisco Radiologic Society, and the American Association of Women in Radiology. Gooding also holds honorary memberships in numerous international radiological societies, including those in Pakistan, Hungary, and Cuba.

In 2003, the American Association for Women Radiologists honored her with the Alice Ettinger Distinguished Achievement Award in recognition of her outstanding, long-term contributions to radiology as a leader, mentor, and teacher. She served as a career advisor for the School of Medicine, and recently chaired the VAMC Radiology Quality Management Program.

An active researcher, Gooding published extensively, with more than 170 peer-reviewed papers to her credit. Radiologists and students around the world benefited from her lectures, refresher courses, and scientific presentations on ultrasound and abdominal imaging. She authored many Practice Guidelines in Ultrasound for the American College of Radiology and served on the editorial advisory boards of numerous journals.

"In addition to her many other contributions, Gretchen has been an active and well-respected teacher and mentor for our residents, fellows, and medical students," said Judy Yee, MD, chief of radiology at the VAMC. "Her warmth, approachability and mentorship touched so many of our trainees."

W. Richard Webb, MD

W. Richard Webb, MD, professor of radiology and the Hideyo Minagi professor at San Francisco General Hospital retired after more than 37 years in the Department of Radiology and Biomedical Imaging.

Webb had an illustrious career in chest radiology and enormous success as a clinician, teacher, researcher,



W. Richard Webb, MD

and mentor. He came to UCSF as a resident in 1972 and served as chief resident in 1975-76. He joined the faculty as an assistant professor in 1977, becoming a professor in 1987. Webb was chief of the Cardio-Thoracic Imaging Section from 1995 to 2006, and in 2006 was named the Hideyo Minagi Professor of Radiology.

Students, residents, and fellows regularly found Webb to be knowledgeable, approachable, and efficient in highlighting key concepts and interesting teaching points. He also is a popular lecturer in many CME programs around the world, and has chaired many courses, most recently a new body imaging course held in Washington, D.C.

Dr. Webb's textbook, *High Resolution CT of the Lung*, now in its third edition, is considered the definitive textbook on the subject. During his career, Webb authored many other books, manuscripts, and chapters, and conducted well-regarded clinical research in a variety of areas, including high-resolution computed tomography (CT) in the diagnosis of AIDS-related disease, complications of lung transplantation, and the CT diagnosis of chest trauma. In 2004, he received the Fleischner Medal and gave the Fleischner Lecture to the Fleischner Society for Thoracic Imaging and Diagnosis, a recognition of his contributions to the field of chest radiology.

"Given his strong clinical, research, and particularly his teaching accomplishments, I am very pleased that Dr. Webb has agreed to remain involved with the clinical work of the section he helped to build," said Ron Arenson, MD, department chairman. "Rick Webb leaves a strong legacy of accomplishment in radiology at UCSF and beyond, and a large and devoted following of former trainees who are proud of their affiliation with him and with the Chest section."

Robert C. Taylor, DDS, MDS

Robert C. Taylor, DDS, MDS, professor emeritus of radiology, retired in June 2009 after many years of service to the Department of Radiology and Biomedical Imaging and the UCSF School of Dentistry.

"I want to thank Bob for his many years of dedicated service to UCSF and Radiology," said Ron Arenson, MD, chairman, Department of Radiology and Biomedical Imaging.

Taylor obtained his dental degree from St. Louis University in Missouri in 1957. He came to UCSF as an oral and maxillofacial surgery resident and joined the School of Dentistry faculty in 1960. As a practicing oral surgeon, Taylor and William Ware, DDS, MDS (later to become the chairman of



Robert C. Taylor, DDS, MDS

the Division of Oral and Maxillofacial Surgery) set up the Temporomandibular Joint Clinic at UCSF. Through the clinic, Taylor developed an interest in imaging. He developed cephalometric tomography for the temporomandibular joint and was among the first to obtain a magnetic resonance image (MRI) of that joint.

His collaboration with Earl Miller, MD on studies of temporomandibular joint function marked the start of Taylor's involvement with the Department of Radiology and Biomedical Imaging. He formally joined the faculty in 1986, while retaining a secondary, unpaid appointment to the Department of Oral and Maxillofacial Surgery. "Bob Taylor was a dentist first and an imaging aficionado second," said M. Anthony Pogrel, DDS, MD, professor and chair, Department of Oral and Maxillofacial Surgery.

Over the years, Taylor developed a talent for putting together research projects and raising funds for them among his network of technology industry leaders. The list of projects he supported include the creation of the Magnetic Resonance Science Center in 1986, the development of Lazer Pantography and 3D processing, and the development of an MRI-guided catheter prototype with the Lawrence Livermore National Laboratory.

Over the last 20 years, Taylor has championed the use of thermography in diagnosing temporomandibular joint problems and the use of magnetic resonance imaging for nerve injuries in dentistry.

Denice Nakano

Denice Nakano, site administrator at the Parnassus Campus, has retired after more than 33 years of committed service to the Department of Radiology and Biomedical Imaging. Nakano's long association with the department started in 1968 as a part-time transcriptionist at San Francisco General Hospital Radiology.


In 1976, she became one of the transcriptionists employed by UCSF Radiology. Using what was then state-of-the-art technology, she transcribed from Dictaphones and then magnetic tapes, making "about six carbon copies of each report, because they went to so many different people," Nakano recalled.

In 1984 Nakano became an administrative assistant at the Parnassus campus, working in the Division of Musculoskeletal Radiology for then-chief Dr. Harry Genant. In 1995, as an administrative analyst she managed research grants, coordinated fellows and trainees, and helped manage clinical trials.

In 2000, Nakano took on a new role as a management services officer at the Parnassus site. In this capacity, Nakano provided administrative oversight for the entire Parnassus operation, including renovations, inventory control, contracts and grants, and administrative management. Throughout her career, Nakano has consistently received praise for her skills, along with numerous performance awards.

"Radiology is very fortunate to have benefited from Denice's skill and dedication for more than 30 years," said Cathy Garzio, administrative director. "She has been a role model for many employees in Radiology, and she had great rapport with department faculty and residents over the years. We will miss, not just her knowledge and work ethic, but also her great attitude and can-do approach to everything she does."

According to Nakano, "there was never a dull moment in the Radiology Department. There were always opportunities for problem-solving. I liked the changes and challenges to make things better administratively. I enjoyed being around motivated people with ambition and drive." Nakano continued, "I am very thankful and proud to have worked for the Department of Radiology. I made so many wonderful friends here and all over the world."



Denice Nakano

Nakano looks forward to spending time with her husband Steven, and sons Grant and Brad, as well as her extended family in the Bay Area.




Nakano celebrates her retirement: (l-r) Richard Sollitto, MD, Denice Nakano, and David Avrin, MD, PhD.

ALUMNI NEWS

1958

Granville Coggs, MD, was profiled in *The Wonder Years: Portraits of Athletes Who Never Slow Down*, by Rick Rickman and Donna Wares (Chronicle Books 2009), a book showcasing senior athletes in words and photographs.



Granville Coggs (right) at the 2008 San Antonio Senior Games track meet with wife Maud Currie Coggs (center) and running coach Michael Davis (left).

1971

Jesse L. Kahn, MD, of Carmel, Calif., and his wife Carol, recommend Glacier National Park as a great place to visit, based on their recent vacation there.



Jesse and Carol Kahn in Glacier National Park.

Kahn continues to work occasionally for the Monterey Peninsula Radiology Group. His new grandson, Mason Lucas, born in August 2009, lives nearby in Pacific Grove. Kahn and his wife Carol will volunteer at the U.S. Open in June 2010, and also volunteer at the AT&T and 1st Tee golf tournaments. He sends his regards to all.

1973

James Branscom, MD, of Alamo, Calif., is semi-retired and works part time for Bay Imaging Consultants and the Martinez VAMC. He and his wife Louise, married for 42 years, have a grandson, Miles, born in 2007. He shares memories: "After leaving UCSF's residency in 1973, I ended up in a start-up practice with a small hospital and clinic in Vallejo, with offices in near Walnut Creek and in Concord. Eventually, the practice opened an imaging center in San Ramon. Later, we merged, first with what was called Diablo Valley Radiology, later Bay Imaging Consultants. The whole trip has in general been a good and rewarding one, with a few bumps. Thanks to those who motivated me, Alex, Dr. Greenspan, and others. Wouldn't really

have chosen any other line of work..." He may be reached by email at: err88@sbcglobal.net.

1977

William R. Brody, MD, PhD, of La Jolla, Calif., became president of the Salk Institute for Biological Studies in La Jolla in March 2009. He oversees a staff of 870 scientific personnel, including several Nobel laureates and members of the National Academy of Sciences. Early in 2009, Brody retired as president of The Johns Hopkins University, a position he had held since 1996. He was named to the National Institutes of Health Scientific Management Review Board (SMRB) in 2008.

1979

Michael P. Federle, MD, of Palo Alto, Calif., writes that the second edition of his textbook, *Diagnostic Imaging: Abdomen*, will be published in time for this year's RSNA. "The publisher is Amirsys, a company that I helped to found. It has become the leading publisher of radiology books and decision-support tools such as STATdx. This online program is used in 80% of all residency training programs and in many radiology private practices," he writes.

1980

Richard A. Barth, MD, of Palo Alto, Calif., radiologist-in-chief at Lucile Packard Children's Hospital at Stanford and professor and associate chair of Radiology at Stanford University School of Medicine, was awarded the 2009 outstanding alumni award by the UCSF Department of Radiology and Biomedical Imaging, at the annual commencement ceremony.



Richard A. Barth receives outstanding alumni award from Ron Arenson and Susan D. Wall.

R. James Brenner, MD, JD, FACR, FCLM, of San Francisco, Calif., joined Bay Imaging Consultants in 2008, where he serves as the director of Breast Imaging. He remains a professor of Clinical Radiology at UCSF.



Melinda and Jeffrey Dieden, Ravello, Italy

1986

Jeffrey D. Dieden, MD, of Lafayette, Calif., vacationed in Ravello, on the Amalfi Coast of Italy with his wife Melinda.

1989


Debra L. Monticciolo, MD, FACR, of Temple, Tex., was elected vice-president of the Society of Breast Imaging in 2009. She serves as chair, Mammography Accreditation, for the American College of Radiology. She is vice-chair for research and section chief for the Department of Radiology at Texas A&M College of Medicine.

1996

Gautham Reddy, MD, MPH, of Seattle, Wash., is the new deputy editor of *The Journal of Thoracic Imaging*. Reddy is a professor of radiology and vice-chair for education in the Department of Radiology at the University of Washington School of Medicine and director of thoracic imaging at the University of Washington Medical Center, Harborview Medical Center, and the Seattle Cancer Care Alliance.

1999

Allen B. Nalbandian, MD, of San Diego, Calif., was nominated president of his group, Valley Radiology Consultants. He also will serve as president of the San Diego Radiology Society in 2010. He has launched a niche teleradiology company, Women's Imaging Specialists of America, dedicated to women's imaging. He writes that "between career and family I manage to squeeze in just enough time to get a few surf sessions."



Wendy and Allen Nalbandian with sons Dylan (9) and Ross (7)


2003

Donna Hoghooghi, MD, of San Francisco, Calif., is president-elect of the UCSF Medical School Alumni Association. She will serve as president in 2010-2011. She and husband Ted Bartlett have a five-year-old daughter, Jasmine, and a two-year-old daughter, Millie.



Millie and Jasmine Bartlett

Gerald K. Lee, MD, of San Mateo, Calif., was awarded the 2009 Outstanding Clinical Faculty award at commencement by the UCSF Department of Radiology and Biomedical Imaging. Since graduating from the UCSF Abdominal Imaging fellowship in 2003, Lee has served as a clinical faculty in Abdominal Imaging, returning several times each year to teach residents and share his experiences. He works in the newly formed Veterans Affairs Teleradiology Group in Menlo Park.



Ron Arenson presents outstanding clinical faculty award for teaching excellence to Gerald K. Lee.

Bachir Taouli, MD, of New York, NY, writes that after six years at New York University, he has accepted a position as director of body MRI and associate professor of radiology and medicine at Mount Sinai School of Medicine in New York City. He has two boys, Zachary and Elias.

2004

Diego E. Ruiz, MD, of San Francisco is president-elect of The Margulis Society. He will serve as president in 2011-2013.

IN MEMORIAM

Gordon Gamsu, MD

Dr. Gordon Gamsu, a world-renowned thoracic radiologist, colleague, mentor, and friend, died January 13, 2009, in New York City, at the age of 69 years, after an extended illness.

Dr. Gamsu was born in Johannesburg, South Africa in 1940 and received his medical training at the University of the Witwatersrand in Johannesburg. He trained in diagnostic radiology at Beth Israel Hospital in Boston, Mass., and the Albert Einstein College of Medicine in the Bronx, N.Y. He was a research fellow in thoracic radiology at the Royal Victoria Hospital in Montreal, Quebec, Canada, and the Cardiovascular Research Institute of the UCSF, Medical Center. In 1972, he joined the UCSF faculty. From 1973 to 1995, he directed the Division of Thoracic Imaging at UCSF, which, under his leadership, became one of the best in the world, conducting groundbreaking research in computed tomography (CT) and magnetic resonance evaluation of the normal lung and assessment of chest disease. He had particular interest in the CT diagnosis of asbestosis and wrote a number of articles on the subject.

Dr. Gamsu was the author or coauthor of 150 original articles and 60 book chapters. He edited three major textbooks, including the first and second editions of *Computed Tomography of the Body*, which was the authoritative work on CT of the chest for nearly 15 years. From 1977 to 1993, he served as director of the radiology residency program at UCSF. In 1996, he left UCSF to become professor and vice-chairman of the Department of Radiology at Weill Cornell Medical Center, New York, N.Y. From 1999 until his retirement in 2007, he served as director of outpatient radiology at the New York Hospital.

During his career, Dr. Gamsu served in numerous leadership positions in academic radiology and pulmonary medicine and received numerous honors and awards. He received the Association of University Radiologists gold medal in 1974 and was awarded

a fellowship in the American College of Radiology in 1991. From 1990 to 1992, he was editor-in-chief of *Investigative Radiology*. In successive years (1999–2001), he was elected president of the two primary academic thoracic radiology organizations, the Fleischner Society and the Society of Thoracic Radiology. Most recently, he was chosen to receive the Society of Thoracic Radiology's gold medal in recognition of his lifetime achievements in thoracic radiology and contributions to the society.

Dr. Gamsu taught and lectured internationally during his career and served on numerous editorial boards and societal committees. Despite his considerable personal

accomplishments in the field of thoracic radiology, Dr. Gamsu is perhaps best recognized for his training of a generation of academic thoracic radiologists. In his 25-year tenure at UCSF and subsequent years at Weill Cornell Medical Center, he was responsible for the training of nearly 40 thoracic radiology fellows, many of whom have become leaders in the field. It is difficult to think of an individual with a greater impact on the field of thoracic radiology over the past quarter century than Dr. Gordon Gamsu.

He is survived by his wife, Dr. Gay Morris, and his daughter, Jessica.

– Reprinted with permission of the RSNA. Klein J, Webb, W. Richard. In Memoriam: Gordon Gamsu, MD, *Radiology* 2009; 251:951



Gordon Gamsu, MD

IMAGING RESEARCH SYMPOSIUM SHOWCASES INNOVATION AND FIRST ANNUAL BRUCE HASEGAWA AWARD

The department's Sixth Annual Imaging Research Symposium, on September 15, 2009, was the occasion for presenting the first annual Bruce Hasegawa Award for Excellence in Biomedical Imaging to David Pham, PhD.

The Hasegawa award recognizes a radiology and biomedical imaging graduate student or postdoctoral scholar. It is funded by Gordon Honda, MD, in memory of his friend Bruce Hasegawa, PhD, a brilliant scientist, teacher, and mentor in the Department of Radiology and Biomedical Imaging, who died in 2008.



Bruce Hasegawa Award: (l-r) David Pham, recipient, with Ron Arenson, Ted Hasegawa, Marilyn Hasegawa, Rebecca Hasegawa, and Gordon Honda.

The Distinction of Hasegawa's Name

Pham is a postdoctoral scholar working in the Nuclear-Optical Specialized Resource Group. "Dr. Hasegawa bought me my first lunch here at UCSF, an unforgettable introduction to jerk chicken," Pham recalled in his remarks.

"Although I was not privileged to study under him, my few brief encounters with him left lasting impressions. His warmth, good nature, generosity, and approachability often made me forget how huge a scientific giant he was. I am grateful for this award, but even more for the distinction that comes with Dr. Hasegawa's name and the excellence that it embodies."

Special guests at the ceremony, held in Millberry Union, included Dr. Gordon and Mrs. Ruri Honda, Hasegawa's brother and his wife, Ted and Marilyn Hasegawa, and their daughter Rebecca.

Symposium Grows in Scope

The symposium highlighted the innovative research being done in the department and at UCSF. Moderated by faculty Christopher Hess MD, PhD, and Xiaojuan Li, PhD, the audience of 200 people in Cole Hall auditorium gained insights into diverse research areas. Presentations and posters addressed cancer, neurodegenerative diseases, musculoskeletal diseases, and cardiovascular diseases. Information on medical informatics and image processing, MR/CT contrast agent development, and the imaging modalities of CT, MR, PET, SPECT, MEG, EEG, optical imaging, and ultrasound were covered.

Executive Vice-Chair of Radiology William P. Dillon, MD, gave an overview of the many clinical studies underway in the department. Vice-Chair of Research Sharmila Majumdar, PhD, reviewed basic science studies.

The symposium planning committee headed by David Saloner, PhD, and Li encouraged faculty, research staff, residents, fellows, post-docs, and students to submit abstracts of their work in all areas of imaging research. A committee reviewed these and selected topics for presentation.

Michael Hope, MD, and Sophie Boddington each received a symposium award certificate for Outstanding Speaker Presentation. Both Hannes Kroll, MD, and Peder Larson, PhD, received an Outstanding Poster certificate.



Speaker and Poster Awards: (l-r) David Saloner, of the symposium planning committee with Sophie Boddington, Hannes Kroll, and symposium planner Xiaojuan Li.

THE LANNA LEE AWARD 2009

Patients and employees on the second shift in Radiology are in the “very capable hands” of Abdella Saleh, RT, the recipient of the 2008 Lanna Lee Award. Director of Medical Operations Kathy Knoerl went on to describe Saleh as “a perfect example of the spirit of the Lanna Lee award,” given annually to the outstanding technologist in the Department of Radiology and Biomedical Imaging.

Saleh joined the Department of Radiology and Biomedical Imaging in 1989 as a hospital assistant. A hard worker, his manager encouraged him to become a technician because of his work ethic and the personal care he gave patients. Saleh continued to work in the department on weekends and evenings while he completed the Radiologic Technologist program at City College.



Abdella Saleh with Nemia Ah, Lanna Lee's sister.

After graduation, Abdella applied for a position in the Diagnostic Department in Radiology. Given his previous experience in the department, he could work in all areas of the department, but he soon became the expert in fluoroscopy procedures. Saleh is known for his excellent customer service and his ability to anticipate the radiologist's requests.

Saleh's climb up the career ladder in Radiology led to his becoming the afternoon supervisor in 2003. “Abdella has excellent leadership qualities; he knows what needs to be done and works in that direction. He is well respected by the employees on the second shift, as well as the leadership in Radiology and radiologists. His calm demeanor and constant professionalism are well-suited for a busy department. Abdella leads by example and is very willing to share his extensive knowledge with staff,” Knoerl concluded.

Saleh's climb up the career ladder in Radiology led to his becoming the afternoon supervisor in 2003. “Abdella has excellent leadership qualities; he knows what needs to be done and works in that direction. He is well respected by the employees on the second shift, as well as the leadership in Radiology and radiologists. His calm demeanor and constant professionalism are well-suited for a busy department. Abdella leads by example and is very willing to share his extensive knowledge with staff,” Knoerl concluded.

The Lanna Lee Award was established in memory of Lanna Lee, a senior radiology technologist who died on her way home from work in 1989 during the Loma Prieta earthquake. Lee was a role model for others, always working with a smile and delivering excellent care to her patients. Since her death, this award is given annually in her honor at the department's Holiday Party. Her family regularly attends the award celebration to share in the knowledge that her spirit lives on.



Svetlana Lee, daughter of Lanna Lee, with Kathy Knoerl.

The Lanna Lee Award was established in memory of Lanna Lee, a senior radiology technologist who died on her way home from work in 1989 during the Loma Prieta earthquake. Lee was a role model for others, always working with a smile and delivering excellent care to her patients. Since her death, this award is given annually in her honor at the department's Holiday Party. Her family regularly attends the award celebration to share in the knowledge that her spirit lives on.

Historically the clerkship has been the most popular senior elective in the UCSF School of Medicine curriculum, with enrollment determined by lottery. However, recent budget cuts reduced the likelihood of being selected. This year, the fourth-year Radiology elective is being offered only three out of nine months. This, and other budget-related restrictions have intensified the need to expand the use of independent, self-guided learning tools (now being used at San Francisco General Hospital and the San Francisco Veterans Affairs Medical Center) to teach medical students Radiology

HENRY I. GOLDBERG CENTER FOR ADVANCED IMAGING EDUCATION

Writing in the *British Medical Journal*, Umar Tariq described his experience in the month-long Radiology elective course for fourth-year medical students as a “learning treat...it does not feel like learning; by the end of the elective, you would realize that you had great fun and you also learned a lot.”

Tariq, a visiting medical student from Pakistan, was one of 110 students during the 2008-2009 academic year to benefit from the popular Goldberg Center clerkship. In recent years, the center's director, Richard Breiman, MD, and associate director, Marcia McCowin, MD, have integrated more computer-based, self-guided learning modules and interactive teaching into the traditional lecture-based curriculum. “We are less dependent on Radiology faculty and are teaching students on the very technology they will be using when they go into practice,” said Breiman.

The computer-based Radiology 100 syllabus, designed by Henry I. Goldberg, MD, in the mid-1990s to augment didactic teaching and the Margulis/Ross Teaching File are in the midst of a major upgrade. The

The Evolving Role of the Radiology Curriculum

The computer-based Radiology 100 syllabus, designed by Henry I. Goldberg, MD, in the mid-1990s to augment didactic teaching and the Margulis/Ross Teaching File are in the midst of a major upgrade. The

original, film-based teaching file, developed at UCSF in the 1960s, became the basis for the American College of Radiology's teaching file. Now digitized and enhanced by an improved user interface, it can be searched by keyword, making it easier to find teaching cases. The RAD 100 syllabus is available online to UCSF School of Medicine students and by subscription to other medical schools, including Stanford and UCLA, a revenue source for the Goldberg Center. Breiman, aided by two student "curricular ambassadors," is also developing a new "roadmap" for Radiology teaching throughout the four years of medical school.

UCSF continues to share its radiology teaching expertise. Attendees at the 2009 meeting of the Association of University Radiologists gained insights into the UCSF Radiology curriculum during four sessions featuring Breiman. He spoke on the role of radiology in teaching anatomy, on the Goldberg Center's experience involving residents in teaching medical students, and on the relative merits of a radiology elective vs. a required course. He also led a session on the use of technology in teaching medical students, including 3D and interactive learning modules. Breiman's stereoscopic 3D work was the topic of a presentation at the 2009 SIGGRAPH International Conference on Computer Graphics and Interactive Techniques.

Goldberg Center Advanced 3D Imaging Research

Drawing on Breiman's expertise in three-dimensional image processing techniques, the Goldberg Center is exploring navigation and display devices. The Center has produced high-resolution 3D renderings for both 2D and stereoscopic 3D display viewable on personal computers, 3D workstations, handheld devices such as an iPhone, and in classrooms with 3D viewing hardware. "Making these images available on a range of devices greatly expands access for students and teachers," Breiman said.

UCSF, visiting medical students, and postgraduate trainees participate in projects in the lab, including several Radiology residents and students committed to residencies at UCSF, UCLA, UCSD, USC, Massachusetts General Hospital/Harvard, the University of Iowa, and the University of Kentucky. Students from Germany, France, India, Pakistan, Israel, and Lebanon have worked on projects for extended periods.

This year, their work resulted in:

- Two presentations at UCSF's summer student research symposium
- A presentation at the 2009 Medicine Meets Virtual Reality meeting
- Two projects nominated for the 2009 RSNA Research Trainee Award

For more information on the Goldberg Center please visit www.radiology.ucsf.edu/medstudents.

Student Kudos for the Goldberg Center

"The teaching reflects the excellent reputation this department and institution have worldwide. Having attended several rotations of this type in several institutions, I must say this has been my best and most learned one yet. I learned more in the few weeks here than I had in the first three years of medical school." *David Mobley, Columbia University medical student*

"The Radiology 140.03 elective, which draws together the amazing faculty and resources of the UCSF Radiology Department, exposes students to the cutting-edge medical imaging research being done at UCSF, while preparing them for practice in a health care system in which imaging continues to become ever more important." *Allison Tillack, UCSF medical student*



June 2009, 140.03 Medical Student Radiology Elective in the Henry I. Goldberg Center.

RADIOLOGY POSTGRADUATE EDUCATION

In the 51 years that the Department of Radiology and Biomedical Imaging has offered CME courses, the stock market has peaked and plummeted, but the value of the courses and caliber of the speakers presented by Radiology Postgraduate Education (PGE) has remained constant. We will continue this tradition into 2010, being ever-mindful of the need to maximize learning in each CME activity.

Personnel Changes

After three successful years and countless hours, Jeanne LaBerge, MD, stepped down as course chair for our Radiology Resident Review course to assume a leadership position in the American Board of Radiology. LaBerge instituted many improvements to this flagship postgraduate education course, making it one of (if not) the best review courses in the nation. We thank her for her dedication and contributions.

The new Course Chair, Vickie Feldstein, MD, is already at work to make it even more beneficial for the senior residents from programs throughout the U.S. and Canada, as well as practicing general radiologists, who attend.

The Resident Review course is also being evaluated to determine how it could and should be modified in light of the changes that the American Board of Radiology will be making to the core and certifying examinations starting in 2013. Go to www.theabr.org/present/overview_changes_2.pdf for an overview of these changes.

In February, Tym Peters, who had served as director of Radiology Postgraduate Education since 2001, became the director of the UCSF Office of Continuing Medical Education for the School of Medicine. In this capacity, he manages all continuing medical education activities for the entire School of Medicine. Radiology Postgraduate Education is now managed by Mary Sheridan, who is working closely with Lynne Steinbach, MD, chair of the Postgraduate Education Committee.

2009 Highlights

Our first course-at-sea touring Alaska's Inside Passage onboard the Regent Seven Seas *Mariner* was the perfect combination of outstanding educational presentations, spectacular scenery and wildlife viewing opportunities, and unparalleled service and amenities onboard the six-star, all-suite ship. We also enjoyed a visit from an onboard celebrity, Robin Cook, doctor and author of numerous best-selling medical thrillers, including *Coma*. He joined us to hear Alisa Gean, MD, deliver a moving presentation on *Lessons from Iraq: A Pictorial Tutorial on the Medical Care Given to Our Troops*. We are evaluating the feasibility of a future cruise course in 2011. Visit our website, www.radiology.ucsf.edu/postgrad, for details. If you have a favorite cruise destination or cruise line you would like us to consider, please email your suggestions to cme@radiology.ucsf.edu.

We continue to add extra value to our courses by offering ABR-approved self-assessment modules



Alaska CME Cruise 2009: (l-r) Judy Yee, Lynne Steinbach, Robin Cook, Ron Arenson, Alisa Gean.

(SAM) at no additional charge to attendees. Faculty have developed 10 modules since the inception of this program in 2007. New SAMs are being developed and included in our 2010 courses to help you fulfill your 20 required SAMs. The need for SAMs will continue to grow, as more radiologists are being (re)certified for the first time since the SAMs requirement was instituted in 2002.

New for 2010

Along with long-standing annual courses, we are offering new destinations and hotels and refocusing some of our regular offerings.

In February, we will hold back-to-back Musculoskeletal and Abdomen & Pelvis courses at the Westin Mission Hills Resort and Spa in Rancho Mirage, Calif. This new venue was chosen for its central location in the Greater Palm Springs area. The resort is situated on 360 acres and offers two world-class golf courses and extensive recreational facilities.

Our annual Diagnostic Imaging Course held in May in Yosemite will move to the ocean in alternate years. May 24-28, 2010 we will meet for the first time at the Intercontinental, The Clement Monterey. The Monterey Peninsula offers scenic beauty, historic Monterey, quaint Carmel-by-the-Sea, Cannery Row, Pebble Beach, and the world-renowned Monterey Bay



© Monterey Bay Aquarium/Randy Wilder

Sea otters and the Monterey Bay Aquarium will delight attendees of the 2010 Neuro/Musculoskeletal Imaging Course.

Aquarium. Christine Glastonbury, MBBS, will chair this course, focusing on neuro/musculoskeletal imaging.

We will make our first journey to beautiful Bermuda for our international destination course in June. We will meet at The Fairmont Southampton from June 20-25, 2010 with course chair Lori Strachowski, MD. With its romantic heritage dating back to the privateers of the 16th century, Bermuda provides colorful architecture, tropical beauty, captivating crystal waters, and pink-hued beaches. You can also experience British traditions such as afternoon tea and cricket without having to fly across the Atlantic Ocean.

Please take advantage of one of these electronic media to stay in touch with us and keep abreast of our latest developments. We look forward to seeing you at one of our future courses.

- Find the most current course schedule at www.radiology.ucsf.edu/postgrad
- Receive information about our courses via email; to join our list email cme@radiology.ucsf.edu
- Receive breaking news about Postgraduate Education by following us on Twitter at www.twitter.com/ucsfradiology



International CME destination 2010, Bermuda

2010 RADIOLOGY CME CALENDAR

January 4-8, 2010

Imaging and Intervention on the Mayan Riviera
The Fairmont Mayakoba Resort - Playa del Carmen,
Mexico

January 10-15, 2010

Breast Imaging & Digital Mammography
The Fairmont Orchid - Kona, Hawaii

January 17-22, 2010

Imaging Update in Kona: Top Teachers in Radiology
The Fairmont Orchid - Kona, Hawaii

January 31-February 2, 2010

Musculoskeletal MRI
The Westin Mission Hills Resort & Spa - Rancho
Mirage, California

February 3-5, 2010

Abdomen & Pelvis CT/MRI
The Westin Mission Hills Resort & Spa - Rancho
Mirage, California

February 14-19, 2010

Body and Musculoskeletal Imaging in Paradise
The Fairmont Orchid - Kona, Hawaii

February 28-March 5, 2010

Radiology Resident Review
The Fairmont San Francisco – San Francisco, California

March 7-12, 2010

Spring Training for Radiologists
Disney's Contemporary Resort – Lake Buena Vista,
Florida

March 19-21, 2010

Breast Imaging Update
The Westin San Francisco Market Street - San Francisco,
California

March 25-27, 2010

Virtual Colonoscopy Workshop
UCSF China Basin Research Center – San Francisco,
California

April 18-22, 2010

Imaging Update in the Capital
The Fairmont Washington, DC – Washington, DC

May 24-28, 2010

Neuro/Musculoskeletal Imaging in Monterey
Intercontinental, The Clement Monterey – Monterey,
California

June 20-25, 2010

Brain, Body and Breast Imaging in Bermuda
The Fairmont Southampton – Southampton, Bermuda

June 24-26, 2010

Virtual Colonoscopy Workshop
UCSF China Basin Research Center – San Francisco,
California

September 9-11, 2010

Virtual Colonoscopy Workshop
UCSF China Basin Research Center – San Francisco,
California

September 20-24, 2010

Interventional Radiology Review
UCSF Parnassus Campus – San Francisco, California

September 26-October 1, 2010

Women's Imaging in Wine Country
The Fairmont Sonoma Mission Inn & Spa - Sonoma,
California

October 18-22, 2010

UCSF Radiology Highlights
JW Marriott, San Francisco, California

October 31-November 5, 2010

Diagnostic Radiology Seminars
The Fairmont Kea Lani – Maui, Hawaii

November 8-12, 2010

Breast Imaging and Digital Mammography
TBD, Palm Springs, California

December 5-10, 2010

Imaging Warm-Up in the Caribbean
The Westin St. John, US Virgin Islands

December 16-18, 2010

Virtual Colonoscopy Workshop
UCSF China Basin Research Center – San Francisco,
California

2010-11 CALENDARS NOW AVAILABLE ONLINE!

For further information please contact:


Radiology Postgraduate Education, UCSF School of Medicine
3333 California Street, Suite 375, San Francisco, CA 94143-0629

Tel: 415/476-5731 Fax: 415/476-9213 E-mail: cme@radiology.ucsf.edu Web: www.radiology.ucsf.edu/postgrad

Course dates and locations are subject to change without notice before publication of a final brochure.

Please visit our website for the most current information.

RESEARCH DIRECTIONS AND RECENT PUBLICATIONS



Abdominal Imaging

Fergus V. Coakley, MD, Chief

Research Directions:

- Dynamic contrast-enhanced MRI and CT for assessment of solid organs and tumors in the abdomen and pelvis
- Advanced modifications of MRI and CT techniques to optimize assessment of hepatic, biliary, and renal disease
- Combined MRI and MR spectroscopic imaging (MRSI) in localizing and staging prostate cancer
- Advanced hepatic imaging, including multi-detector CT, CT cholangiography, new hepatobiliary MR contrast agents, and MR cholangiopancreatography
- Radiological evaluation of diffuse liver disease, including cirrhosis, pseudocirrhosis, and non-alcoholic hepatitis
- 3D rendering of CT and MR images, including projectional and volumetric applications, and CT colonography
- Role of prenatal MRI and MRSI in fetal anomalies, fetal lung maturity, and obstetric disease
- Evaluation of prostate cancer with MRSI in a prospective, multi-institutional, clinico-pathologic study
- The promotion of evidence-based abdominal imaging, including systematic validation or debunking of commonly held opinions and assumptions

Recent Key References:

Bahl M, Qayyum A, Westphalen AC, Noworolski SM, Chu PW, Ferrell L, Tien PC, Bass NM, Merriman RB. Liver steatosis: investigation of opposed-phase T1-weighted liver MR signal intensity loss and visceral fat measurement as biomarkers. *Radiology*. 2008 Oct;249(1):160-6.

Barajas RF Jr, Yeh BM, Webb EM, Westphalen AC, Puder L, Coakley FV. Spectrum of CT findings in patients with atrial fibrillation and nontraumatic acute abdomen. *AJR Am J Roentgenol*. 2009 Aug;193(2):485-92.

Baxter S, Wang ZJ, Joe BN, Qayyum A, Taouli B, Yeh BM. Timing bolus dynamic contrast-enhanced (DCE) MRI assessment of hepatic perfusion: Initial experience. *J Magn Reson Imaging*. 2009 Jun;29(6):1317-22.

Poff JA, Coakley FV, Qayyum A, Yeh BM, Browne LW, Merriman RB, Ferrell LD, Feldstein VA. Frequency and histopathologic basis of hepatic surface nodularity in patients with fulminant hepatic failure. *Radiology*. 2008 Nov;249(2):518-23.

Wang ZJ, Joe BN, Coakley FV, Zaharchuk G, Busse R, Yeh BM. Urinary oxygen tension measurement in humans using magnetic resonance imaging. *Acad Radiol*. 2008 Nov;15(11):1467-73.

Biostatistics and Outcomes Research Specialized Resource Group

Research Directions:

The multidisciplinary MD and PhD faculty and research staff of the Biostatistics and Outcomes Research SRG share a common interest in statistical and epidemiological evaluation of radiology techniques. Our mission is to (1) provide stable, efficient, and cutting-edge statistical and research methodological support to departmental researchers in study design, data collection, clinical research, data analysis, publication, and grant applications; (2) develop innovative, customized statistical and epidemiological methods for radiological research; (3) use advancements in statistical and epidemiological methods to improve the scientific quality of, and help bridge research projects in the department; and (4) provide appropriate levels of training to research fellows, residents, and faculty. Current research includes:

- Determining efficient designs to integrate new markers in drug development/clinical trials
- Outcomes
- Bayesian reconstruction of low-resolution MRI modalities
- Voxel-based statistical methods
- Bayesian decision analysis for diagnostic methods
- Location error
- Optimizing statistical design and methodology to validate new techniques in patient care
- Unifying statistical models for imaging meta-analysis with aggregated and individual patient data
- Assessing the risk of cancer associated with incidental findings identified on ultrasound and CT imaging
- Developing standardized guidelines for interpreting ultrasound imaging
- Assessing patterns of imaging over time using computer tomography and quantifying associated exposure to ionizing radiation

- Determining patient, physician, and technologist factors associated with high CT radiation exposure
- Determining the risk of cancer associated with high medical radiation exposure
- Describing patterns of prenatal screening for birth defects and identifying multi-level factors that influence the adoption of newer screening tests
- Texture analysis and data mining of multimodal medical images
- Improved diagnostic imaging using MR spectroscopy

Key Recent Publications:

Fan SK, Venook AP, Lu Y. Design issues in dose-finding Phase I trials for combinations of two agents. *J Biopharm Stat.* 2009;19(3):509-23.

Jin H, Lu Y. A non-inferiority test of areas under two parametric ROC curves. *Contemp Clin Trials.* 2009 Jul;30(4):375-9.

Kornak J, Dunham B, Hall DA, Haggard MP. 237-253 Nonlinear voxel-based modelling of the haemodynamic response in fMRI. *J Appl Stat.* 2009 36(3): 237-253.

Kornak J, Young K, Schuff N, Du A, Maudsley AA, Weiner MW. K-Bayes Reconstruction for Perfusion MRI I: Concepts and Application. *J Digit Imaging.* 2009 Feb 10. [Epub ahead of print]

Smith-Bindman R, Miglioretti DL, Larson EB. Rising use of diagnostic medical imaging in a large integrated health system. *Health Aff (Millwood).* 2008 Nov-Dec;27(6):1491-502.

Schueler KM, Chu PW, Smith-Bindman R. Factors associated with mammography utilization: a systematic quantitative review of the literature. *Womens Health (Larchmt).* 2008 Nov;17(9):1477-98.



Brain Behavior Research Interest Group

Srikantan Nagarajan, PhD, Co-Director
Pratik Mukherjee, MD, PhD, Co-Director

Research Directions:

The vision of the Brain-Behavior RIG is to:

- Understand the

relationship between brain and behavior in health and disease

- Integrate information from molecules to mind
- Translate neuroimaging advances to the clinic

Our specific mission is to:

- Map and analyze functional activation in the brain
- Map and analyze structural and functional network connectivity in the brain
- Identify neurophysiological and neuroanatomical correlates of behavior in health and disease

Specific projects involve:

- Understanding the neural bases of sensory and motor function, speech, language, learning, memory,

attention, executive function, and social cognition as measured by brain structure, function, and connectivity in the healthy and in a variety of diseases

- Developing biological, brain-based markers for diagnosis, monitoring disease progression, and response to therapies
- Developing and disseminating powerful, state-of-the-art computational tools and resources for multimodal structural and functional brain imaging
- Developing novel brain-based therapies

The RIG's activities are currently involved with these specific populations:

- Healthy young adults, normally developing children, and normal aging adults
- Patients with epilepsy, traumatic brain injury; neuroENT (tinnitus, spasmodic dysphonia); and neuropsychiatric illnesses (schizophrenia, depression, PTSD, lupus, Gulf War Syndrome); multiple sclerosis, movement disorders (Parkinson's disease, focal hand dystonia), prion diseases (CJD); neurodevelopmental disorders (autism, agenesis of the corpus callosum, cerebral palsy); neurodegenerative diseases (Alzheimer's/MCI, FTD, ALS, semantic dementia, PPA); brain tumors; cerebrovascular disease (stroke, AVM, sickle cell disease)

Recent Key References:

Henry RG, Shieh M, Amirbekian B, Chung S, Okuda DT, Pelletier D. Connecting white matter injury and thalamic atrophy in clinically isolated syndromes. *J Neurol Sci* 2009; 282:61-6.

Hinkley LB, Webster RL, Byl NN, Nagarajan SS. Neuroimaging characteristics of patients with focal hand dystonia. *J Hand Ther.* 2009 Apr-Jun;22(2):125-34.

Niogi SN, Mukherjee P, Ghajar J, Johnson C, Kolster R, Lee H, Suh M, Manley GT, Candliss BD. Structural dissociation of attentional control and memory in adults with and without mild traumatic brain injury. *Brain.* 2008 Dec;131(Pt 12):3209-21.

Niogi SN, Mukherjee P, Ghajar J, Johnson C, Kolster RA, Sarkar R, Lee H, Meeker M, Zimmerman RD, Manley GT, McCandliss BD. Extent of microstructural white matter injury in postconcussive syndrome correlates with impaired cognitive reaction time: a 3T diffusion tensor imaging study of mild traumatic brain injury. *AJNR Am J Neuroradiol.* 2008 May;29(5):967-73.

Ventura MI, Nagarajan SS, Houde JF. Speech target modulates speaking induced suppression in auditory cortex. *BMC Neurosci.* 2009 Jun 13;10:58.

Brain Cancer Research Interest Group

Soonmee Cha, MD, Co-Director
Sarah J. Nelson, PhD, Co-Director

Research Directions:

Evaluating patients with brain tumors is a major focus for imaging research at UCSF and is an important application for the development of novel MR imaging and spectroscopy techniques. This research is performed in close collaboration with the Brain Tumor Research

Center, which includes a broad array of basic scientists and clinical researchers engaged in multi-disciplinary, translational research studies with a common disease focus. The researchers in the brain tumor RIG have substantial NIH and other agency grant funding to support their work. Key methodologies being applied to understand the underlying mechanisms of response to therapy and to validate *in vivo* parameters include the *ex vivo* analysis of image-guided tissue samples and the applications of NMR spectroscopy in cell and pre-clinical model systems. *In vivo* imaging methodologies under consideration include the following mechanisms for probing anatomic, vascular, structural, and metabolic properties of brain tumors.

- Applying T2*-weighted magnitude and phase images acquired with 3T and 7T whole body scanners for visualizing heterogeneity in the region of T2 hyperintensity caused by local changes in susceptibility due to hemorrhage and other treatment effects
- Measuring changes in vascular properties using arterial spin labeling, dynamic-contrast enhanced, (DCE) and perfusion-weighted (PW) imaging for patients receiving anti-angiogenic therapies
- Assessing the changes in diffusion tensor imaging for mapping connectivity by applying tractography to visualize the disruption in normal tissue structure caused by the tumor, and in the pre-operative analysis of the patient for surgical planning purposes
- Evaluating metabolically abnormal, non-enhancing tumor to quantify disease burden, plan treatment, and assess treatment response using 1H MRSI and hyperpolarized C-13 metabolic imaging
- Identifying parameters that contribute to the characterization of lesions which are non-enhancing on post-Gadolinium T1-weighted images to assess tumor burden and select the most appropriate treatments
- Correlating non-invasive imaging parameters with the genetic and molecular properties of tumors to identify lesions that are likely to have a poor outcome and to tailor therapy to individual patients
- Investigating the metabolic profile of primary/recurrent tumor with *ex vivo* HRMAS of image-guided biopsies to identify disease pathways that are affected and could be targeted for therapeutic intervention
- Developing new surrogate metabolic markers of disease progression based on association of *ex vivo* and *in vivo* metabolic profiles and imaging data

Recent Key References:

Crawford FW, Khayal IS, McGue C, Saraswathy S, Pirzkall A, Cha S, Lamborn KR, Chang SM, Berger MS, Nelson SJ. Relationship of pre-surgery metabolic and physiological MR imaging parameters to survival for patients with untreated GBM. *J Neurooncol.* 2009 Feb;91(3):337-51.



Khayal IS, McKnight TR, McGue C, Vandenberg S, Lamborn KR, Chang SM, Cha S, Nelson SJ. Apparent diffusion coefficient and fractional anisotropy of newly diagnosed grade II gliomas. *NMR Biomed.* 2009 May;22(4):449-55.

Saraswathy S, Crawford FW, Lamborn KR, Pirzkall A, Chang S, Cha S, Nelson SJ. Evaluation of MR markers that predict survival in patients with newly diagnosed GBM prior to adjuvant therapy. *J Neurooncol.* 2009 Jan;91(1):69-81.

Pirzkall A, McGue C, Saraswathy S, Cha S, Liu R, Vandenberg S, Lamborn KR, Berger MS, Chang SM, Nelson SJ. Tumor regrowth between surgery and initiation of adjuvant therapy in patients with newly diagnosed glioblastoma. *Neuro Oncol.* 2009 Feb 19. [Epub ahead of print]

Ross J, Najjar AM, Sankaranarayananpillai M, Tong WP, Kaluarachchi K, Ronen SM. Fatty acid synthase inhibition results in a magnetic resonance-detectable drop in phosphocholine. *Mol Cancer Ther.* 2008 Aug;7(8):2556-65.

Breast Cancer Research Interest Group

Nola Hylton, PhD, Co-Director

Bonnie N. Joe, MD, Co-Director

Research Directions:

The Breast RIG's research aims are to advance imaging-based approaches for breast cancer diagnosis, leading to earlier detection, reduction of disease recurrence, and improved survival. Our major research areas include:

- MRI and spectroscopy to assess breast tumor response to neoadjuvant chemotherapy. UCSF is the lead institution for the national ACRIN 6657/I-SPY breast cancer clinical trial testing MRI and molecular biomarkers for the prediction of treatment response and survival for women receiving neoadjuvant chemotherapy for locally advanced breast cancer.
- Computer-aided tools for real-time measurement of MRI biomarkers for breast cancer
- MRI of ductal carcinoma *in-situ* (DCIS) for staging and assessing response to hormonal treatment
- Quantitative mammographic breast density measurement for breast cancer risk assessment
- MRI-directed tissue biopsy for radiologic-pathologic correlation of imaging and molecular biomarkers
- MRI measurement of breast density and tissue composition



Recent Key References:

Aliu SO, Wilmes LJ, Moasser MM, Hann BC, Li KL, Wang D, Hylton NM. MRI methods for evaluating the effects of tyrosine kinase inhibitor administration used to enhance chemotherapy efficiency in a breast tumor xenograft model. *J Magn Reson Imaging*. 2009 May;29(5):1071-9.

Barker AD, Sigman CC, Kelloff GJ, Hylton NM, Berry DA, Esserman LJ. I-SPY 2: an adaptive breast cancer trial design in the setting of neoadjuvant chemotherapy. *Clin Pharmacol Ther*. 2009 Jul;86(1):97-100.

Cummings SR, Tice JA, Bauer S, Browner WS, Cuzick J, Ziv E, Vogel V, Shepherd J, Vachon C, Smith-Bindman R, Kerlikowske K. Prevention of breast cancer in postmenopausal women: approaches to estimating and reducing risk. *J Natl Cancer Inst*. 2009 Mar 18;101(6):384-98.

Klifa C, Carballido-Gamio J, Wilmes L, Laprie A, Shepherd J, Gibbs J, Fan B, Noworolski S, Hylton N. Magnetic resonance imaging for secondary assessment of breast density in a high-risk cohort. *Magn Reson Imaging* 2009. [Epub]

Kuerer HM, Albarracin CT, Yang WT, Cardiff RD, Brewster AM, Symmans WF, Hylton NM, Middleton LP, Krishnamurthy S, Perkins GH, Babiera G, Edgerton ME, Czerniecki BJ, Arun BK, Hortobagyi GN. Ductal carcinoma in situ: state of the science and roadmap to advance the field. *J Clin Oncol*. 2009 Jan 10;27(2):279-88.

Cardiac and Pulmonary Imaging

Charles B. Higgins, MD, Interim Chief

Research Directions:

Cardiac CT angiography (CTA)

- CTA assessment of coronary allograft vasculopathy after heart transplantation
- Use of cardiac CTA for pre-surgical clearance
- Use of cardiac CTA for definitive emergency room evaluation of atypical chest pain
- Evaluation of coronary atherosclerosis in patients with HIV infection

Cardiac CT

- Evaluation of pulmonary venous anatomy in atrial fibrillation
- Characterization of myocardial ischemic injury by contrast-enhanced MRI and CT

High-resolution CT

- High-resolution CT diagnosis of lung disease

- Clinical outcomes following negative CT for acute pulmonary embolism
- Predictors of poor outcome in patients with acute PE diagnosed by helical CT

Cardiac MRI

- Use of novel cardiac MRI techniques and computational modeling for the quantitative assessment of ventricular performance in congenital heart disease
- Use of multidimensional flow techniques for quantitative assessment of flow dynamics in congenital heart disease
- MRI to assess cardiac function after repair of tetralogy of Fallot; correlation with clinical outcomes
- MRI to assess cardiac function in the single ventricle patient after Fontan palliation; correlation with clinical outcomes
- Endovascular therapy and hemodynamic assessment using MRI guidance



Recent Key References:

Chang AY, FitzGerald SJ, Cannaday J, Zhang S, Patel A, Palmer MD, Reddy GP, Orдовas KG, Stillman AE, Janowitz W, Radford NB, Roberts AJ, Levine BD. Cardiovascular risk factors and coronary atherosclerosis in retired National Football League players. *Am J Cardiol*. 2009 Sep 15;104(6):805-11.

Elicker B, Pereira CA, Webb R, Leslie KO. High-resolution computed tomography patterns of diffuse interstitial lung disease with clinical and pathological correlation. *J Bras Pneumol*. 2008 Sep;34(9):715-44.

Hope MD, Meadows AK, Hope TA, Orдовas KG, Reddy GP, Alley MT, Higgins CB. Images in cardiovascular medicine. Evaluation of bicuspid aortic valve and aortic coarctation with 4D flow magnetic resonance imaging. *Circulation*. 2008 May 27;117(21):2818-9.

Zamora AC, Collard HR, Barrera L, Mendoza F, Webb WR, Carrillo G. Silicone injection causing acute pneumonitis: a case series. *Lung*. 2009 Aug;187(4):241-4.

Zhuo H, Yang K, Lynch SV, Dotson RH, Glidden DV, Singh G, Webb WR, Elicker BM, Garcia O, Brown R, Sawa Y, Misset B, Wiener-Kronish JP. Increased mortality of ventilated patients with endotracheal *Pseudomonas aeruginosa* without clinical signs of infection. *Crit Care Med*. 2008 Sep;36(9):2495-503.

Contrast Agent Research Group

Heike Daldrop-Link, MD, PhD, Director

The research program of the Contrast Agent Research group focuses on “cellular MR imaging,” a new discipline that combines cell biology and *in vivo* MR imaging. Cellular imaging provides non-invasive *in vivo* detection of specific cell populations in target organs. Our long-term research objectives are to diagnose microscopic disease before it becomes symptomatic, to monitor cellular therapies that specifically eradicate pathologic cells, and to monitor stem cell therapies that regenerate physiologic cell populations.

Research Directions:

- *In vivo* tracking of contrast-agent-labeled stem cells in arthritic joints for non-invasive assessment of stem cell engraftment outcomes
- Labeling human embryonic stem cells with clinically applicable contrast agents and fluorescent dyes for a non-invasive cell depiction with MRI and optical imaging
- Monitoring the efficacy of new cellular immunotherapies designed specifically to eradicate cancer cells.
- Specific *in vivo* targeting of breast and ovarian cancers for improved cancer detection and characterization; specifically, evaluating novel folate-receptor contrast agents for detecting breast and ovarian cancers



Recent Key References:

Daldrop-Link HE, Mohanty A, Cuenod C, Pichler B, Link T. New perspectives on bone marrow contrast agents and molecular imaging. *Semin Musculoskelet Radiol*. 2009 Jun;13(2):145-56.

Henning TD, Wendland MF, Golovko D, Sutton EJ, Sennino B, Malek F, Bauer JS, McDonald DM, Daldrop-Link H. Relaxation effects of ferucarbotran-labeled mesenchymal stem cells at 1.5T and 3T: discrimination of viable from lysed cells. *Magn Reson Med*. 2009 Aug;62(2):325-32.

Tavri S, Jha P, Meier R, Henning TD, Mueller T, Hostetter D, Knopp C, Johansson M, Reinhardt V, Boddington S, Sista A, Wels W, Daldrop-Link HE: Optical imaging of cellular immunotherapy against prostate cancer. *Mol Imaging*. 2009 Jan-Feb;8(1):15-26.

Wang J, Boddington S, Wendland M, Meier R, Corot C, Daldrop-Link HE: MR Imaging of Ovarian Tumors using Folate-Receptor targeted contrast agents. *Pediatr Radiol*. 2008 May;38(5):529-37.

Additional references are available at www.radiology.ucsf.edu/contrast_agent.

Goldberg Center for Advanced Imaging Education

Richard S. Breiman, MD, Director

Research Directions:

- Applying technology to teaching:
 - 3D image processing, including stereoscopic 3D
 - Interactive software, such as Flash, for the creation of teaching modules
 - Stereoscopic 3D displays
 - Display of educational content on handheld displays
 - Handheld devices for 3D navigation
 - Simplified user interfaces for 3D rendering
- Focusing educational research on the assessment of the learning value of techno-centric teaching methods, such as computer-based interactive teaching modules
- Assessing the value of 3D renderings, including stereoscopic 3D, in teaching normal and abnormal anatomy
- Simulating surgical and other interventional procedures, and communicating the results of diagnostic imaging examinations
- Creating research and curricular development opportunities for students and residents

Recent Key References:


Breiman RS, Coakley FV, Webb EM, Ellingson JJ, Roberts JP, Kohr J, Lutz J, Knoess N, Yeh BM. CT cholangiography in potential liver donors: effect of premedication with intravenous morphine on biliary caliber and visualization. *Radiology*. 2008 Jun;247(3):733-7.

Chawla SC, Jha P, Breiman R, Farmer D, Gooding C. Congenital tracheobiliary fistula diagnosed with contrast-enhanced CT and 3-D reformation. *Pediatr Radiol*. 2008 Sep;38(9):999-1002.

Hsu CT, Wang ZJ, Yu AS, Gould RG, Fu Y, Joe BN, Qayyum A, Breiman RS, Coakley FV, Yeh BM. Physiology of renal medullary tip hyperattenuation at unenhanced CT: urinary specific gravity and the NaCl concentration gradient. *Radiology*. 2008 Apr;247(1):147-53.

Qayyum A, Chen DM, Breiman RS, Westphalen AC, Yeh BM, Jones KD, Lu Y, Coakley FV, Callen PW. Evaluation of diffuse liver steatosis by ultrasound, computed tomography, and magnetic resonance imaging: which modality is best? *Clin Imaging*. 2009 Mar-Apr;33(2):110-5.

Teistler M, Breiman RS, Lison T, Bott OJ, Pretschner DP, Aziz A, Nowinski WL. Simplifying the exploration of volumetric images: development of a 3D user interface for the radiologist's workplace. *J Digit Imaging*. 2008 Oct;21 Suppl 1:S2-12.



Interventional Magnetic Resonance Imaging

David Saloner, PhD, Director

Research Directions:

- Evaluating the benefit added by using MRI in combination with an interventional angiography suite
- Assessing the use of MR-determined hemodynamic



measures to monitor interventional procedures, such as stenting or angioplasty

- Determining changes in end-organ perfusion in response to interventional procedures
- Developing methods for site-specific delivery of therapeutic agents
- Evaluating MR monitoring of tumor embolization therapy
- MR guidance of deep brain stimulator placement

Recent Key References:

Martin AJ, Starr PA, Larson PS. Software requirements for interventional MR in restorative and functional neurosurgery. *Neurosurg Clin N Am*. 2009 Apr;20(2):179-86.

Carlsson M, Martin A, Ursell P, Saloner D, and Saeed M. Magnetic Resonance Imaging Quantification Of Left Ventricular Dysfunction Following Coronary Microembolization. *Magn Reson Med*. 2009 Mar;61(3):595-602.

Dicks DL, Carlsson M, Heiberg E, Martin A, Saloner D, Arheden H, Saeed M. Persistent decline in longitudinal and radial strain after coronary microembolization detected on velocity encoded phase contrast magnetic resonance imaging. *J Magn Reson Imaging*. 2009 Jul;30(1):69-76.

Dicks D, Saloner D, Martin A, Carlsson M, Saeed M. Percutaneous transcatheter VEGF gene therapy: MRI guided delivery and characterization of 3D myocardial strain. *Int J Cardiol*. 2009 Apr 5. [Epub]

Martin AJ, Baek B, Acevedo-Bolton G, Higashida RT, Comstock J, Saloner DA. MR imaging during endovascular procedures: an evaluation of the potential for catheter heating. *Magn Reson Med*. 2009 Jan;61(1):45-53.

Interventional Radiology

Robert K. Kerlan, Jr., MD, Chief

Research Directions:

- Joint project with Transplant Service for implantation of pancreatic islet cells
- Joint project with Transplant Service for downstaging hepatocellular carcinoma in potential transplant candidates

- Joint project with Abdominal Imaging using MR diffusion imaging to differentiate flow abnormalities from hepatocellular carcinoma
- Joint project with Pediatric Surgery to create gastrojejunostomies and percutaneous jejunostomies using magnets
- Assessing the role of interventional radiology in managing complications related to the creation of ileal pouches following proctectomy
- Use of expandable metallic stents in the airways
- Joint project with Urology on RF ablation of small renal masses
- Assessing the safety of transdiaphragmatic drainages



Recent Key References:

Brandt-Zawadzki M, Kerlan RK Jr. Patient-centered radiology: use it or lose it! *Acad Radiol*. 2009 May;16(5):521-3.

Costouros NG, Niho H, Mahadevan U, Kerlan RK Jr, Bloom AI. Angiographic embolization for control of life-threatening hemorrhage from benign rectal ulcers. *J Vasc Interv Radiol*. 2009 Apr;20(4):561-2.

Yao FY, Kerlan RK Jr, Hirose R, Davern TJ 3rd, Bass NM, Feng S, Peters M, Terrault N, Freise CE, Ascher NL, Roberts JP. Excellent outcome following down-staging of hepatocellular carcinoma prior to liver transplantation: an intention-to-treat analysis. *Hepatology*. 2008 Sep;48(3):819-27.


Informatics and Image Processing/Display Specialized Resource Group

David E. Avrin, MD, PhD, Director

Research and Development Directions:

Our SRG initiated a number of exciting projects and both submitted and was awarded an abundance of grants this past year.

- **IDR:** The Vice Chancellor's Office for Information Technology is deploying an Integrated Data Repository (IDR) to facilitate translational bench-to-bedside research. The IDR will be populated with anonymous data from UCARE and other sources



such as ImageCast, with links to PACS studies and images. The research database project of Drs. Max Wintermark and Wyatt Tellis is being used as a proof-of-concept test case. The research database will be both a data source and a data consumer. The IDR is based on i2b2 multi-institutional collaborative concepts.

- **Research PACS:** As our research enterprise grows, with close collaboration between our imaging scientists and clinical sections through the RIG structure, and the need for HIPAA compliance, it has become clear that our Department needs an anonymous research PACS and other archive system, with re-identification capabilities. The Informatics and Image Processing SRG, in collaboration with members of several research groups, plans to deploy such a system this coming year.
- **Image Processing:** Several members of our SRG, notably Karl Young, PhD, and Colin Studholme, PhD, received NIH grants. Young works on statistical analysis of images, and Studholme on mapping to an anatomic model in the presence of motion.
- **RSNA Image Sharing Initiative:** We are one of five institutions listed as development and demonstration sites on a contract to be awarded to RSNA by NIBIB to develop a secure and usable web-based system for institutions to studies and images. Permission and authentication of patients and physicians would be achieved through web-based personal health records acting as a portal. We anticipate that this technology will obviate the need to create and transport CDs. Drs. Tellis and Avrin submitted RC-1 and RC-2 "challenge grants" in response to the Obama administration funding of health care information technology projects, based upon the to-be-developed RSNA technology. These projects address the need for multi-institutional research image sharing and UC-wide clinical image sharing.

Recent Key Publications:

Maudsley AA, Domenig C, Govind V, Darkazanli A, Studholme C, Arheart K, Bloomer C. Mapping of brain metabolite distributions by volumetric proton MR spectroscopic imaging (MRSI) *Magnetic Resonance in*

Medicine. Volume 61 Issue 3, March 2009, Pages 548-559.

Hadjidemetriou S, Studholme C, Mueller S, Weiner MW, Schuff N. Restoration of MRI data for intensity non-uniformities using local high order intensity statistics. *Medical Image Analysis*. Volume 13, Issue 1, February 2009, Pages 36-48.

Kornak J, Young K. K-Bayes Reconstruction for Perfusion MRI II: Modeling and Technical Development. *J Digit Imaging*. 2009 Mar 10. [Epub]

Kornak J, Young K, Schuff N, Du A, Maudsley AA, Weiner MW. K-Bayes Reconstruction for Perfusion MRI I: Concepts and Application. *J Digit Imaging*. 2009 Feb 10. [Epub]

Matson GB, Young K, Kaiser LG. RF pulses for *in vivo* spectroscopy at high field designed under conditions of limited power using optimal control. *J Magn Reson*. 2009 Jul;199(1):30-40

Yee J. CT colonography: techniques and applications. *Radiol Clin N Am*. 2009;47:133-145.

Additional references are available at www.radiology.ucsf.edu/bicg/publications/journals.

Margaret Hart Surbeck Laboratory of Advanced Imaging

Sarah J. Nelson, PhD, Director

Daniel B. Vigneron, PhD, Associate Director

Research Directions:

Development of high-field, 3 Tesla (3T) and 7 Tesla (7T) Magnetic Resonance (MR) techniques with improved sensitivity and specificity that more effectively address fundamental problems in biology and medicine, most notably:

- New algorithms for reconstructing spatial and temporal responses of biological systems and quantifying the resultant multi-dimensional and multi-spectral images
- New strategies for designing high-frequency RF coils and coil arrays that address electromagnetic problems and computational electromagnetism in *in vivo* MR at high fields using the FDTD and other finite element methods



- Applications of novel RF coil designs for *in vivo* MRI and spectroscopy
- Implementing parallel imaging strategies for anatomic, vascular, and spectroscopic imaging sequences in the musculoskeletal system, prostate, and brain
- Dynamic contrast-enhanced and perfusion-weighted imaging
- Phase and susceptibility-weighted imaging
- High-resolution angiography of neurovascular disease
- Developing faster, more reliable methods to acquire and process diffusion MRI
- Integrating studies on the human scanners with *ex vivo* analyses of tissue samples using high-resolution magic angle spinning NMR spectroscopy
- Improving and translating 3T MR spectroscopy sequences for prostate and brain in routine clinical use
- Applying and developing high-resolution MRI, MR spectroscopy, and MR diffusion imaging techniques at 7T
- Developing hyperpolarized C-13 agents and integrating novel data acquisition and analysis procedures
- Applying hyperpolarized C-13 metabolic imaging in cell systems and pre-clinical models to evaluate cancer and other diseases
- Developing new methods for hyperpolarized C-13 metabolic imaging in patients

Scientists in the Surbeck Lab continue to develop hands-on educational programs in high-field MR that are available to undergraduate and graduate students, medical students, and research fellows.

Recent Key References:

Albers MJ, Bok R, Chen AP, Cunningham CH, Zierhut ML, Zhang VY, Kohler SJ, Tropp Hurd RE, Yen YF, Nelson SJ, Vigneron DB, Kurhanewicz J. Hyperpolarized ¹³C lactate, pyruvate, and alanine: noninvasive biomarkers for prostate cancer detection and grading. *Cancer Res*. 2008 Oct 15;68(20):8607-15.

Hammond KE, Metcalf M, Carvajal L, Okuda DT, Srinivasan R, Vigneron D, Nelson SJ, Pelletier D. Quantitative *in vivo* magnetic resonance imaging of multiple sclerosis at 7 tesla with sensitivity to iron. *Ann Neurol*. 2008 Dec;64(6):707-13.

Hess CP. Update on diffusion tensor imaging in Alzheimer's disease. *Magn Reson Imaging Clin N Am*. 2009 May;17(2):215-24.

Krug R, Carballido-Gamio J, Banerjee S, Burghardt AJ, Link TM, Majumdar S. *In-vivo* ultra-high-field magnetic resonance imaging of trabecular bone micro-architecture at 7 tesla. *J Magn Reson Imaging*. 2008 Apr;27(4):854-9.

Larson PE, Kerr AB, Chen AP, Lustig MS, Zierhut ML, Hu S, Cunningham CH, Pauly JM, Kurhanewicz J, Vigneron DB. Multiband excitation pulses for hyperpolarized ¹³C dynamic chemical-shift imaging. *J Magn Reson*. 2008 Sep;194(1):121-7.

Von Morze C, Purcell DD, Banerjee S, Xu D, Mukherjee P, Kelley DA, Majumdar S, Vigneron DB. High-resolution intracranial MRA at 7T using autocalibrating parallel imaging: initial experience in vascular disease patients. *Magn Reson Imaging*. 2008 Dec;26(10):1329-33.

Wu B, Wang C, Krug R, Kelley D, Xu D, Banerjee, Vigneron D, Nelson S, Majumdar S, Zhang X. 7T human spine imaging arrays with adjustable inductive decoupling. *IEEE Trans Bio Med Eng*. 2009; 2009 Aug 25. [Epub]

MR/CT Contrast Agent Development Specialized Resource Group

Benjamin M. Yeh, MD, Co-Director

Michael F. Wendland, PhD, Co-Director

Research Directions:

Our overarching mission is to develop novel and useful contrast media and applications for contrast-enhanced imaging. Our strategies include developing novel methods for cell tracking, drug delivery, and treatment monitoring, and the refinement of pharmacokinetic modeling, quantitative imaging, and translational research. We seek to answer fundamental biomedical questions, including determining tumor-specific characteristics by developing and testing probes to assess tumor receptor status and microvessel leakiness.

Research directions are to develop:


- Imaging angiogenesis by use of macromolecular contrast material for CT and MRI to allow accurate assessment of microvessel permeability
- Human embryonic stem cell labeling with SPIO and fluorescent dyes for MRI and optical imaging
- Folate-receptor targeted contrast agents for imaging malignancy
- Novel applications of CT contrast materials
- Rat model of nephrogenic systemic fibrosis
- Dual-energy CT applications

References:

Boddington S, Henning TD, Sutton EJ, Daldrup-Link HE. Labeling stem cells with fluorescent dyes for non-invasive detection with optical imaging. *J Vis Exp*. 2008 Apr 2;(14). pii: 686. doi: 10.3791/686.

Henning TD, Wendland MF, Golovko D, Sutton EJ, Sennino B, Malek F, Bauer JS, McDonald DM, Daldrup-Link H. Relaxation effects of ferucarbotran-labeled mesenchymal stem cells at 1.5T and 3T: discrimination of viable from lysed cells. *Magn Reson Med*. 2009 Aug;62(2):325-32.

Raatschen HJ, Fu Y, Brasch RC, Pietsch H, Shames DM, Yeh BM. *In vivo* monitoring of angiogenesis inhibitory treatment effects by



dynamic contrast-enhanced computed tomography in a xenograft tumor model. *Invest Radiol*. 2009 May;44(5):265-70.

Sennino B, Raatschen HJ, Wendland MF, Fu Y, You WK, Shames DM, McDonald DM, Brasch RC. Correlative dynamic contrast MRI and microscopic assessments of tumor vascularity in RIP-Tag2 transgenic mice. *Magn Reson Med*. 2009 Sep;62(3):616-25.

Yeh BM, Shepherd JA, Wang ZJ, Teh HS, Hartman RP, Prevhal S. Dual-energy and low-kVp CT in the abdomen. *AJR Am J Roentgenol*. 2009 Jul;193(1):47-54.

MRI/MRS Specialized Resource Group

Daniel Vigneron, PhD, Director

Research Directions:

The MRI/MRS SRG works to advance MR imaging science to benefit the study of human disease. Studies include developing hardware and techniques to improve MR anatomic, diffusion, spectroscopic, hyperpolarized, perfusion, and high-field 3T and 7T imaging. We look at everything from developing new techniques and translating existing techniques, to improving the quality, speed, information content, applicability of advanced MR methods. This graphic depicts our approach:

Basic development=>Translation=>Optimization=>Validation

Our key missions are to:

- Be world leaders in cutting-edge MR techniques for studying human disease
- Collaborate with RIGS to translate basic science MR techniques into application studies for testing and optimization
- Work with clinical MRI to optimize and evaluate new techniques and improve state-of-the-art methods
- Train and educate all personnel in advanced MR techniques

Recent Key References:

Berman JI, Glass HC, Miller SP, Mukherjee P, Ferriero DM, Barkovich AJ, Vigneron DB, Henry RG. Quantitative fiber tracking analysis of the optic radiation correlated with visual performance in premature newborns. *AJNR Am J Neuroradiol*. 2009 Jan;30(1):120-4.

Chen AP, Tropp J, Hurd RE, Van Criekinge M, Carvajal LG, Xu D, Kurhanewicz J, Vigneron DB. *In vivo* hyperpolarized ¹³C MR spectroscopic imaging with ¹H decoupling. *J Magn Reson*. 2009 Mar;197(1):100-6.



Hope MD, Purcell DD, Hope TA, von Morze C, Vigneron DB, Alley MT, Dillon WP. Complete intracranial arterial and venous blood flow evaluation with 4D flow MR imaging. *AJNR Am J Neuroradiol*. 2009 Feb;30(2):362-6.

Lupo JM, Banerjee S, Hammond KE, Kelley DA, Xu D, Chang SM, Vigneron DB, Majumdar S, Nelson SJ. GRAPPA-based susceptibility-weighted imaging of normal volunteers and patients with brain tumor at 7 T. *Magn Reson Imaging*. 2009 May;27(4):480-8.

Martin AJ, Baek B, Acevedo-Bolton G, Higashida RT, Comstock J, Saloner DA. MR imaging during endovascular procedures: an evaluation of the potential for catheter heating. *Magn Reson Med*. 2009 Jan;61(1):45-53.

Osorio JA, Xu D, Cunningham CH, Chen A, Kerr AB, Pauly JM, Vigneron DB, Nelson SJ. Design of cosine modulated very selective suppression pulses for MR spectroscopic imaging at 3T. *Magn Reson Med*. 2009 Mar;61(3):533-40.

Tam EW, Ferriero DM, Xu D, Berman JI, Vigneron DB, Barkovich AJ, Miller SP. Cerebellar development in the preterm neonate: effect of supratentorial brain injury. *Pediatr Res*. 2009 Jul;66(1):102-6.

Wilson DM, Hurd RE, Keshari K, Van Criekinge M, Chen AP, Nelson SJ, Vigneron DB, Kurhanewicz J. Generation of hyperpolarized substrates by secondary labeling with [1,1-¹³C] acetic anhydride. *Proc Natl Acad Sci U S A*. 2009 Apr 7;106(14):5503-7.

Musculoskeletal and Quantitative Imaging Research Interest Group

Sharmila Majumdar, PhD, Co-Director

Thomas M. Link, MD, PhD, Co-Director

Research Directions:

- High-field and high-resolution MRI for quantitative characterization of the morphology and function of the musculoskeletal system
- Identification of biomarkers for degeneration in bone, cartilage, and inter-vertebral disc, and diseases such as osteoporosis, spinal disorders, and osteoarthritis
- MR spectroscopy methods for characterizing muscle in diabetes, HIV disease, and other diseases
- Strategies for non-invasive monitoring of cartilage and disc regeneration
- Microscopic characterization of bone, cartilage, disc, and other tissues, using methodologies such as computed tomography, Fourier Transform Infrared imaging, high-resolution NMR spectroscopy, and confocal laser microscopy
- Development of high-resolution, and quantitative computed tomography for characterizing bone geometry, micro-architecture, and density aimed at understanding aging, ethnic differences in the skeleton, osteoporosis, metal artifact reduction, and orthopedic implants

Recent Key References:

Carballido-Gamio J, Krug R, Huber MB, Hyun B, Eckstein F, Majumdar S, Link TM. Geodesic topological analysis of trabecular bone microarchitecture from high-spatial resolution magnetic



resonance images. *Magn Reson Med*. 2009 Feb;61(2):448-56.

Folkesson J, Krug R, Goldenstein J, Issever AS, Fang C, Link TM, Majumdar S. Evaluation of correction methods for coil-induced intensity inhomogeneities and their influence on trabecular bone structure parameters from MR images. *Med Phys*. 2009 Apr;36(4):1267-74.

Hellio Le Graverand MP, Buck RJ, Wyman BT, Vignon E, Mazzuca SA, Brandt KD, Piperno M, Charles HC, Hudelmaier M, Hunter DJ, Jackson C, Kraus VB, Link TM, Majumdar S, Prasad PV, Schnitzer TJ, Vaz A, Wirth W, Eckstein F. Subregional femorotibial cartilage morphology in women--comparison between healthy controls and participants with different grades of radiographic knee osteoarthritis. *Osteoarthritis Cartilage*. 2009 Sep;17(9):1177-85.

Issever AS, Link TM, Kentenich M, Rogalla P, Schwieger K, Huber MB, Burghardt AJ, Majumdar S, Diederichs G. Trabecular bone structure analysis in the osteoporotic spine using a clinical in vivo setup for 64-slice MDCT imaging: comparison to microCT imaging and microFE modeling. *J Bone Miner Res*. 2009 Sep;24(9):1628-37.

Keyak JH, Koyama AK, LeBlanc A, Lu Y, Lang TE. Reduction in proximal femoral strength due to long-duration spaceflight. *Bone*. 2009 Mar;44(3):449-53.

Li X, Pai A, Blumenkrantz G, Carballido-Gamio J, Link T, Ma B, Ries M, Majumdar S. Spatial distribution and relationship of T1rho and T2 relaxation times in knee cartilage with osteoarthritis. *Magn Reson Med*. 2009 Jun;61(6):1310-8.

Stahl R, Krug R, Kelley DA, Zuo J, Ma CB, Majumdar S, Link TM. Assessment of cartilage-dedicated sequences at ultra-high-field MRI: comparison of imaging performance and diagnostic confidence between 3.0 and 7.0 T with respect to osteoarthritis-induced changes at the knee joint. *Skeletal Radiol*. 2009 Aug;38(8):771-83.

Musculoskeletal Radiology

Thomas M. Link, MD, PhD, Chief

Research Directions:

Bone Marrow Imaging

- Monitoring the progress of the treatment of Gauchers disease

Cartilage and Osteoarthritis MR Imaging

- Imaging osteoarthritis-related changes in the Osteoarthritis Initiative incidence cohort
- Osteoarthritis and physical activity
- Cartilage imaging of marathoners and physically active subjects

- Optimizing MR protocols at 3T for the knee
- Assessing menisci with matrix-sensitive MRI sequences

High-field MRI for musculoskeletal applications

- *In vitro* and *in vivo* comparison of cartilage imaging at 1.5T, 3T, and 7T
- Comparing 1.5T with 3T MRI for the evaluation of smaller joints and the spine

Imaging of the Knee

- ACL grafts and popliteomeniscal fascicle tears with arthroscopic correlation

Imaging of the Shoulder

- Optimizing MRI for visualizing metal-on-metal surface replacements

MR Arthrography

- Evaluating the complications of MR arthrography

Osteoporosis Imaging

- Evaluating insufficiency fractures of the pelvis, CT vs. MRI
- Contrast-enhanced, multi-slice-spiral CT for assessing bone density and structure
- Diabetic bone disease and bone structure
- CT-based trabecular bone structure measures in relation to biomechanical strength and microCT
- CT and radiograph-based trabecular bone structure measures to predict implant failure in patients undergoing internal fixation of proximal femur fractures

New MRI techniques

- Use of CUBE and IDEAL sequences at 3T for imaging of the knee

Recent Key References:

Bauer JS, Barr C, Henning TD, Malfair D, Ma CB, Steinbach L, Link TM. Magnetic resonance imaging of the ankle at 3.0 Tesla and 1.5 Tesla in human cadaver specimens with artificially created lesions of cartilage and ligaments. *Invest Radiol*. 2008 Sep;43(9):604-11.

Chundru U, Riley GM, Steinbach LS. Magnetic resonance arthrography. *Radiol Clin North Am*. 2009 May;47(3):471-94. Review.

Daldrup-Link HE, Steinbach L. MR imaging of pediatric arthritis. *Magn Reson Imaging Clin N Am*. 2009 Aug;17(3):451-67, vi.

Link TM. MR imaging in osteoarthritis: hardware, coils, and sequences. *Radiol Clin North Am*. 2009 Jul;47(4):617-32.



Rauscher I, Stahl R, Cheng J, Li X, Huber MB, Luke A, Majumdar S, Link TM. Meniscal measurements of T1rho and T2 at MR imaging in healthy subjects and patients with osteoarthritis. *Radiology*. 2008 Nov;249(2):591-600.

Ristow O, Steinbach L, Sabo G, Krug R, Huber M, Rauscher I, Ma B, Link TM. Isotropic 3D fast spin-echo imaging versus standard 2D imaging at 3.0 T of the knee--image quality and diagnostic performance. *Eur Radiol*. 2009 May;19(5):1263-72.

Wong S, Steinbach L, Zhao J, Stehling C, Ma CB, Link TM. Comparative study of imaging at 3.0 T versus 1.5 T of the knee. *Skeletal Radiol*. 2009 Aug;38(8):761-9.

Neurodegenerative Diseases Research Interest Group

Norbert Schuff, PhD, Co-Director
Michael Weiner, MD, Co-Director

Research Directions:

- Studying the causes and effects of neurodegenerative and psychiatric disorders, using MRI as a surrogate marker
- Developing powerful, new brain MR techniques for early detection, improved diagnosis, and assessment of therapeutic interventions of neurodegenerative and psychiatric disorders
- Developing multimodal brain image processing and imaging statistical analysis techniques
- Highlights include:
 - Ultra-high resolution structural MRI
 - Diffusion spectrum imaging
 - Dynamic, arterial-spin-labeling imaging
 - Susceptibility-weighted imaging
 - Spectroscopic imaging and j-modulated spectroscopy
 - Bayesian image reconstruction
 - Multivariate image analysis methods
 - Standards for imaging neurodegenerative diseases that can be transferred into clinical practice and multi-center clinical trials

Recent Key References:

Durazzo TC, Gazdzinski S, Yeh PH, Meyerhoff DJ. Combined neuroimaging, neurocognitive and psychiatric factors to predict alcohol consumption following treatment for alcohol dependence. *Alcohol Alcohol*. 2008 Nov-Dec;43(6):683-91.

Meyerhoff DJ, Durazzo TC. Proton magnetic resonance spectroscopy in alcohol use disorders: a potential new endophenotype? *Alcohol Clin Exp Res*. 2008 Jul;32(7):1146-58.

Mueller SG, Laxer KD, Barakos J, Cheong I, Garcia P, Weiner MW. Subfield atrophy pattern in temporal lobe epilepsy with and without mesial sclerosis detected by high-resolution MRI at 4 Tesla: preliminary results. *Epilepsia*. 2009 Jun;50(6):1474-83.

Schuff N, Woerner N, Boreta L, Kornfield T, Shaw LM, Trojanowski JQ, Thompson PM, Jack CR Jr, Weiner MW. Alzheimer's Disease Neuroimaging Initiative. MRI of hippocampal volume loss in early Alzheimer's disease in relation to ApoE genotype and biomarkers. *Brain*. 2009 Apr;132(Pt 4):1067-77.

Young K, Du AT, Kramer J, Rosen H, Miller B, Weiner M, Schuff N. Patterns of structural complexity in Alzheimer's disease and

frontotemporal dementia. *Hum Brain Mapp*. 2009 May;30(5):1667-77.

Zhan W, Zhang Y, Mueller SG, Lorenzen P, Hadjideometriou S, Schuff N, Weiner MW. Characterization of white matter degeneration in elderly subjects by magnetic resonance diffusion and FLAIR imaging correlation. *Neuroimage*. 2009 Aug;47 Suppl 2:T58-65.

Zhang Y, Schuff N, Du AT, Rosen HJ, Kramer JH, Gorno-Tempini ML, Miller BL, Weiner MW. White matter damage in frontotemporal dementia and Alzheimer's disease measured by diffusion MRI. *Brain*. 2009 Sep;132(Pt 9):2579-92.

Neuroradiology

William P. Dillon, MD, Chief

Research Directions:

Neuropediatrics

- Cause of cerebellar hypoplasia in some prematurely born neonates
- Effects of brain cooling on CNS injury in term neonates suffering hypoxic-ischemic injury
- Embryogenesis of disorders of the midbrain and hindbrain
- Normal and abnormal development of the cerebral cortex
- Fetal MR Neuroimaging: development and application of advanced MRI techniques to study normal and abnormal fetal brain development

Traumatic brain injury

- Diffusion tensor imaging (DTI) and fiber tractography, functional MRI (fMRI), 3D MR spectroscopic imaging (MRSI), and deformation morphometry as imaging biomarkers for mild TBI to predict clinical outcomes in post-concussive syndrome, with correlation to neurocognitive testing and genomic analysis for TBI susceptibility genes such as ApoE
- DTI and fiber tractography processing for a multi-center consortium study of mild TBI

Cardiovascular disease and stroke

- Use of 64-slice CT in the detection of cardiovascular disease and stroke
- Functional mapping and scoring system for predicting the outcome of ischemic stroke
- Use of perfusion and CTA imaging to detect ongoing hemorrhages in the brain of patients presenting with acute intracerebral hematoma
- Use of permeability image mapping to detect stroke patients at risk of subsequent hemorrhage
- Automated software for the outcome classification of patients with acute subarachnoid hemorrhage



Brain tumors

- Use of permeability and perfusion imaging to guide operative biopsy
- Correlation of genetic markers and imaging markers from tissue obtained by image-guided biopsy

Head and neck

- The utility of PET/CT in follow-up of patients with head and neck cancer
- The use of advanced imaging techniques in the detection of recurrent head and neck cancer

Spine

- CT-guided back pain management
- The use of image guidance to improve the accuracy of injections
- Utility of gadolinium MR myelography to detect CSF leaks
- MR neurography for peripheral nerve diagnosis

Neurodegenerative Diseases

- New imaging biomarkers for neurodegenerative diseases using 7T MRI
- 7T imaging of patients with intractable epilepsy
- Characterization of multimodal diffusion data using high angular, resolution-diffusion imaging

Recent Key References:

Guerrini R, Dobyns WB, Barkovich AJ. Abnormal development of the human cerebral cortex: genetics, functional consequences and treatment options. *Trends Neurosci.* 2008 Mar;31(3):154-62.

Jissendi-Tchofo P, Doherty D, McGillivray G, Hevner R, Shaw D, Ishak G, Leventer R, Barkovich AJ. Pontine tegmental cap dysplasia: MR imaging and diffusion tensor imaging features of impaired axonal navigation. *AJNR Am J Neuroradiol.* 2009 Jan;30(1):113-9.

Kim JJ, Dillon WP, Glastonbury CM, Provenzale JM, Wintermark M. Sixty-Four-Section Multidetector CT Angiography of Carotid Arteries: A Systematic Analysis of Image Quality and Artifacts. *AJNR Am J Neuroradiol.* 2009 Sep 3. [Epub]

Le TH, Gean AD. Neuroimaging of traumatic brain injury. *Mt Sinai J Med.* 2009 Apr;76(2):145-62.

Nakata Y, Barkovich AJ, Wahl M, Strominger Z, Jeremy RJ, Wakahiro M, Mukherjee P, Sherr EH. Diffusion abnormalities and reduced volume of the ventral cingulum bundle in agenesis of the corpus callosum: a 3T imaging study. *AJNR Am J Neuroradiol.* 2009 Jun;30(6):1142-8.

Wahl M, Strominger Z, Jeremy RJ, Barkovich AJ, Wakahiro M, Sherr EH, Mukherjee P. Variability of homotopic and heterotopic callosal connectivity in partial agenesis of the corpus callosum: a 3T diffusion tensor imaging and Q-ball tractography study. *AJNR Am J Neuroradiol.* 2009 Feb;30(2):282-9.

Neurovascular/Neurointerventional Research Interest Group

David Saloner, PhD, Director

Research Directions:

The Neurovascular/NIR RIG aims to use state-of-the-art imaging in monitoring the evolution of vascular disease; in assessing the delivery and efficacy of image-guided interventions and of medical therapies; and in improving the selection of stroke patients for acute reperfusion therapy.

Recent Key References:

Arora S, Chien JD, Cheng SC, Chun KA, Wintermark M. Optimal carotid artery coverage for carotid plaque CT-imaging in predicting ischemic stroke. *J Neuroradiol.* 2009 Jun 30.



Boussel L, Arora S, Rapp J, Rutt B, Huston J, Parker D, Yuan C, Bassiouny H, Saloner D; MAPP Investigators. Atherosclerotic plaque progression in carotid arteries: monitoring with high-spatial-resolution MR imaging – multicenter trial. *Radiology.* 2009 Sep;252(3):789-96.

Boussel L, Rayz V, Martin A, Acevedo-Bolton G, Lawton MT, Higashida R, Smith WS, Young WL, Saloner D. Phase-contrast magnetic resonance imaging measurements in intracranial aneurysms *in vivo* of flow patterns, velocity fields, and wall shear stress: comparison with computational fluid dynamics. *Magn Reson Med.* 2009 Feb;61(2):409-17.

Hetts SW, Narvid J, Sanai N, Lawton MT, Gupta N, Fullerton HJ, Dowd CF, Higashida RT, Halbach VV. Intracranial aneurysms in childhood: 27-year single-institution experience. *AJNR Am J Neuroradiol.* 2009 Aug;30(7):1315-24.

Soares BP, Dankbaar JW, Bredno J, Cheng S, Bhogal S, Dillon WP, Wintermark M. Automated versus manual post-processing of perfusion-CT data in patients with acute cerebral ischemia: influence on interobserver variability. *Neuroradiology.* 2009 Jul;51(7):445-51.

Nuclear Medicine

Randall A. Hawkins, MD, PhD, Chief


Research Directions:

Cardiac and vascular applications of clinical SPECT-CT, PET, and PET-CT:

- Applications of SPECT-CT for cardiac synchrony
- Dementia imaging with SPECT-CT
- Clinical PET and PET-CT studies of cancer, cardiovascular, and neurological diseases
- Feasibility of PET and MRI to characterize myocardial metabolism and flow
- Use of PET in monitoring therapy for breast and ovarian cancers
- Conformal radiation treatment planning with PET-CT
- Imaging structure and function in small animals with CT/SPECT
- Molecular probe development for SPECT and PET

Key Recent References:

Botvinick EH. Current methods of pharmacologic stress testing and the potential advantages of new agents. *J Nucl Med Technol.* 2009 Mar;37(1):14-25. Review.



Daldrup-Link HE, Hawkins RA, Meier R, Goldsby RE, Artemov D. Receptor imaging of pediatric tumors: clinical practice and new developments. *Pediatr Radiol.* 2008 Nov;38(11):1154-61

Iagaru A, Wang Y, Mari C, Quon A, Goris ML, Horning S, Gambhir SS. (18)F-FDG-PET/CT evaluation of response to treatment in lymphoma: when is the optimal time for the first re-evaluation scan? *Hell J Nucl Med.* 2008 Sep-Dec;11(3):153-6.

Matthay KK, Quach A, Huberty J, Franc BL, Hawkins RA, Jackson H, Groshen S, Shusterman S, Yanik G, Veatch J, Brophy P, Villablanca JG, Maris JM. Iodine-131--metaiodobenzylguanidine double infusion with autologous stem-cell rescue for neuroblastoma: a new approaches to neuroblastoma therapy phase I study. *J Clin Oncol.* 2009 Mar 1;27(7):1020-5.


Nuclear-Optical Specialized Resource Group

Henry F. VanBrocklin, PhD, Director

Research Directions:

- Developing targeted nanoparticles for early pancreatic cancer detection
- Evaluating molecular probes for mesothelioma imaging
- Preparing phosphoramidate imaging agents for prostate cancer
- Identifying breast cancer pre-malignancy with molecular probes
- Noninvasive detection of heart transplant rejection with molecular probes
- Characterizing atherosclerotic plaques
- Hypoxia as a biomarker for tuberculosis and breast cancer
- Developing an automated system for the preparation of fluorine-18 fluorine gas for PET radiochemistry
- Developing quantitative, multi-pinhole SPECT/CT technology for highly sensitive, targeted volume imaging
- Quantitative SPECT/CT and PET/CT imaging of prostate cancer using molecular probes
- Developing a patient-specific, pre-therapy dosimetry tool for targeted radiotherapy of neuroblastoma
- Developing quantitative dynamic SPECT/CT and PET/CT techniques for myocardial perfusion imaging

- Developing dual isotope, simultaneous acquisition of myocardial perfusion imaging
- Developing novel radionuclide detector technologies for small animal imaging
- Developing quantitative dynamic imaging techniques for microPET/CT imaging of cardiovascular and cancer research
- Molecular imaging of metastatic lymph nodes in breast cancer
- Preparing tungsten-based nanomaterials for imaging applications
- Tracking distribution of labeled stem cells targeting the myocardium and assessment of their physiologic effects on myocardial perfusion and function
- Evaluating a fluorine-18-labeled probe to image Alzheimer's plaques
- Imaging NMDA receptors related to MS and Lupus



Recent Key References:

Bidlingmaier S, He J, Wang Y, An F, Feng J, Barbone D, Gao D, Franc B, Broadus VC, Liu B. Identification of MCAM/CD146 as the target antigen of a human monoclonal antibody that recognizes both epithelioid and sarcomatoid types of mesothelioma. *Cancer Res.* 2009 Feb 15;69(4):1570-7.

Huang Q, Xu J, Tsui BM, Gullberg GT. Reconstructing uniformly attenuated rotating slant-hole SPECT projection data using the DBH method. *Phys Med Biol.* 2009 Jul 7;54(13):4325-39.

Pan MH, Gao DW, Feng J, He J, Seo Y, Tedesco J, Wolodzko JG, Hasegawa BH, Franc BL. Biodistributions of ¹⁷⁷Lu- and ¹¹¹In-labeled 7E11 antibodies to prostate-specific membrane antigen in xenograft model of prostate cancer and potential use of ¹¹¹In-7E11 as a pre-therapeutic agent for ¹⁷⁷Lu-7E11 radioimmunotherapy. *Mol Imaging Biol.* 2009 May-Jun;11(3):159-66.

Watkins GA, Jones EF, Scott Shell M, VanBrocklin HF, Pan MH, Hanrahan SM, Feng JJ, He J, Sounni NE, Dill KA, Contag CH, Coussens LM, Franc BL. Development of an optimized activatable MMP-14 targeted SPECT imaging probe. *Bioorg Med Chem.* 2009 Jan 15;17(2):653-9.

Winant C, Mari Aparici C, Bacharach S, Reutter BW, Sitek A, Gullberg GT. Analysis of dynamic SPECT-CT measurements of the arterial input function in human subjects. In: Sellin P ed. Conference Record of 2008 IEEE nuclear science symposium held at Dresden, Germany, October 19 – October 25, 2008. *IEEE Nuclear & Plasma Sciences Society.*

Pediatric Radiology

Heike E. Daldrop-Link, MD, PhD, Interim Chief

Research Directions:

The Pediatric Radiology section is involved in research projects investigating new imaging technologies for pediatric patients, in particular new applications of magnetic resonance imaging and PET-CT, as well as collaborative research projects involving pediatric oncology, gastroenterology, and surgery.

- Evaluating whole body MRI for staging of children with solid tumors
- Assessing criteria for the differentiation of normal thymus and malignant anterior mediastinal masses in pediatric patients on PET/CT studies
- Evaluating the diagnostic accuracy of MR enterography in the detection of inflammatory bowel disease; correlation of imaging findings with endoscopy
- Serving as expert reviewers for CT and MRI studies of patients with advanced neuroblastoma for the consortium New Approaches to Neuroblastoma Therapy
- Serving as reviewers for a project of UCSF pediatric surgeons on the safety and efficacy of a Magnetic Mini-Mover in correcting pectus excavatum deformities in pediatric patients

Recent Key References:

Daldrop-Link HE, Hawkins RA, Meier R, Goldsby RE, Artemov D. Receptor imaging of pediatric tumors: clinical practice and new developments. *Pediatr Radiol*. 2008 Nov;38(11):1154-61

Daldrop-Link HE, Steinbach L. MR imaging of pediatric arthritis. *Magn Reson Imaging Clin N Am*. 2009 Aug;17(3):451-67

Jha P, Chawla SC, Tavri S, Patel C, Gooding C, Daldrop-Link H. Pediatric liver tumors--a pictorial review. *Eur Radiol*. 2009 Jan;19(1):209-19

Kleis M, Daldrop-Link H, Matthay K, Goldsby R, Lu Y, Schuster T, Schreck C, Chu PW, Hawkins RA, Franc BL. Diagnostic value of PET/CT for the staging and restaging of pediatric tumors. *Eur J Nucl Med Mol Imaging*. 2009 Jan;36(1):23-36

Wagner LM, Villablanca JG, Stewart CF, Crews KR, Groshen S, Reynolds CP, Park JR, Maris JM, Hawkins RA, Daldrop-Link HE, Jackson HA, Matthay KK. Phase I trial of oral irinotecan and temozolomide for children with relapsed high-risk neuroblastoma: a new approach to neuroblastoma therapy consortium study. *J Clin Oncol*. 2009 Mar 10;27(8):1290-6.



Pediatric/Fetal Research Interest Group

A. James Barkovich, MD, Director

Research Directions:

- Developing new imaging techniques to assess normal and abnormal development, including MRSI and DTI
- Developing new technology for imaging fetuses and neonates and adapting state-of-the-art techniques for application in the developing fetus and infant
- Using imaging techniques to diagnose and study malformations of the brain
- Using imaging to assess injury in premature and term neonates
- Using imaging to assess new therapies for injured fetuses and neonates
- Using imaging to assess brain injury in neonates and infants with severe congenital heart disease

Recent Key References:

Berman JI, Glass HC, Miller SP, Mukherjee P, Ferriero DM, Barkovich AJ, Vigneron DB, Henry RG. Quantitative fiber tracking analysis of the optic radiation correlated with visual performance in premature newborns. *AJNR Am J Neuroradiol*. 2009 Jan;30(1):120-4.

Jissendi-Tchofo P, Kara S, Barkovich AJ. Midbrain-hindbrain involvement in lissencephalies. *Neurology*. 2009 Feb 3;72(5):410-8.

Tam EW, Ferriero DM, Xu D, Berman JI, Vigneron DB, Barkovich AJ, Miller SP. Cerebellar development in the preterm neonate: effect of supratentorial brain injury. *Pediatr Res*. 2009 Jul;66(1):102-6.

Tang PH, Bartha AI, Norton ME, Barkovich AJ, Sherr EH, Glenn OA. Agenesis of the corpus callosum: an MR imaging analysis of associated abnormalities in the fetus. *AJNR Am J Neuroradiol*. 2009 Feb;30(2):257-63.

Schneider MM, Berman JI, Baumer FM, Glass HC, Jeng S, Jeremy RJ, Esch M, Biran V, Barkovich AJ, Studholme C, Xu D, Glenn OA. Normative Apparent Diffusion Coefficient Values in the Developing Fetal Brain. *AJNR Am J Neuroradiol*. 2009 Jul 23. [Epub]

Prostate Cancer Research Interest Group

John Kurhanewicz, PhD, Co-Director

Fergus V. Coakley, MD, Co-Director

Research Directions:

- Developing an optimized and clinically feasible multiparametric MR protocol for prostate cancer and diseases of the liver
- Rigorous histopathological correlative studies for validation of MR biomarkers
- Developing ways to analyze multiparametric imaging data
- Developing clinical predictive nomograms that incorporate imaging variables
- Image-guided biopsy and therapy
- Identifying, validating and implementing robust, quantitative, noninvasive magnetic-resonance-based

metabolomic biomarkers of human disease and therapeutic response using *ex vivo* tissues, biofluids, and preclinical cell and murine models of human disease

- Developing targeted contrast agents for prostate cancer and other diseases
- Developing and implementing hyperpolarized ¹³C magnetic resonance spectroscopic imaging in prostate cancer patients

Recent References:

Levin YS, Albers MJ, Butler TN, Spielman D, Peehl DM, Kurhanewicz J. Methods for metabolic evaluation of prostate cancer cells using proton and (¹³C) HR-MAS spectroscopy and [³-(¹³C)] pyruvate as a metabolic substrate. *Magn Reson Med*. 2009 Sep 24. [Epub]

Lupo JM, Chen AP, Zierhut ML, Bok RA, Cunningham CC, Kurhanewicz J, Vigneron DB, Nelson SJ. Analysis of hyperpolarized dynamic (¹³C) lactate imaging in a transgenic mouse model of prostate cancer. *Magn Reson Imaging*. 2009 Aug 18. [Epub]

Weinreb JC, Blume JD, Coakley FV, Wheeler TM, Cormack JB, Sotito CK, Cho H, Kawashima A, Tempny-Afdhal CM, Macura KJ, Rosen M, Gerst SR, Kurhanewicz J. Prostate cancer: sextant localization at MR imaging and MR spectroscopic imaging before prostatectomy--results of ACRIN prospective multi-institutional clinicopathologic study. *Radiology*. 2009 Apr;251(1):122-33.

Westphalen AC, Kurhanewicz J, Cunha RM, Hsu IC, Kornak J, Zhao S, Coakley FV. T2-Weighted endorectal magnetic resonance imaging of prostate cancer after external beam radiation therapy. *Int Braz J Urol*. 2009 Mar-Apr;35(2):171-80; discussion 181-2.

Westphalen AC, Coakley FV, Kurhanewicz J, Reed G, Wang ZJ, Simko JP. Mucinous adenocarcinoma of the prostate: MRI and MR spectroscopy features. *AJR Am J Roentgenol*. 2009 Sep;193(3):W238-43.

San Francisco General Hospital

Mark W. Wilson, MD, Chief

Research Directions:

- Imaging evaluation of pulmonary embolism, particularly the ability of CT pulmonary angiography to predict outcomes in patients with pulmonary embolism
- Utility of imaging for diagnosis in AIDS patients
- Functional evaluation of pulmonary nodules in patients with suspected lung carcinoma, imaging of mesothelioma
- Imaging recurrent pyogenic cholecystitis and cholangitis
- Imaging trauma to the spine and spinal cord, chest, abdomen, and extremities
- Exploring MR sequences before and after gadolinium for focal hepatic lesions
- Neutral versus positive oral contrast in abdominal imaging
- Evaluating and maintaining atypical dialysis access grafts and fistulas

- Outcomes of transcatheter embolization for treatment of hemorrhagic complications of pregnancy termination
- Evaluating evolving techniques for transcatheter embolization for pelvic trauma
- Magnetic catheter manipulation in the MRI environment
- Proliferation of ultrasound in underdeveloped countries
- Global health care initiatives
- Internet applications in radiology
- Evaluating patterns of infection by atypical mycobacteria
- Evaluating HRCT features of interstitial lung disease in the setting of hypersensitivity pneumonitis
- Imaging and computer-aided assessment of traumatic brain injury
- Optimizing hepatic MRI and CT imaging parameters
- Transcatheter treatment of pelvic hemorrhage: post-traumatic, post-partum, and post-abortion



Recent Key References:

Chang SD, Thoeni RF. Effect of T1 shortening on T2-weighted MRI sequences: comparison of hepatic mass conspicuity on images acquired before and after gadolinium enhancement. *AJR Am J Roentgenol*. 2008 May;190(5):1318-23.

Le TH, Gean AD. Neuroimaging of traumatic brain injury. *Mt Sinai J Med*. 2009 Apr;76(2):145-62. Review.

Steinauer JE, Diedrich JT, Wilson MW, Darney PD, Vargas JE, Drey EA. Uterine artery embolization in postabortion hemorrhage. *Obstet Gynecol*. 2008 Apr;111(4):881-9.

Yuh EL, Gean AD, Manley GT, Callen AL, Wintermark M. Computer-aided assessment of head computed tomography (CT) studies in patients with suspected traumatic brain injury. *J Neurotrauma*. 2008 Oct;25(10):1163-72.

Ultrasound

Ruth B. Goldstein, MD, Chief

Research Directions:

- Prenatal diagnosis of CNS anomalies with ultrasound and MRI
- Further investigation of clinical manifestations and treatment of twin transfusion syndrome

- Prospective, randomized trial of repair of fetal myelomeningocele
- Prospective, randomized trial for selective ablation of connecting vessels in twin transfusion syndrome



Recent Key References:

Aziz S, Chopra R, Anton T, D'Agostini D, Pretorius D. "Clinical Applications of Three-Dimensional Sonography in Obstetrics". *Maternal Fetal Medicine, Sixth Edition*, Ed. by Creasy and Resnik; Saunders and Elsevier Inc.

Callen PW, Callen AL, Glenn OA, Toi A. Columns of the fornix, not to be mistaken for the cavum septi pellucidum on prenatal sonography. *J Ultrasound Med.* 2008 Jan;27(1):25-31.

Cho RC, Chu P, Smith-Bindman R. Second trimester prenatal ultrasound for the detection of pregnancies at increased risk of Trisomy 18 based on serum screening. *Prenat Diagn.* Feb 2009;29(2):129-139.

Glass HC, Bonifacio SL, Sullivan J, Rogers E, Ferriero DM, Goldstein R, Barkovich AJ. Magnetic resonance imaging and ultrasound injury in preterm infants with seizures. *J Child Neurol.* 2009 Sep;24(9):1105-11.

Kuppermann M, Norton ME, Gates E, Gregorich SE, Learman LA, Nakagawa S, Feldstein VA, Lewis J, Washington AE, Nease RF Jr. Computerized prenatal genetic testing decision-assisting tool: a randomized controlled trial. *Obstet Gynecol.* 2009 Jan;113(1):53-63.

Sippel RS, Elaraj DM, Poder L, Duh QY, Kebebew E, Clark OH. Localization of recurrent thyroid cancer using intraoperative ultrasound-guided dye injection. *World J Surg.* 2009 Mar;33(3):434-9.


Wong SK, Barkovich AJ, Callen AL, Filly RA. Supratentorial abnormalities in the Chiari II malformation: III. The interhemispheric cyst. *J Ultrasound Med.* 2009 Aug;28(8):999-1006.

Veterans Affairs Medical Center

Judy Yee, MD, Chief

Research Directions:

- Reduced cathartic and non-cathartic CT colonography



- Assessment of Bone Mineral Density on CT colonography
- Diagnosis of osteoporotic spine fractures with Multi-detector CT
- The National CT Colonography Trial: assessment of accuracy in participants age 65 and older
- Computed tomography evaluation of imaging features that predict variceal hemorrhage
- Dual-energy and low kVp CT imaging
- Dynamic contrast enhanced (perfusion) imaging in the abdomen and pelvis
- Novel applications of CT and MR contrast timing and delivery in the abdomen and pelvis

Recent Key References:

Baxter S, Wang ZJ, Joe BN, Qayyum A, Taouli B, Yeh BM. Timing bolus dynamic contrast-enhanced (DCE) MRI assessment of hepatic perfusion: Initial experience. *J Magn Reson Imaging.* 2009 Jun;29(6):1317-22.

Chang TT, Sawhney R, Monto A, Davoren BJ, Kirkland JG, Stewart L, Corvera CU. Implementation of a multidisciplinary treatment team for hepatocellular cancer at a Veterans Affairs Medical Center improves survival. *HPR (Oxford)* 2008;10:405-411.

Johnson CD, Chen MH, Toledano AY, Heiken JP, Limburg PJ, Dachman A, Kuo MD, Menias C, Fidler JL, Cheema JI, Coakley K, Iyer RB, Horton KM, Siewart B, Obregon RG, Zimmerman P, Hara AK, Halvorsen RA, Yee J, Casola G, Herman BA, Burgart LJ. The national CT colonography trial: multicenter assessment of accuracy for detection of large adenomas and cancers. *N Engl J Med.* 2008 Sep 18;359(12):1207-17.

Taylor SA, Charman SC, Lefere P, McFarland EG, Paulson EK, Yee J, Aslam R, Barlow JM, Gupta A, Kim DH, Miller CM, Halligan S. CT colonography: investigation of the optimum reader paradigm by using computer-aided detection software. *Radiology.* 2008 Feb;246(2):463-71.

Yee J. CT colonography: techniques and applications. *Radiol Clin North Am.* 2009 Jan;47(1):133-45.

Yeh BM, Shepherd JA, Wang ZJ, Teh HS, Hartman RP, Prevhal S. Dual-energy and low-kVp CT in the abdomen. *AJR Am J Roentgenol.* 2009 Jul;193(1):47-54.

Zhang LJ, Zhao YE, Wu SY, Yeh BM, Zhou CS, Hu XB, Hu QJ, Lu GM. Pulmonary embolism detection with dual-energy CT: experimental study of dual-source CT in rabbits. *Radiology.* 2009 Jul;252:61-70.

Center for Imaging of Neurodegenerative Diseases

Michael W. Weiner, MD, Director

Research Directions:

- Studying the causes and effects of neurodegenerative and psychiatric disorders, using MRI as a surrogate marker
- Developing powerful, new brain MR techniques for early detection, improved diagnosis, and assessment of therapeutic interventions of neurodegenerative and psychiatric disorders
- Developing multimodal brain image processing and imaging statistical analysis techniques
- Highlights include:



Vascular Imaging Research Center

David Saloner, PhD, Director

Research Directions:

- Ultra-high resolution structural MRI
 - Diffusion spectrum imaging
 - Dynamic, arterial-spin-labeling imaging
 - Susceptibility-weighted imaging
 - Spectroscopic imaging and j-modulated spectroscopy
 - Bayesian image reconstruction
 - Multivariate image analysis methods
 - Standards for imaging neurodegenerative diseases that can be transferred into clinical practice and multi-center clinical trials
- Implementation of advanced post-processing methods in the analysis of atherosclerotic disease
 - Development of methods for visualization of complex flow in intracranial aneurysms
 - Assessment of thromboembolism in a murine model
 - Analysis of plaque vulnerability using patient-specific image-based computational methods
 - Development of 4-D MRI methods for determination of valvular function

Recent Key References:

Durazzo TC, Gazdzinski S, Yeh PH, Meyerhoff DJ. Combined neuroimaging, neurocognitive and psychiatric factors to predict alcohol consumption following treatment for alcohol dependence. *Alcohol Alcohol.* 2008 Nov-Dec;43(6):683-91.

Meyerhoff DJ, Durazzo TC. Proton magnetic resonance spectroscopy in alcohol use disorders: a potential new endophenotype? *Alcohol Clin Exp Res.* 2008 Jul;32(7):1146-58.

Mueller SG, Laxer KD, Barakos J, Cheong I, Garcia P, Weiner MW. Subfield atrophy pattern in temporal lobe epilepsy with and without mesial sclerosis detected by high-resolution MRI at 4 Tesla: preliminary results. *Epilepsia.* 2009 Jun;50(6):1474-83.

Schuff N, Woerner N, Boreta L, Kornfield T, Shaw LM, Trojanowski JQ, Thompson PM, Jack CR Jr, Weiner MW; Alzheimer's Disease Neuroimaging Initiative. MRI of hippocampal volume loss in early Alzheimer's disease in relation to ApoE genotype and biomarkers. *Brain.* 2009 Apr;132(Pt 4):1067-77.

Young K, Du AT, Kramer J, Rosen H, Miller B, Weiner M, Schuff N. Patterns of structural complexity in Alzheimer's disease and frontotemporal dementia. *Hum Brain Mapp.* 2009 May;30(5):1667-77.

Zhan W, Zhang Y, Mueller SG, Lorenzen P, Hadjide metriou S, Schuff N, Weiner MW. Characterization of white matter degeneration in elderly subjects by magnetic resonance diffusion and FLAIR imaging correlation. *Neuroimage.* 2009 Aug;47 Suppl 2:T58-65.

Zhang Y, Schuff N, Du AT, Rosen HJ, Kramer JH, Gorno-Tempini ML, Miller BL, Weiner MW. White matter damage in frontotemporal dementia and Alzheimer's disease measured by diffusion MRI. *Brain.* 2009 Sep;132(Pt 9):2579-92.



Recent Key References:

Carlsson M, Martin AJ, Ursell PC, Saloner D, Saeed M. Magnetic resonance imaging quantification of left ventricular dysfunction following coronary microembolization. *Magn Reson Med.* 2009 Mar;61(3):595-602.

Boussel L, Arora S, Rapp J, Rutt B, Huston J, Parker D, Yuan C, Bassiouny H, Saloner D; MAPP Investigators. Atherosclerotic plaque progression in carotid arteries: monitoring with high-spatial-resolution MR imaging--multicenter trial. *Radiology.* 2009 Sep;252(3):789-96.

Boussel L, Rayz V, Martin A, Acevedo-Bolton G, Lawton MT, Higashida R, Smith WS, Young WL, Saloner D. Phase-contrast magnetic resonance imaging measurements in intracranial aneurysms in vivo of flow patterns, velocity fields, and wall shear stress: comparison with computational fluid dynamics. *Magn Reson Med.* 2009 Feb;61(2):409-17.

Fukaya E, Saloner D, Leon P, Wintermark M, Grossman RF, Nozaki M. Magnetic resonance angiography to evaluate septocutaneous perforators in free fibula flap transfer. *J Plast Reconstr Aesthet Surg.* 2009 Jul 4. [Epub]

Martin AJ, Baek B, Acevedo-Bolton G, Higashida RT, Comstock J, Saloner DA. MR imaging during endovascular procedures: an evaluation of the potential for catheter heating. *Magn Reson Med.* 2009 Jan;61(1):45-53.

Women's Imaging

Bonnie N. Joe, MD, PhD, Chief

Research Directions:

- MRI, optical imaging, and X-ray mammography for breast cancer screening and surveillance, diagnosis and tissue characterization for risk assessment, cancer staging, and treatment response assessment
- New techniques in MRI-guided biopsy and imaging protocols
- Quantitative assessment of breast density and breast cancer risk models
- Digital breast tomosynthesis
- MRI/MRS for assessing tumor response to neo-adjuvant chemotherapy for patients with locally advanced breast cancer
- MR spectroscopy for biomarker development in breast cancer and fetal maturity applications

Recent Key References:

Joe BN, Vahidi K, Zektzer A, Chen MH, Clifton MS, Butler T, Keshari K, Kurhanewicz J, Coakley F, Swanson MG. (1)H HR-MAS spectroscopy for quantitative measurement of choline concentration in amniotic fluid as a marker of fetal lung maturity: inter- and intraobserver reproducibility study. *J Magn Reson Imaging*. 2008 Dec;28(6):1540-1545.

Kim DH, Vahidi K, Caughey AB, Coakley FV, Vigneron DB, Kurhanewicz J, Mow B, Joe BN. In vivo (1)H magnetic resonance spectroscopy of amniotic fluid and fetal lung at 1.5 T: technical challenges. *J Magn Reson Imaging*. 2008 Oct;28(4):1033-1038.

Li KL, Partridge SC, Joe BN, Gibbs JE, Lu Y, Esserman LJ, Hylton NM. Invasive breast cancer: predicting disease recurrence by using high-spatial-resolution signal enhancement ratio imaging. *Radiology*. 2008 Jul;28(1):79-87.

Taplin S, Abraham L, Barlow WE, Fenton JJ, Berns EA, Carney PA, Cutter GR, Sickles EA, Carl D, Elmore JG. Mammography facility characteristics associated with interpretive accuracy of screening mammography. *J Natl Cancer Inst*. 2008 Jun 18;100(12):876-887.

Venkatesan A, Chu P, Kerlikowske K, Sickles EA, Smith-Bindman R. Positive predictive value of specific mammographic findings according to reader and patient variables. *Radiology*. 2009 Mar;250(3):648-657.



GRANTS

Robert G. Gould, ScD

- Novel Parallax Free Sensor for Molecular Imaging. Radiation Monitoring Devices, Inc., 8/15/08 – 8/14/09, \$45,000

Christopher P. Hess, MD, PhD

- Clinical-Radiologic Correlations in Phace Syndrome: Can Imaging Predict Neurologic Outcome? American Society of Neuroradiology, 8/1/08 – 7/31/09, \$7,500

Nola M. Hylton, PhD

- Real-Time *In vivo* MRI Biomarkers for Breast Cancer Pre-Operative Treatment Trials. NIH/NCI, 4/25/08 – 1/31/13, \$2,426,800
- UCSF-Sentinel Research Project. Sentinel Medical, Inc. 11/15/08 – 11/14/11 \$185,400

Bonnie N. Joe, MD, PhD

- Image-directed Tissue Analysis of Breast Cancer. UC Cancer Research Coordinating Committee, 7/1/09 – 6/30/10, \$45,375

Ella F. Jones, PhD

- Characterizing the Evolution of Pre-malignant Tissues at Malignancy. NIH/NCI, 9/18/08 – 8/30/11, \$1,947,242
- *In vivo* Assessments of DePuy Cells in Rat-Tail Discs. Advanced Tech & Regenerative Medicine, 12/1/08 – 12/31/09, \$133,000
- Inhibitor-Directed Imaging of Prostate Cancer. Washington State University 5/1/08 – 7/31/09, \$79,530

Galatea J. Kazakia, PhD

- *In vivo* Imaging of Cortical Porosity in the Peripheral Skeleton. NIH/NIAMS, 2/1/09 – 11/30/13, \$594,000

Jeanne M. LaBerge, MD

- GORE Viabahn Endoprosthesis versus Percutaneous Transluminal Angioplasty (PTA) to Revise Arteriovenous Grafts at the Venous Anastomosis in Hemodialysis Patients (Gore REVISE Study). W.L. Gore & Associates, Inc., 7/7/09 – 5/24/11, \$48,434

Thomas F. Lang, PhD

- A Study of Reduced Bone Quality as a Cause of Fracture. Creighton University Center of Research Translation. 4/1/08 – 3/31/09, \$52,411
- Quantitative Periprosthetic PET/CT. NIH/NIAMS, 9/5/08 – 8/31/10, \$342,540
- Standardization of CT Body Composition, NIH/NIA, 9/1/08 – 8/31/09, \$40,000
- Monitoring Bone Health by Daily Load Stimulus Measurement. National Space Biomedical Research Institute, 10/1/08 – 9/30/09, \$18,736

Xiaojuan Li, PhD

- NMR Spectral Markers of Cartilage Degeneration in Osteoarthritis. NIH/NIAMS, 8/1/09 – 7/31/11, \$382,388

Sharmila Majumdar, PhD

- Imaging for MK0822 Study. Marin Endocrine Care & Research, Inc., 2/2/09 – 2/1/11, \$179,122
- Imaging for MK0822 Study. Diablo Clinical Research, Inc., 10/22/08 – 12/31/10, \$179,122
- Standardization and Cross Calibration of Distal Radius and Distal Tibia Bone Quality using High Resolution Peripheral Computed Tomography Scanners. Synarc, Inc., 1/8/09 – 1/7/10, \$84,118
- A Phase III Randomized, Placebo-Controlled Study to Evaluate the Effect of Odanacatib on Bone Mineral Density and Overall Safety, and to Estimate the Effect of Odanacatib on Bone Micro-architecture in Postmenopausal Women Treated with Vitamin D. Merck & Co., Inc., 10/15/08 – 2/15/10, \$135,034

Carina Mari Aparici, PhD

- O-15 water PET imaging of brain activity in pain: Effects of multi-source transcranial magnetic stimulation. NeoStim, Inc., 4/17/09 – 4/16/10, \$149,445

Alastair J. Martin, PhD

- MR Guided DBS Implantation for Parkinson's Disease. NIH/NIBIB, 6/15/09 – 5/31/11, \$424,875

Susanne Mueller, PhD

- Pfizer Alliance. University of Pennsylvania, 1/1/09–12/31/09, \$6,000

Pratik Mukherjee, MD, PhD

- Macrostructural and Microstructural Imaging Biomarkers. NIH/NINDS. 7/15/09 – 6/30/13, \$2,002,303
- The Attention Dynamics Consortium In Traumatic Brain Injury. Brain Trauma Foundation, 4/1/09 – 3/31/13, \$457,702

Sarah J. Nelson, PhD

- Compounding and Clinical Trial Services Agreement. GE Medical Systems, 3/23/09 – 3/22/11, \$1,650,441.

David A. Saloner, PhD

- Determinants of Intracranial Aneurysm Growth. NIH/NINDS, 1/1/09 – 12/31/13, \$1,689,845

Youngho Seo, PhD

- Optics Characterization and Imaging Studies. Lawrence Livermore National Laboratory, 3/1/09 – 8/31/09, \$30,000
- High Resolution Detectors for Single Photon Cardiac Imaging. Radiation Monitoring Devices, Inc., 9/15/08 – 6/30/09, \$20,000

John A. Shepherd, PhD

- Standardization of Whole Body DXA Measures. GE Healthcare, 7/24/09 – 7/23/10, \$26,000
- Breast Density in Angeliq. Bayer AG, 1/9/09 – 12/31/09, \$61,362
- Pediatric Type 2 Diabetes Therapy: AP Scans. George Washington University, 1/1/08 – 12/31/10, \$7,194

Akhilesh K. Sista, MD

- Evaluating 18F-fluoromisonidazole as an Imaging Biomarkers. Society of Nuclear Medicine, 7/1/08 – 6/30/11, \$25,000

Rebecca Smith-Bindman, MD

- Risk of Cancer Associated with Incidental Findings Identified on Ultrasound Imaging. NIH/NCI, 4/1/09 – 3/31/11, \$392,910

Richard B. Souza, PhD

- Effects of Abnormal Loading on Tibiofemoral Articular Cartilage Composition. NSBRI, 11/1/08 – 10/31/10, \$100,000

Colin Studholme, PhD

- Mapping Patterns of Brain Tissue Growth in Premature Neonates. NIH/NINDS, 8/1/09 – 7/31/14, \$1,684,122

Henry F. VanBrocklin, PhD

- Preparation of Carbon-11 Labeled Dihydroergotamine. MAP Pharmaceuticals, 7/20/09–7/19/10, \$66,083
- Bayer L19SIP Stability Studies. Bayer Schering Pharma AG, 5/29/09 – 5/7/10, \$90,903

Daniel B. Vigneron, PhD

- Hyperpolarized C-13 MR Exploratory Studies of Liver Cancer. NIH/NCI, 6/1/09 – 5/31/11, \$369,393
- Technique Development for Hyperpolarized C-13 MR Studies. NIH/NIBIB, 9/1/09 – 8/31/11, \$193,370

Michael W. Weiner, MD

- Amyloid Imaging, VMCI, and Analysis for ADNI, NIH, 2009 – 2011, \$8,824,331
- Aging Brain: Vasculature, Ischemia and Behavior, Project 2: MRI of Brain Structure and Perfusion, NIH/NIA, 2008 – 2013, \$110,868
- Aging Brain: Vasculature, Ischemia and Behavior, Core C: Neuroimaging Core, NIH/NIA, 2008 – 2013, \$147,234
- Data Sharing Project, Michael J. Fox Foundation, 2009 – 2010, \$75,000

Kelly Westlake, PhD

- Functional connectivity in sensory and motor cortices following stroke: Implications for recovery and rehabilitation. American Heart Association (National Office). 1/1/09 – 12/31/10, \$110,000

Judy Yee, MD





- Evaluation of a Novel Display for CT Colonography. INFINITT, 2009 – 2010, \$100,000

FELLOWSHIPS

Peder E. Larson, PhD

- Dynamic Metabolic Imaging for Prostate Cancer Assessment. American Cancer Society, Inc., 1/1/09 – 12/31/11, \$138,000





2009 PHOTO GALLERY

Images is produced by the Department of Radiology and Biomedical Imaging, UCSF

Design:	Lisa Krieshok
Copyediting:	Diane Fraser
Editorial Coordinator:	Katie Murphy
Printing:	UC Printing Services



University of California
San Francisco

advancing health worldwide™