

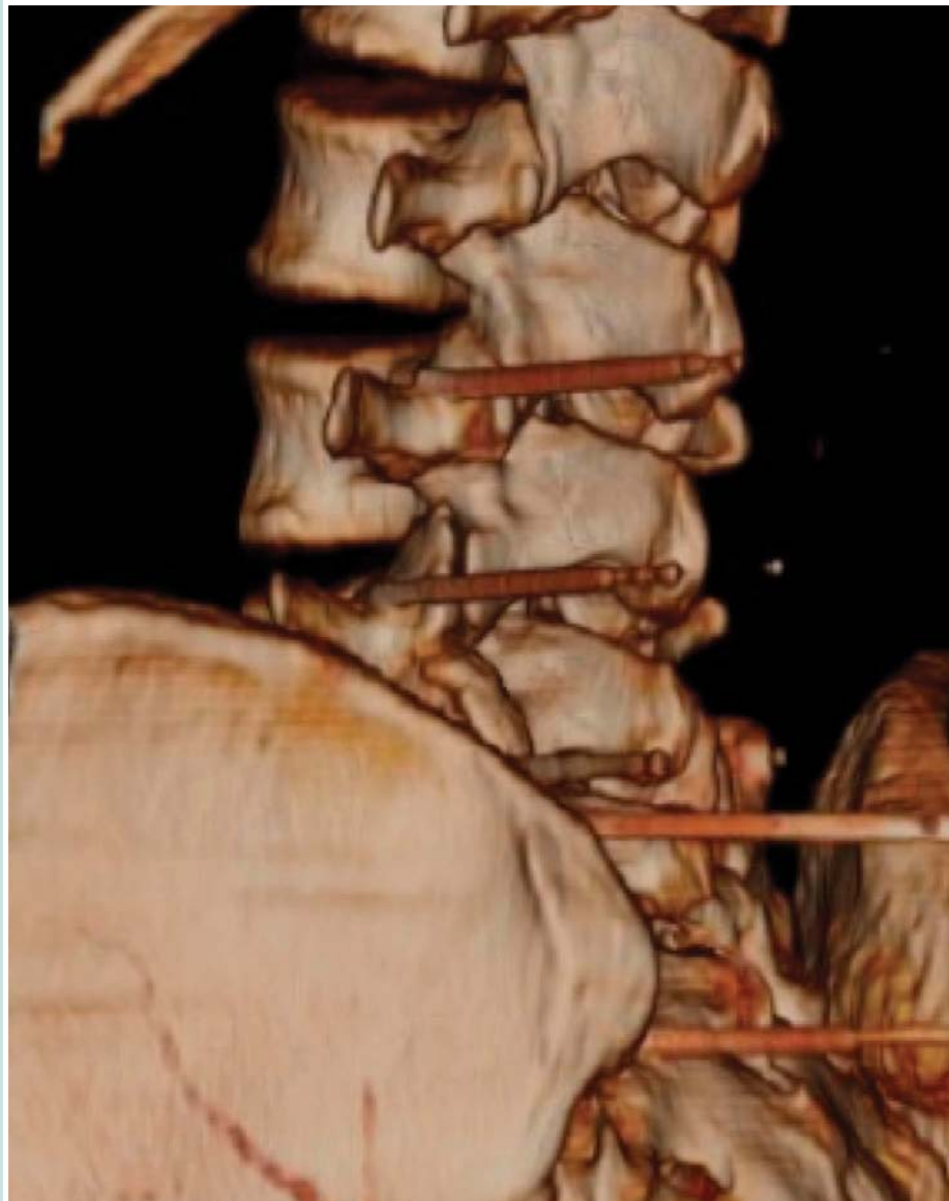2010



UNIVERSITY OF CALIFORNIA SAN FRANCISCO

# IMAGES

---



DEPARTMENT OF RADIOLOGY AND BIOMEDICAL IMAGING

### **About the Cover:**

This 3D reformatted computed tomographic image of the lumbosacral spine shows radiofrequency ablation needles placed under CT guidance for rhizotomy of the right L3-4, L4-5, and L5-S1 facet joints in a patient with right-sided back pain related to underlying facet arthropathy.

# Table of Contents

## letter from the chairman

- 2 Patient Care, Safety, Research, and Learning

## clinical and research news

- 4 Spine Injections
- 10 MR T<sub>1</sub> $\rho$  Relaxation Time Quantification Reveals Early Cartilage Degeneration in Osteoarthritic and Acutely Injured Knees
- 14 Emerging Multivariate Analysis Methods for Multimodal MRI Studies of Neurodegenerative Diseases
- 18 Multi-Parametric Anatomic, Functional, and Hyperpolarized Micro-Imaging at Ultra-High Field (14T)

## new facilities and technology

- 22 A Replacement Year
- 24 State-of-the-Art Women's Imaging Services for Breast Cancer Screening and Evaluation

## department update

- 26 Three New Section Leaders in 2010
- 27 New Faculty Appointments
- 30 Honors and Awards
- 33 Clinical Faculty Honored for Their Contributions
- 33 Hylton Named to Scientific Advisory Council
- 34 Retired in 2010
- 35 In Memoriam: T. Hans Newton, MD
- 36 Diagnostic Radiology Residency Program
- 39 The Nuclear Medicine Training Program
- 40 First-Year Diagnostic Radiology Residents 2010
- 46 Second-, Third-, and Fourth-Year Diagnostic Radiology Residents 2010–2011
- 47 Clinical Fellows/Instructors 2010–2011
- 48 Diagnostic Radiology and Nuclear Medicine Residency Graduates—Class of 2010
- 50 The Margulis Society
- 52 The Margulis Society Donor List
- 54 Alumni News
- 56 Surbeck Young Investigators Awards
- 58 The Henry I. Goldberg Center for Advanced Imaging Education
- 59 Radiology Postgraduate Education
- 61 2011 Radiology CME Calendar
- 62 Imaging Research Symposium and Second Bruce Hasegawa Award
- 63 The Lanna Lee Award
- 64 Faculty Roster
- 68 The Year in Pictures

## radiology and biomedical imaging research

- 70 Research Directions
- 86 Grants and Fellowships

### Dear Colleagues and Friends,

As *Images* went to press last year, we were in our third month with a new Chancellor, Susan Desmond-Hellman, MD, MPH, and a new Dean, Sam Hawgood, MBBS, and UCSF had just won its fourth Nobel Prize! At the same time, we became aware of the need for operational improvements to help the campus, school, and department cope with unprecedented financial challenges. I am happy to report that Radiology and Biomedical Imaging had an incredibly successful 2010, thanks to faculty, trainees, and staff rising to these challenges.

The Chancellor has asked us to think about goals in five broad categories: patients and health, discovery, education, people and diversity, and business processes and efficiencies. Our department has expertise and accomplishments to share in each area. Most importantly, we remained focused on delivering excellent patient care and timely, relevant interpretations to referring physicians to help them diagnose and treat their patients. The two new inpatient MRIs in Long Hospital—the first inpatient expansion of radiology in more than 20 years—have been very well received and well utilized. Our joint venture with the UCSF Medical Center at the China Basin Imaging Center continues to be a great success. Our focus on improved service to clinicians has produced demonstrable results and we hope to expand this relationship with the medical center in 2010.

Radiation exposure has been much in the news lately. Rebecca Smith-Bindman, MD, of our faculty, received significant publicity for her work on the risks and benefits of CT scans. While we have had some healthy discussion about radiation issues, I commend Dr. Smith-Bindman for her work and the issues she raised.

Our commitment to safety and offering good advice to referring colleagues remains very high. For example, the Patient Safety Committee, led by Dr. Roy Gordon and our clinical team, led by Dr. Fergus Coakley, have developed easy-to-understand material for patients and clinicians on radiation issues. In addition, Drs. Coakley and Bob Gould are conducting a pilot project with our Emergency Room colleagues where radiation dose is individually calculated and reported to the ordering physician. We are also upgrading our CT scanners to include software which will help with dose minimization at all of our sites.

2009 and 2010 have been banner years for research and discovery. I am very proud that we held our second-place position in NIH funding, with nearly \$40 million in awards in 2009. Much of the credit for this accomplishment belongs to Dr. Mike Weiner and his exceptional work at the Center for Imaging of Neurodegenerative Disease. In total, more than 40 faculty investigators received grants this past year. UCSF Radiology also was the first in the country in ARRA awards. We received funding for 23% of our ARRA proposals, totaling nearly \$30 million. This is exceptional, and our basic scientists and physician scientists deserve tremendous credit. I particularly want to thank our Vice Chair for Research, Dr. Sharmila Majumdar, for her exceptional research leadership and creative, energetic guidance.

The UCSF Radiology residency continues to be ranked #1 in the country. This year we had nearly 600 applications for 12 slots. The match went very well, with thanks due to our Program Director, Dr. Aliya Qayyum, our Associate Director, Dr. David Avrin, and our chief residents and senior residents. They are tremendous cheerleaders for



the program. You should know that nearly every resident now completes a research program and the chief residents play an important role on the Department Operations and Patient Safety committees.

Once again I want to extend many thanks to the Margulis Society for its support of our residency program. This year, the Margulis Society inaugurated a biennial lecture series. We were thrilled to welcome our alum, Dr. William Brody, president of the Salk Institute, who inaugurated the series with a thought-provoking lecture.

As you can read (p. 58) we spent significant time reorganizing the medical student experience in the Goldberg Center under the leadership of Dr. Emma Webb. We continue to honor the legacy of Dr. Bruce Hasegawa with an award to an outstanding post-doctoral scholar, R. Dana Carpenter, PhD, as well as a named lecture in the spring.

Our faculty continue to receive accolades, honors, and awards, which you will read about in this issue. Throughout a very difficult year, our faculty and staff made enormous contributions. They never let budget cuts, furloughs, lack of resources, or other complications stop them from striving to make this the best radiology department in the country. I want to acknowledge and thank Dr. Bill Dillon, executive vice chair, and Cathy Garzio, our administrative director, for their help guiding the department while I took a sabbatical this past year. Both are tremendous leaders!

I am not sure what 2011 will bring, but I expect that more change is certain. I spent part of my sabbatical reflecting on what it means to be a leader in radiology in the United States today. Clearly, health care reform, financial challenges, turf battles, and many other issues put the specialty at a crossroads. However, I am hopeful that our focus on excellence in patient care, translational



research, and educating future generations of clinicians and researchers will allow us to continue to evolve and deliver value over this next year and many more.

Please don't forget to join us in Chicago at our RSNA reception for alumni and friends. We will once again be at the Rookery Building in Chicago's Loop, Sunday November 28 2010. I look forward to seeing you and talking with you about your own exciting accomplishments and ideas.

Sincerely,

A handwritten signature in dark ink that reads "Ronald L. Arenson, MD". The signature is written in a cursive, flowing style.

Ronald L. Arenson, MD

## Spine Injections

Cynthia T. Chin, MD

### Background

Back pain is one of the most common health problems in the United States and is the leading cause of disability for persons younger than 45 years, according to the American College of Radiology appropriateness criteria. It is estimated that billions of dollars are spent annually to evaluate and treat back pain, not including the time lost from work.

Only a minority of back pain patients (1%–10%) require surgery. The use of spine injections, along with a proper rehabilitation program, may play an important role in the conservative management of patients with back and radicular pain, improving their quality of life and function. For some patients, the goal is to use non-surgical therapies to manage the pain and avoid major surgery, or to be more comfortable while awaiting surgery.

The first documented spinal epidural medication injection to treat back pain and sciatica was performed in 1901 using cocaine, the first clinically administered local anesthetic. From the 1920s to 1940s, spinal epidural injections

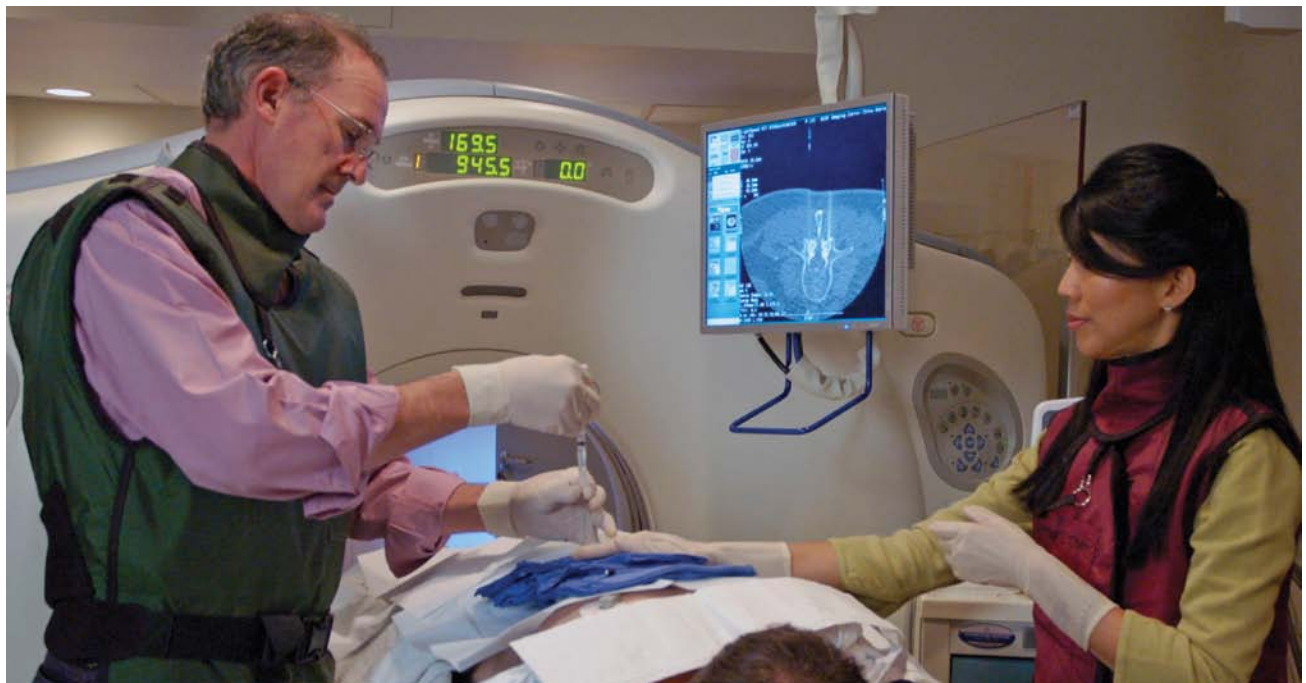used high volumes of normal saline and local anesthetics. In 1952, injection of corticosteroids into the epidural space for lumbar radicular pain was first recorded and was first reported in the United States in 1961.

The frequency of interventional spine pain management procedures is growing, as evidenced by a 100% increase in Medicare claims for epidural injections from the late 1990s to early 2000s.

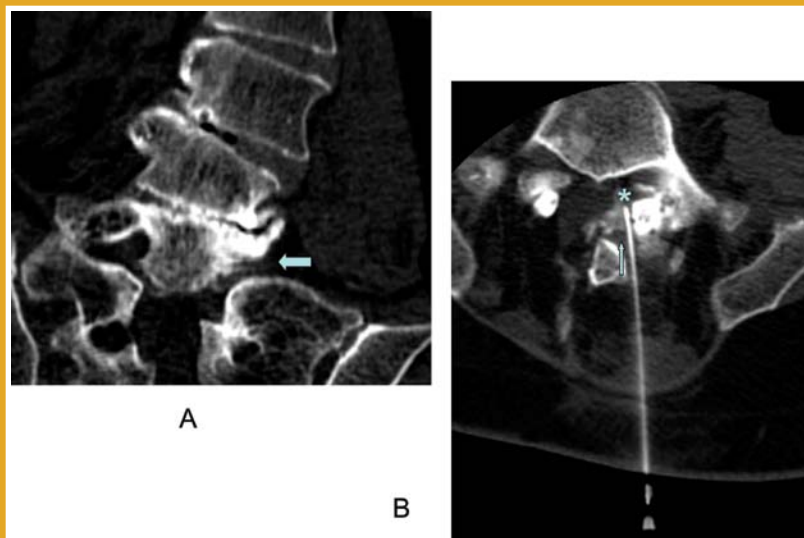
The recent opening of the UCSF Precision Spine and Peripheral Nerve Center puts UCSF Radiology at the forefront in interventional spine care management. The center offers state-of-the-art imaging technology and ongoing research explores the diagnosis and management of spine and peripheral nerve-related disease.

### Mechanism

There is evidence of an inflammatory basis for back and radicular pain. This inflammatory mechanism is both autoimmune mediated via macrophage activity and non-

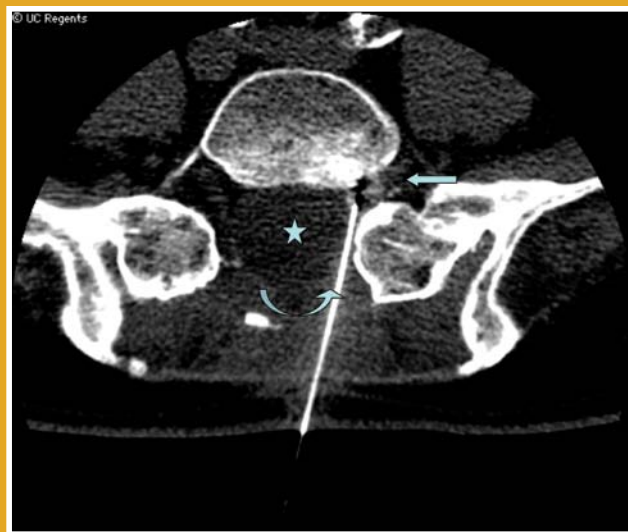


William Dillon, MD, Chief of Neuroradiology, and Cynthia Chin, MD, perform a CT-guided spine injection at the UCSF Precision Spine and Peripheral Nerve Center.



**Figure 1:** After an unsuccessful attempt at an L5 injection under fluoroscopic guidance, a 75-year-old patient with severe left leg pain was referred to UCSF for a left L5 epidural injection under CT guidance. Coronal (A) and axial (B) CT images of the lumbosacral spine demonstrate severe scoliosis with severe narrowing of the left L5 foramen (arrows). The left L5 epidural injection was performed successfully under CT guidance (B) with the needle tip in the left epidural space and contrast within the left L5 lateral recess and epidural space (asterisk). The patient had complete resolution of symptoms following the injection.

**Figure 2:** A 60-year-old patient with severe back and leg pain referred to UCSF for a left L5 nerve block under CT guidance due to the inability to safely access the nerve under fluoroscopic guidance. The patient had a previous laminectomy (curved arrow) and spinal fusion, precluding usual access to the left L5 nerve. The needle was successfully advanced in the 2mm space lateral to the thecal sac (star) to terminate at the left L5 foramen. Contrast outlines the left L5 nerve root within the foramen. (straight arrow)

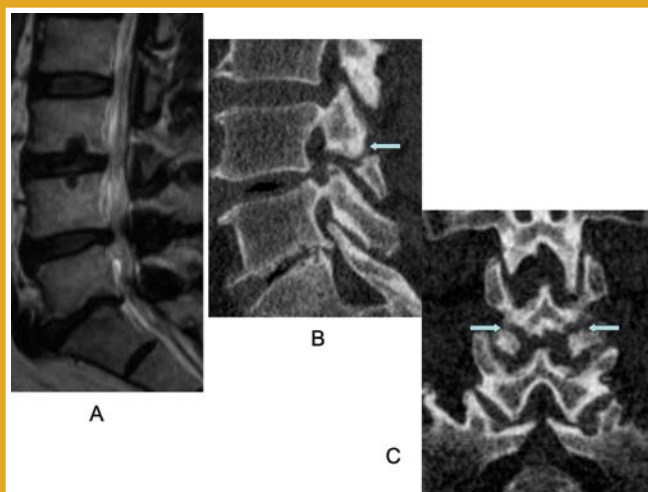


immune mediated through histiocytes, fibroblasts, and chondrocytes with the release of cytokines, phospholipases, prostaglandins, and leukotrienes. This underlying inflammatory mechanism forms the rationale for the use of spinal corticosteroid injections: their anti-inflammatory effect has been shown to be effective in reducing pain.

### Image Guidance

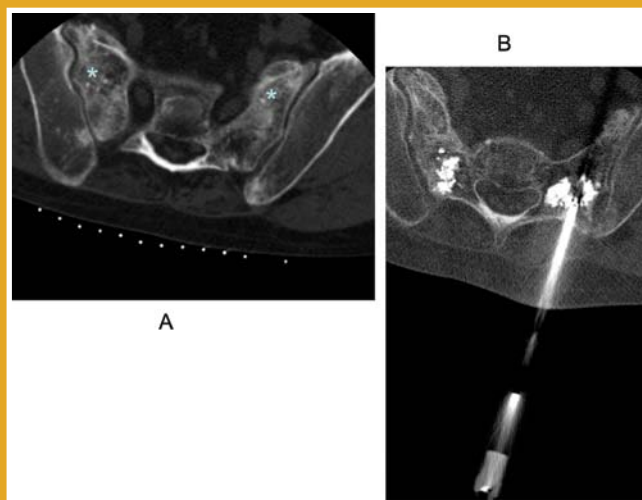
The method of guidance for spinal injections may be a subject of great discussion. The traditional epidural injection technique may involve the physician feeling the patient's spine in order to guide the placement of a needle. While

X-ray fluoroscopic guidance is commonly used to guide the needles in spinal injections, computed tomographic (CT) scan guidance has been shown to provide more accurate and precise placement of injections. It also reduces patient discomfort during the procedures. The quantity of contrast used for spinal injections under CT guidance is much lower relative to the quantity used in fluoroscopic-guided injections. CT guidance is essential in patients with congenital variations in anatomy, post-operative patients, and in patients with degenerative disease obscuring normal anatomic landmarks. (Figures 1 and 2) In addition, CT images allow physicians to evaluate and identify additional



**Figure 3:** A 65-year-old patient with low back and leg pain presumed due to disc disease referred for transforaminal epidural blocks. Sagittal T2 sequence of the lumbar spine (A) demonstrates spinal stenosis and multilevel degenerative disc disease. Sagittal (B) and coronal (C) CT images of the lumbar spine obtained in preparation for the injections demonstrate bilateral L4 pars interarticularis fractures (arrows) not previously diagnosed.

**Figure 4:** A 72-year-old patient on chronic steroids with debilitating low back pain referred for facet and sacroiliac injections. CT scan obtained in preparation demonstrates bilateral subacute sacral insufficiency fractures not previously diagnosed. (A: asterisks) The patient instead underwent bilateral sacroplasty with injection of cement for fracture stabilization (B) with improvement in symptoms.



potential sites of pain generation that may not have been diagnosed (i.e., insufficiency fractures and pars defects). (Figures 3 and 4)

CT-guided spine procedures are done at the UCSF Precision Spine and Peripheral Nerve Center using a dedicated, latest-generation CT scanner. An in-room monitor and fast, minimal dose-radiation CT scan techniques allow the precise placement of the needle near a nerve in question. We also can use CT to diagnose the causes of spine disease. The scanner uses the most recent radiation dose reduction software available: Adaptive Statistical Iterative Reconstruction. This is the first software to allow dramatic reductions—up to 70%—in the already low patient radiation dose during injections.

### Medications

Corticosteroids and anesthetics are the most commonly administered medications in spinal injections. They are routinely administered in combination during the same procedure. For purely diagnostic injections, an anesthetic alone is usually injected. For therapeutic injections, steroids are injected along with the anesthetic.

Corticosteroids predominantly affect the action of cytokines involved in inflammation. They lead to down-regulation of immune function, inhibiting cell-mediated immunity, reducing cellular accumulation at inflammatory sites, and decreasing vascular responses.

Local anesthetics act mainly by inhibiting sodium-specific ion channels on neuronal cell membranes, preventing



the development of action potentials and inhibiting signal conduction.

All neurons are sensitive to local anesthetics; however, smaller diameter neurons are blocked more effectively than larger neurons. Therefore, pain sensation (smaller myelinated axons) can be blocked with relative preservation of sensation.

One of the most commonly administered local anesthetic in spine injections is bupivacaine, which has a longer duration of action and is more potent than lidocaine. The anesthetic effect of bupivacaine may last no more than 6 to 7 hours; however, bupivacaine injections have been demonstrated to provide relief from chronic back pain after lumbar facet nerve-root blocks for a median duration of 15 weeks. The mechanism for this relative long-term relief is unknown and may be related to the possible suppression of nociceptive discharge, blockade of sympathetic reflex arc, axonal transport and sensitization, and anti-inflammatory effects.

### **Injections**

Common potential degenerative spine sources of back pain include facet joint disease, spinal stenosis, and disc disease, all of which can also compromise the spinal nerves resulting in radiculopathy as well.

Symptoms arising from these different spinal tissues can feel very similar and may therefore be quite difficult to differentiate without the use of injection procedures.

**Facet Joints<sup>1</sup>:** The facet joints, synovial joints of the spine, may be the primary source of pain in approximately one-third of people with chronic low back pain, and in most people with neck pain following whiplash. The joint capsule tissue or the intra-articular tissue may become damaged, displaced, pinched, or trapped, and give rise to pain.

The capsules contain mechanoreceptors as well as different nociceptors, which are well innervated by the medial branches of the dorsal rami. These nerve fibers are the target for different injection therapies to the facet joints.

---

1 “Facet joint” is an American term, coined in the 1970s, when surgeons became interested in these small joints as a source of back pain. The zygapophysial joints, the formal name which had been in use for centuries and endorsed by the International Anatomical Nomenclature Committee, is derived from the Greek words *zygos*, meaning yoke, connection, or bridge, and *physis*, meaning growth. A popular contraction for zygapophysial joint is “z” joint.

Multiple studies have failed to identify any consistent clinical features that are indicative of lumbar facet joint pain. Therefore, diagnostic blocks are the only means of diagnosing this entity.

The facet joints can be anesthetized by injecting local anesthetic into the cavity of the target joint (intra-articular blocks), or onto the nerves that innervate the joint (medial branch blocks). Radiofrequency neurotomy is a natural progression from positive blocks.

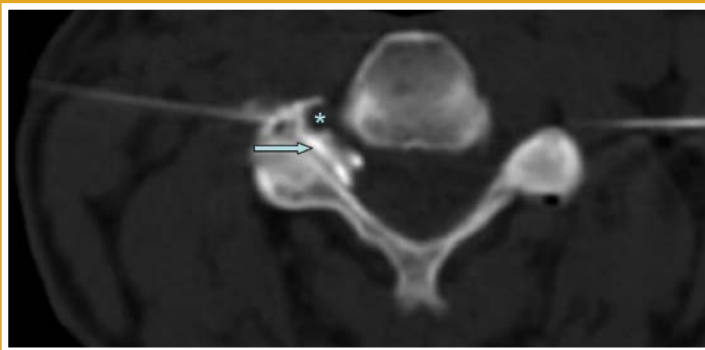
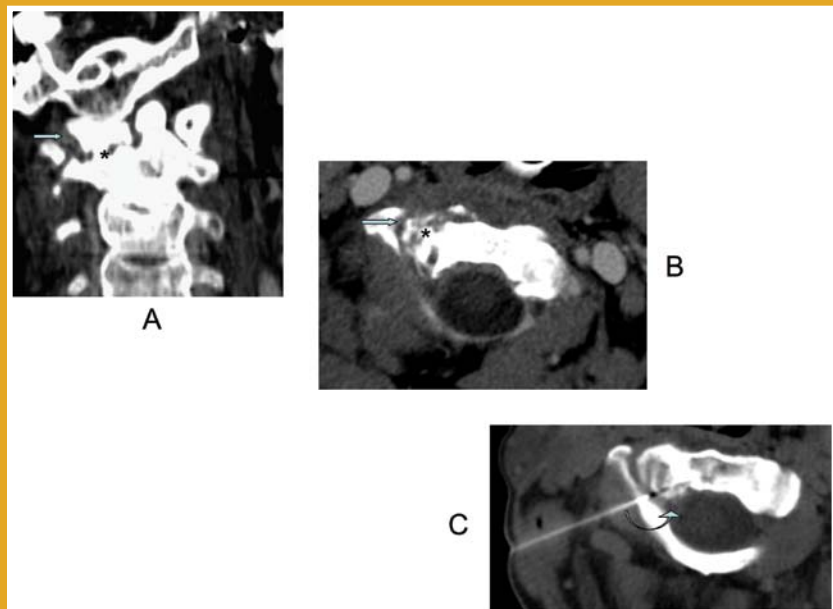
**Medial branch blocks:** Medial branch blocks target each of the nerves that innervate a given facet joint. Using CT guidance allows for more accurate and precise needle placement compared to conventional fluoroscopy. A small volume of local anesthetic is deposited onto each nerve innervating the target joint.

**Medial branch radiofrequency ablation:** Medial branch neurotomy exerts a far more lasting effect because the nerve is physically altered. Histologically and physiologically, thermal coagulation at temperatures above 80 °C affects motor fibers and sensory fibers, denaturing the nerve, thereby relieving pain. Although the nerve eventually regenerates, the rate of regeneration is slower than after traumatic nerve injuries. When nerves are transected, axon tubules regenerate within hours of the injury, cross the gap, and grow into the distal segment at a rate of 1 mm per day. In contrast, radiofrequency thermal coagulation seals the nerve *in situ*, providing no gap across which the nerve can regenerate. Before regeneration can occur into the distal segment, the coagulated segment must be repaired by endocellular processes, which may take several months. (cover image)

**Epidural and Nerve Blocks:** Epidural and nerve root block/steroid injections are common interventional treatments for spine and radicular pain. Epidural steroid injections are highly effective in a large proportion of patients, including patients with axial pain (neck or low back pain), or spinal stenosis with neurogenic claudication. The injection can be specifically guided to the region of greatest stenosis under CT guidance.

When isolated lumbar nerve root irritation is more clearly suspected, nerve root blocks can provide useful diagnostic information as well as deliver more specifically targeted steroid treatment. Nerve root blocks (NRBs) have

**Figure 5:** A 59-year-old patient with severe right neck and head pain. Coronal (A) and axial (B) CT images demonstrate advanced degeneration and subluxation of the right C1 and C2 lateral masses (asterisk), resulting in severe right C1-2 foraminal stenosis and significantly narrowing the course of the right vertebral artery (arrow). Axial CT scan (C) demonstrates successful right C2 nerve block with needle placement safely remote from the vertebral artery. The patient's symptoms resolved following the injection.



**Figure 6:** A 45-year-old patient with right arm pain who underwent a right C5 nerve block. Axial CT scan demonstrates contrast outlining the right C5 foraminal nerve root. The needle tip is safely positioned remote from the vertebral artery (asterisk).

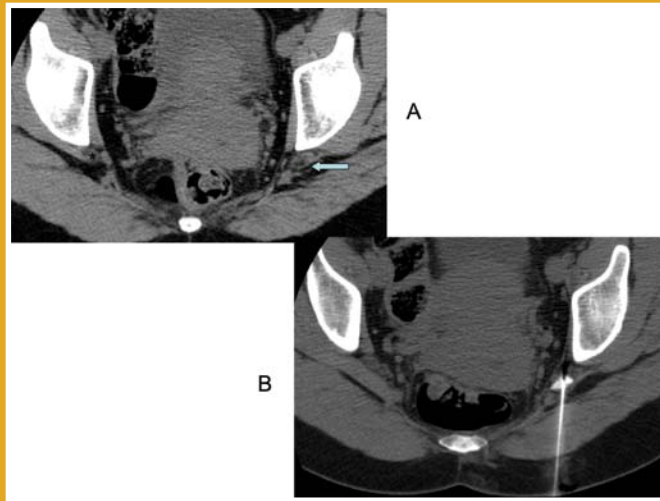
an important role in the conservative treatment of patients with radicular pain.

Sustained pain relief can be achieved in a substantial number of patients with both types of procedure. The majority of patients with lumbar radicular pain who avoid an operation for at least one year after receiving a nerve root injection with bupivacaine alone or in combination with steroid may continue to avoid operative intervention for a minimum of five years.

Nerve root injections enable the delivery of medication directly to a given critical location where the nerve is being compressed by osteophytes, disc extrusions, facet arthropathy, etc. They also may help reduce the risk of systemic side effects. The doses of anesthetics and corticosteroids required for epidural injections are larger than those

required for selective blocks, and higher medication doses may increase the risk of side effects, including iatrogenic Cushing syndrome.

The potential for severe complications with cervical spine interventions is higher than that with lumbar spine interventions. Damage to the cervical spinal cord following epidural steroid injections has been described. Spinal cord infarction has also been described with nerve blocks in the cervical and lumbosacral regions; it is thought to be caused by embolization of the particulate components of the injected steroid, leading to an anterior spinal artery syndrome. Because CT guidance allows for visualization of the vertebral artery, it reduces the risk of injury to the vertebral artery and the cervical spinal cord. CT guidance increases the precision of injections and helps the physi-



**Figure 7:** A 46-year-old patient with chronic left buttock pain. Axial CT scan through the sciatic notch (A) demonstrates a markedly enlarged and edematous left sciatic nerve (arrow) relative to the normal right sciatic nerve (asterisk). Left sciatic nerve block (B) demonstrates contrast outlining the left sciatic nerve. The patient had significant improvement in symptoms.

cian avoid these vital structures during needle placement. (Figures 5 and 6)

**Disc:** The normal intervertebral disc (IVD) is a poorly innervated structure supplied only by sensory (mainly nociceptive) and postganglionic sympathetic (vasomotor efferents) nerve fibers. With degeneration, the IVD becomes densely innervated, even in regions that in normal conditions lack innervation. This increased innervation has been associated with pain of IVD origin.

A disc may be painful when it bulges, herniates, tears, or degenerates. MRI and CT scans demonstrate anatomy and cannot absolutely prove a pain source. In many instances, discs are abnormal on MRI or CT scans but are not a source of pain.

Discography is a functional test that can demonstrate the disc(s) as a pain generator. A small needle is used to inject contrast dye into the disc with the goal of reproducing a patient's pain if it is discogenic. Discography is usually performed when pain is significant enough to consider more advanced treatment options, directed at the disc itself, such as surgery (i.e. fusion, disc replacement)

**Extraspinal Sciatica (Piriformis syndrome):** Piriformis syndrome is attributed to compression of the sciatic nerve in the pelvis by the piriformis muscle. Although lumbar disc herniation or spinal stenosis are the more common etiologies for sciatica, piriformis syndrome is thought

to account for a small but distinct percentage of patients presenting with sciatic, leg, or buttock pain. It is difficult to diagnose and often goes undiagnosed. Routine MRI of the spine is often unremarkable in these patients. Proposed etiologies of nerve compression are the intramuscular course of the sciatic nerve, hypertrophy of the piriformis muscle, post-traumatic changes involving hematoma, fibrosis, myositis ossificans, and fracture (especially, avulsion fracture of ischial tuberosity). Diagnosing and managing this syndrome includes injections of the piriformis muscle and sciatic nerve blocks. At UCSF, CT guidance allows for accurate and safe positioning of these injections. (Figure 7)

### Summary

Spinal injections can be highly effective for a large proportion of patients with back and radicular pain and they play an increasingly important role in diagnosis and conservative management. The goal of the spinal injection is not to cure anatomic abnormalities, but rather to diagnose the pain generator and to reduce pain, allowing patients to engage in rehabilitation and to return to their normal activities. UCSF Radiology is at the forefront in participating in the integral care of these patients.

*Cynthia T. Chin, MD is an associate professor of clinical radiology in the Neuroradiology Section of the Department of Radiology and Biomedical Imaging and Neurosurgery and is the director of the UCSF Precision Spine and Peripheral Nerve Center.*

# MR $T_{1\rho}$ Relaxation Time Quantification Reveals Early Cartilage Degeneration in Osteoarthritic and Acutely Injured Knees

Xiaojuan Li, PhD, Eric T. Han, MS, Richard Souza, PT, PhD, Thomas M. Link, MD, PhD, C. Benjamin Ma, MD, Sharmila Majumdar, PhD

## Cartilage and Osteoarthritis

Osteoarthritis (OA) is characterized by the progressive loss of hyaline articular cartilage. Magnetic resonance imaging has been widely applied to visualize cartilage directly. However, conventional MRI is limited to showing morphological changes in cartilage at a stage when cartilage is already irreversibly lost. Standard MR techniques dedicated to cartilage include fat-saturated  $T_2$ -weighted, proton density-weighted fast spin echo (FSE) sequences and  $T_1$ -weighted spoiled gradient echo (SPGR) sequences. These sequences, however, are inconclusive in quantifying early degenerative changes in the cartilage matrix.

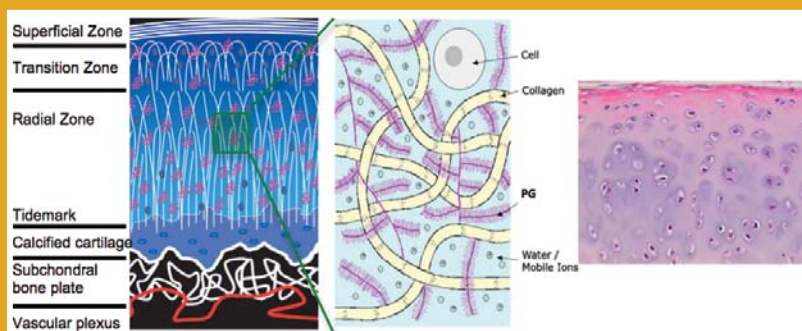
Hyaline articular cartilage is composed of chondrocytes surrounded by a large extracellular matrix (ECM). The ECM is composed primarily of water and two groups of macromolecules: proteoglycan and collagen fibers (mainly type II) (Figure 1). Early events in the development of cartilage matrix breakdown include the loss of proteoglycans, changes in water content, and molecular-level changes in collagen. Early diagnosis of cartilage degeneration would require the ability to non-invasively detect changes in proteoglycan concentration and collagen integrity before gross morphologic changes occur.

The UCSF Department of Radiology and Biomedical Imaging in close collaboration with the Applied Science Laboratory at GE Healthcare have developed novel quantitative MRI, namely  $T_{1\rho}$  relaxation time quantification in cartilage. Our goals are to improve early diagnosis of cartilage injury and degeneration, allowing early intervention, and to provide critical evaluation of therapeutic treatment.

## MR $T_{1\rho}$ Definition and Quantification Methods

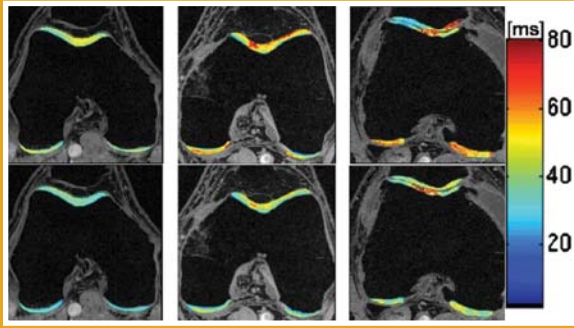
The  $T_{1\rho}$  parameter is defined as the time constant describing the spin-lattice relaxation in the rotating frame. It probes the slow-motion interactions between motionally restricted water molecules and their local macromolecular environment, and therefore provides unique biomedical information in the low-frequency regime. The macromolecules in articular cartilage ECM restrict the motion of water molecules. Changes to the ECM, such as loss of proteoglycan, therefore, can be reflected in measurements of  $T_{1\rho}$ .

The Musculoskeletal Quantitative Imaging Research group within UCSF Radiology is one of the first groups in the field to develop  $T_{1\rho}$  quantification techniques in cartilage, and to translate the techniques into clinical applications for patients with osteoarthritic or acutely injured



**Figure 1.** Schematic representation of cartilage molecular organization. Left: Multi-layer structure of hyaline cartilage. Middle: The extracellular matrix (ECM) of hyaline cartilage is composed primarily of water and two groups of macromolecules: proteoglycan (PG) and collagen (mainly type II) fibers. Right: 400X hyaline cartilage histology.





**Figure 2.**  $T_{1\rho}$  maps (first row) and  $T_2$  maps (second row) for a healthy control (left), a patient with mild OA (middle), and a patient with severe OA (right).  $T_{1\rho}$  and  $T_2$  values were significantly elevated and become more heterogeneous in OA cartilage.  $T_{1\rho}$  and  $T_2$  showed different spatial distribution and may provide complementary information regarding cartilage degeneration in OA.

knees. During the past six years, we have developed novel and robust  $T_{1\rho}$  quantification techniques using spin-lock (SL) techniques followed by 2D (spiral or FSE sequences) or 3D (SPGR sequences using transient signal evolving towards the steady-state).

In an SL experiment, spins are flipped into the transverse plane along one axis, immediately followed by an SL pulse applied along the same axis. Under locking condition, the spins will relax with a time-constant  $T_{1\rho}$  along  $B_1$  of locking pulses in the transverse plane. The amplitude of the SL pulse is defined as SL frequency, normally ranging from a few hundreds hertz to a few kilohertz. The duration of the SL pulse is defined as time of SL (TSL).  $T_{1\rho}$  relaxation phenomena are sensitive to physicochemical processes with inverse correlation times on the order of the nutation frequency of the SL pulse. By setting the amplitude of the SL pulse to coincide with the frequency of the molecular processes of interest, the signal from the SL-MRI sequence becomes heavily  $T_{1\rho}$ -weighted.  $T_{1\rho}$  can be computed by acquiring a series of  $T_{1\rho}$ -weighted images at various TSL by fitting the exponential decay curve.

Using specimens collected from patients who underwent total knee arthroplasty (TKA) due to severe OA, we demonstrated a significant, negative correlation between  $T_{1\rho}$  quantification and the concentration of proteoglycan in the cartilage matrix. The *in vivo* average coefficient-of-

variation (CV) of mean  $T_{1\rho}$  values for cartilage was 1.6%, with regional CV ranging from 1.7% to 8.7%, indicating excellent reproducibility.

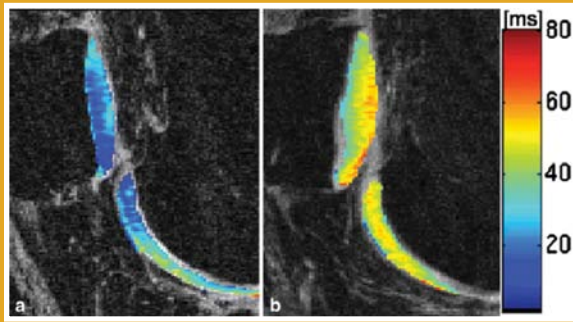
#### ***In vivo* MR $T_{1\rho}$ Quantification in Osteoarthritic Knees**

Using developed techniques, we demonstrated significantly elevated cartilage  $T_{1\rho}$  values in OA subjects compared to controls (Figure 2). Increased  $T_{1\rho}$  were also correlated with increased disease severity shown with X-rays and MRI. Furthermore, we observed biochemical, degenerative cartilage changes, as indicated by elevated  $T_{1\rho}$ , in morphologically normal appearing knees with standard MRI. Compared with more established  $T_2$  quantification,  $T_{1\rho}$  has a larger dynamic range and higher effect size in distinguishing between OA and control cartilage.  $T_{1\rho}$  and  $T_2$  also show different spatial distribution (Figure 2) and may provide complementary information regarding cartilage degeneration in OA.

In addition to average values, texture analysis has been applied to quantify the heterogeneity in  $T_{1\rho}$  maps. We demonstrated that OA cartilage had significantly higher  $T_{1\rho}$  contrast and entropy compared to controls, indicating that  $T_{1\rho}$  values are not only increased, but are more heterogeneous in osteoarthritic cartilage.

We also applied  $T_{1\rho}$  measurements in physically active and sedentary healthy subjects, as well as in patients with early OA.  $T_{1\rho}$  values in active subjects with and without focal cartilage abnormalities differed significantly (Figure 3 on the next page), even in the regions where no cartilage abnormalities were observed with clinical MRI.  $T_{1\rho}$  were significantly higher in early OA patients compared to healthy subjects. These results suggest that  $T_{1\rho}$  could be a parameter suited to identify active healthy subjects at higher risk for developing cartilage pathology. This non-invasive imaging marker would be valuable for developing preventive interventions or strategies for OA.

It is well known that OA is a multi-factorial disease involving not only cartilage, but other tissues, such as meniscus and subchondral bone. We observed that the increase of cartilage  $T_{1\rho}$  correlated significantly with a decrease of trabecular bone structures in subjects with mild OA. In addition, cartilage  $T_{1\rho}$  quantification can not only distinguish between subjects with a normal meniscus and those with a meniscal tear, it can also distinguish between subjects with increased intra-substance signal and those with a meniscal tear, providing a more sensitive stratification of joint degeneration compared to conventional MRI. These stud-



**Figure 3.** Color-coded  $T_{1\rho}$  maps overlaid on SPGR images from a central section of the patello-femoral cartilage. (a) demonstrates the  $T_{1\rho}$  map of an active, asymptomatic 25-year-old male subject without focal cartilage abnormalities anywhere in the knee. The average  $T_{1\rho}$  of the patello-femoral compartment was  $33.7 \pm 0.73$  ms. (b) shows the  $T_{1\rho}$  map of an active, asymptomatic 36-year-old female subject at the central femoro-patellar joint who had a cartilage lesion at the lateral patella. The average  $T_{1\rho}$  of the patello-femoral compartment was  $45.9 \pm 1.68$  ms. Interestingly, compared to subject (a), the  $T_{1\rho}$  values at the central patella and at the trochlea are globally increased not only in the region of the defect, yet have a similar distribution.

ies suggest that there is a complex interrelationship among cartilage, meniscus, and trabecular bone degeneration in OA knees, and that MR  $T_{1\rho}$  is a valuable tool to quantify such correlations.

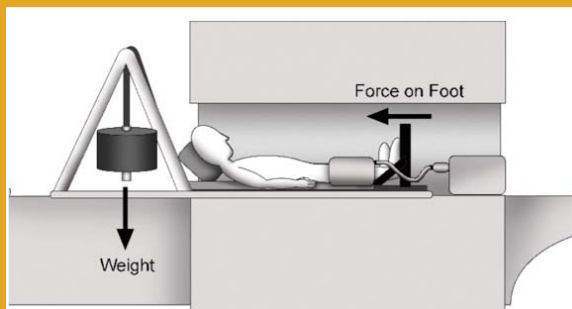
More recently, we evaluated  $T_{1\rho}$  measurements in cartilage with simulated acute loading, using an MR-compatible

loading device developed in-house (Figure 4). We demonstrated that acute loading resulted in a significant decrease in  $T_{1\rho}$  of the medial compartment, with greater change of values observed in cartilage regions with small focal lesions. These data suggest that changes of  $T_{1\rho}$  values with loading may be related to cartilage biomechanical properties and may be a valuable tool for identifying early cartilage disease.

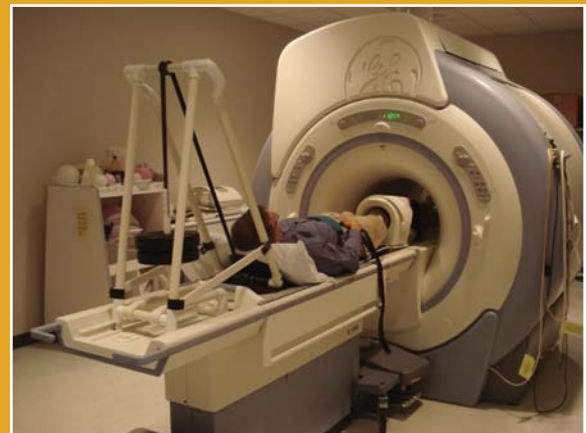#### ***In vivo* MR $T_{1\rho}$ Quantification in Knees with Acute Injuries**

In addition to patients with OA,  $T_{1\rho}$  quantification techniques have been applied to patients with acutely injured knees, in particular patients with acute anterior cruciate ligament tears. Previous cohort studies showed that more than half of patients with ACL tears will develop OA later in life, even after ACL reconstruction. There is a profound need for early detection of joint degeneration in such knees.

Using developed techniques, we demonstrated significantly increased  $T_{1\rho}$  values in the posterior lateral tibia. This sub-compartment overlies the commonly seen bone bruise during ACL tear. The elevation of  $T_{1\rho}$  in these regions indicated cartilage damage due to translational injury when the ACL was ruptured. Two patients have been confirmed to have cartilage damage in these regions with elevated  $T_{1\rho}$  values using arthroscopic images. (Figure 5) Interestingly, at one year after ACL reconstruction, despite the resolution of BMEL, cartilage overlying the baseline BMEL still shows significantly higher  $T_{1\rho}$ . This suggests potential irreversible damage of cartilage in these regions. Previous histological studies revealed a loss of the proteoglycan component in



**Figure 4.** Schematic (above) and photo (right) of the MR-compatible loading device developed in-house.



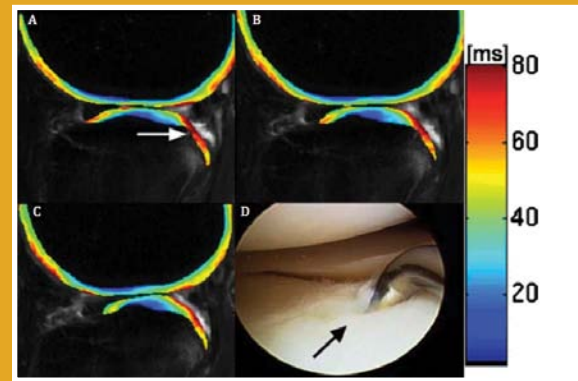
cartilage matrix overlying BMELs. We have, for the first time, detected and followed up such changes in cartilage matrix non-invasively using advanced MR techniques. In addition, at one-year follow up, we observed significantly elevated  $T_{1\rho}$  values in the medial femorotibial cartilage, in particular the contact areas of medial femoral condyle and medial tibia.

To explore potential mechanisms of post-traumatic OA development in ACL-injured knees, we developed techniques to simultaneously quantify knee kinematics (under simulated acute loading) and cartilage  $T_{1\rho}$ . Abnormal kinematics following ACL reconstruction are thought to be a cause of post-traumatic OA. However, it has been difficult to show a direct relationship between changes in knee kinematics and the development of OA, primarily due to the long lag time between injury and resultant morphological cartilage changes seen in radiographs. Using  $T_{1\rho}$  MRI, we observed that the  $T_{1\rho}$  increase in medial femorotibial cartilage, in particular the weight-bearing regions, was significantly correlated with abnormal anterior tibial translation and abnormal internal tibial rotation, in ACL-injured subjects at one year after their ACL reconstruction.

These results suggest that cartilage damage after acute knee injuries can be risk factors for predisposing these knees to OA. Abnormal kinematic changes following ACL reconstruction appear to lead to accelerated cartilage degeneration. Quantitative  $T_{1\rho}$  can probe these degenerations as early as one year post surgery. In fact, ACL-injured knees may serve as a valuable *in vivo* model for “early OA,” and, due to its sensitivity to proteoglycan loss,  $T_{1\rho}$  can be an extremely valuable tool for evaluating and monitoring early degeneration in such joints.

## Summary

$T_{1\rho}$  quantification in cartilage can provide valuable information related to biochemical degeneration of the cartilage matrix prior to morphological change demonstrated with conventional MRI. Because these techniques will be able to detect cartilage damage at a stage when changes are potentially still reversible,  $T_{1\rho}$  quantification in cartilage may have significant clinical implications, allowing opportunities for early intervention or prevention of OA.  $T_{1\rho}$  quantification requires no contrast agent injection and no special hardware. Technical challenges of  $T_{1\rho}$  quantification include relatively high energy deposited into tissue during the scan and relatively long acquisition times. Ongoing efforts at UCSF



**Figure 5.** A, B, and C shows a color-coded  $T_{1\rho}$  map overlaid on 3-T magnetic resonance images, demonstrating the increased  $T_{1\rho}$  relaxation times along the posterolateral aspect of the tibial plateau at the site of the tibial plateau bone bruise (white arrow). The mean  $T_{1\rho}$  value of the cartilage directly over the bone bruise was  $60.2 \pm 13.7$  ms, whereas the mean  $T_{1\rho}$  value of the remaining cartilage was  $37.5 \pm 14.3$  ms. D is an arthroscopic image demonstrating Outerbridge grade-1 softening of the articular cartilage overlaying the posterolateral aspect of the tibial plateau with a focal area of grade-2 fissures in the region of the bone bruise (black arrow).

Radiology include further technical development, exploration of the relationship among cartilage, bone, and meniscus in osteoarthritis, between cartilage health, gait and physical activities, between imaging measures and genetic profiles in degenerative cartilage, and eventually, clinical translation of the techniques developed.

Xiaojuan Li, PhD, is an associate professor in residence, Department of Radiology and Biomedical Imaging. Eric T. Han, MS, was research manager at the Applied Science Laboratory, GE Healthcare. Richard Souza, PT, PhD, is an assistant professor in residence, Department of Physical Therapy and Rehabilitation Science, and Department of Radiology and Biomedical Imaging. Thomas M. Link, MD, PhD, is a professor in residence, the Clinical Director of MQIR and the Chief of Musculoskeletal Radiology. C. Benjamin Ma, MD, is an associate professor in residence, and the Chief of Sports Medicine at the Department of Orthopaedic Surgery. Sharmila Majumdar, PhD, is a professor in residence, the director of the Musculoskeletal and Quantitative Imaging Research Interest Group and the vice-chair of research for the Department of Radiology and Biomedical Imaging.

# Emerging Multivariate Analysis Methods for Multimodal MRI Studies of Neurodegenerative Diseases

Duygu Tosun, PhD, Yu Zhang, MD, Michael W. Weiner, MD, and Norbert Schuff, PhD

## Background

Neurodegenerative diseases such as Alzheimer's disease, frontotemporal dementia, amyotrophic lateral sclerosis, Parkinson's disease, and epilepsy often do not show characteristic brain lesions, which radiologists can identify. These disorders more often show patterns of atrophy as detected on structural MRI, or subtle changes using other MRI modalities such as perfusion, functional, or diffusion tensor MRI. For this reason, these images are analyzed quantitatively using image-analysis software packages rather than by visual assessment. Furthermore, this data is frequently analyzed using statistical methods. Major challenges in this field include how to use and analyze multiple MRI modalities together in an integrated fashion, how to extract the maximum information, and how to determine the added value of multimodal MRI for diagnosis. The following article focuses on the analysis of multimodality brain MRI data for studies of neurodegenerative diseases.

## Voxel-By-Voxel Multivariate Analyses

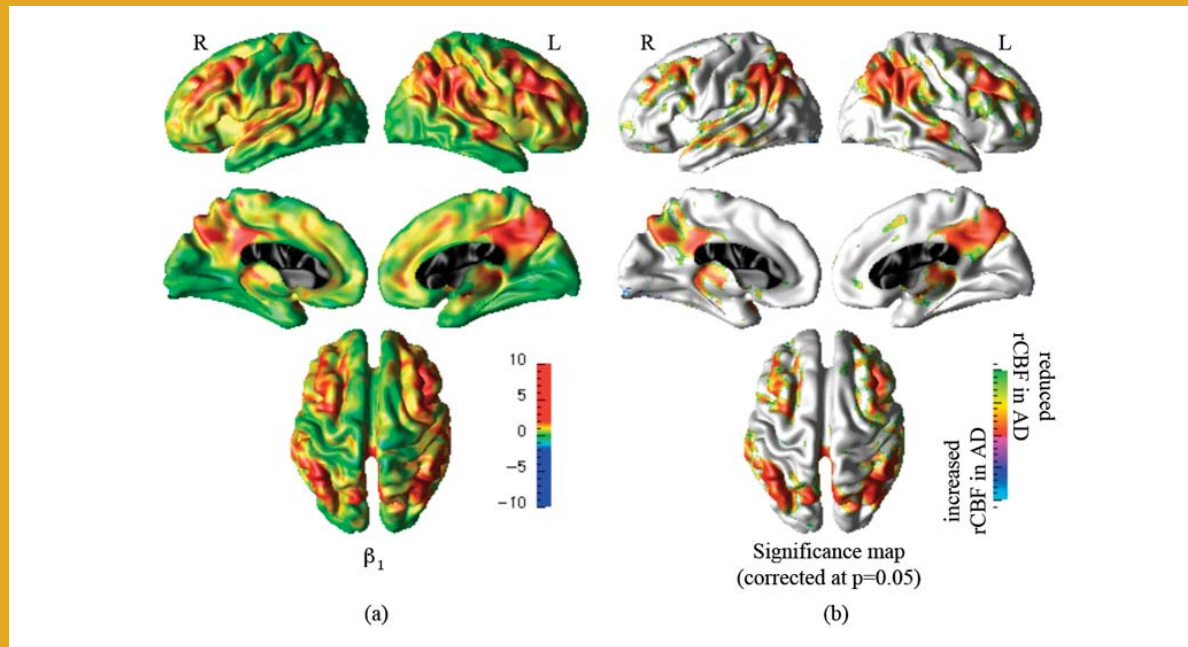
Structural MRI has been the method of choice for studies of the brain anatomy in neurodegenerative disease (ND), such as the pattern and rates of brain tissue loss in relation to memory deficits in Alzheimer's disease (AD) or behavioral impairments in frontotemporal dementia (FTD). In addition, perfusion-weighted MRI has been used to measure regional cerebral blood flow (rCBF), as an index of abnormal brain physiology. Diffusion-weighted MRI is used increasingly to assess the disintegration of white matter fiber bundles and the decline in brain connectivity in ND. Usually, the images are analyzed statistically, voxel-by-voxel and in a series of separate, univariate tests to determine if some observations are significantly different from the norm. Although such univariate tests provide an incredible amount of useful information, they neither reveal relations across brain regions nor relations among structural, physiological, and functional variations, which might further boost information for studies of ND.

In a first step toward extracting more information from multimodal MRI data, we developed statistical algorithms which test multiple observations jointly, voxel-by-voxel. For example, we recently demonstrated that the sensitivity in detecting altered brain metabolites in amyotrophic lateral sclerosis can be boosted by jointly evaluating multiple metabolite resonances observed with MR spectroscopic imaging. Similarly, to jointly evaluate multiple MRI modalities (e.g., structural and perfusion MRI), we developed a non-parametric statistical method to identify concordant or discordant correlations between structural and physiological variations. This approach revealed that certain brain regions in AD and FTD are systematically affected by both tissue loss and reduced rCBF, while other brain regions can exhibit tissue loss without significant alterations in rCBF or vice versa. This implies that the mechanisms underlying AD and FTD pathology are heterogeneous.

To determine the added value of joint analysis of structural and perfusion MRI for classifying ND, we developed an integrated framework to fuse structural and perfusion-weighted MRI data and a voxel-by-voxel analysis of the fused data based on logistic regressions. For the fusion of structural and perfusion-weighted MRI data, we applied the concept of cortical spatial normalization, in which an optical flow warp algorithm is used to match anatomically homologous cortical features across subjects to those of a reference cortical surface. We extended this approach to multimodal MRI by projecting variations within each MRI mode, i.e. structural and perfusion-weighted images, to the corresponding vertex on the cortical surface, providing a one-to-one correspondence across imaging modes on a surface mesh.

To test the added value of using structural and perfusion-weighted MRI data together for classifying AD patients and controls, we applied logistic regression analysis to determine sequentially the value of regional measures of cortical thickness alone, regional rCBF alone, and regional measures of cortical thickness and rCBF together. Logistic regressions of each MRI modality used separately showed that





**Figure 1.** Classification power of reduced rCBF for the classification of control subjects and AD patients; logistic regression coefficients (a), significance map corrected at  $p=0.05$  (b)

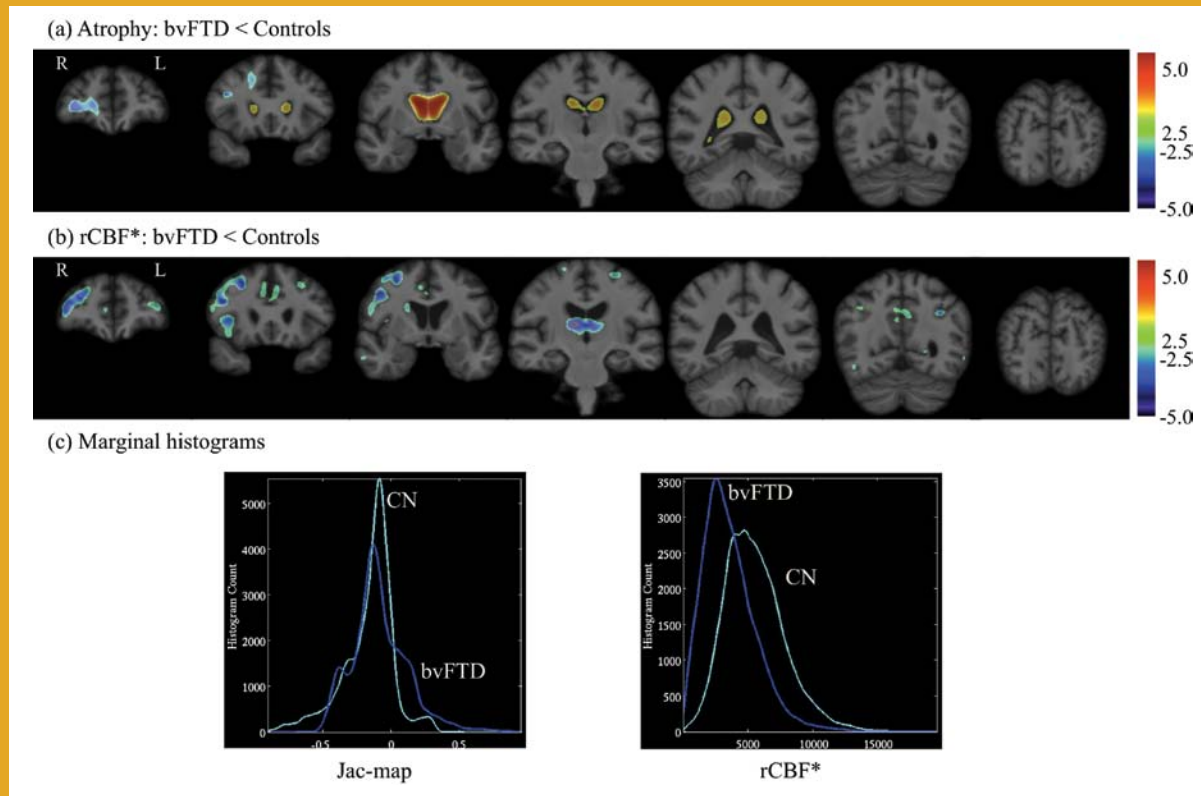
AD is represented by the well-established patterns of cortical thinning and rCBF reduction, affecting predominantly temporo-parietal brain regions. Logistic regressions of joint structural and perfusion-weighted MRI data indicated further that cortical thinning dominated the classification of AD in brain regions associated with early AD-related pathology without significant contributions from rCBF, as shown in Figure 1. However, significant contributions to the ability to classify AD also derived from positive interactions between cortical thinning and reduced rCBF in some brain regions, primarily involving the right superior temporal sulcus. The contribution of these interactions to a correct classification of AD could become even more important at early stages of the disease, such as classifying mild cognitive impairment, a clinical concept that is thought to represent a transitional stage from normal aging to AD.

Although these examples demonstrate the benefit of multivariate analyses for studies of ND, variations across brain regions, which likely carry additional information, are not yet incorporated. In the next sections, we describe emerging statistical concepts for the joint analysis of mul-

tivariate MRI data that take variations across image voxels into account.

### Multivariate Data-Mining Concepts

More recently, new algorithms for multivariate, large-scale data statistics have become available. These algorithms allow all image voxels from fused multimodal imaging data to be exploited simultaneously. This provides a way to study relations across both distal brain regions and imaging modalities. Under the general umbrella of multivariate canonical correlation analysis, several statistical concepts of large-scale data-mining have been proposed. The most promising approaches include joint independent components analysis, which attempts to identify the principal patterns in brain alterations, and partial least squares regression, which aims to identify the fundamental relationships among multiple variables, for example the relation between many image voxels and neurocognitive and neurobehavioral measures. In the next section, we present initial results using some of these new data-mining concepts for multivariate analyses of multimodal brain MRI data.



**Figure 2.** The spatial extent of the dominant joint component's (a) brain atrophy (tissue loss measured by Jacobian determinate, Jac-map, of the spatial normalization deformation field) and (b) rCBF features at  $z=2.5$  threshold overlaid onto the unbiased, average structural brain image. (c) Marginal histograms for the Jac-map and rCBF measures.

## Applications

**Joint Independent Components Analysis:** We used jICA to identify the principal components of joint structural and perfusion-weighted MRI variations in patients diagnosed with behavioral variant FTD and healthy elders. While regular univariate tests revealed the typical pattern of widespread brain atrophy and hypoperfusion of FTD, involving primarily the frontal lobe regions, the jICA identified additional links between structural and physiological variations in specific brain regions (Figure 2). These brain regions defined by jICA yielded a larger separation between FTD patients and controls than brain regions defined by regular univariate tests. Whether structural and perfusion-weighted MRI contributed equally to the improvement in classification of FTD or structural MRI dominated the classification—as seen in AD—still needs to be determined. Nonetheless, the findings demonstrate the power of jICA

to effectively evaluate multimodal brain imaging data and to capture unique morphological and physiological signatures that may open new avenues for imaging and dementia research.

## Relational Analysis Of White and Gray Matter Variations

In another multimodal imaging study, which included structural and perfusion-weighted MRI as well as diffusion-weighted MRI, we compared the extent of regional abnormalities between AD and FTD across MRI modalities as well as across gray matter and white matter. To elucidate variations across MRI modalities as well as tissue types, we designed a statistical approach, termed joint relational analysis. This joint assessment of MRI modalities across brain tissue types showed that FTD is associated with a greater extent of white matter damage than AD at mild disease severity. This distinction between FTD and AD gradually disappears

as the severity of each disease progresses. Furthermore, in FTD the magnitudes of gray matter loss and white degeneration exceeded the magnitude of diminished gray matter perfusion, whereas in AD, all three MRI measures exhibited similar levels of abnormality. The difference in multimodal MRI between FTD and AD is illustrated in Figure 3. Taken together, the results suggest that FTD and AD differ with respect to tissue specific damage, in addition to their respective characteristic regional patterns of brain alterations.

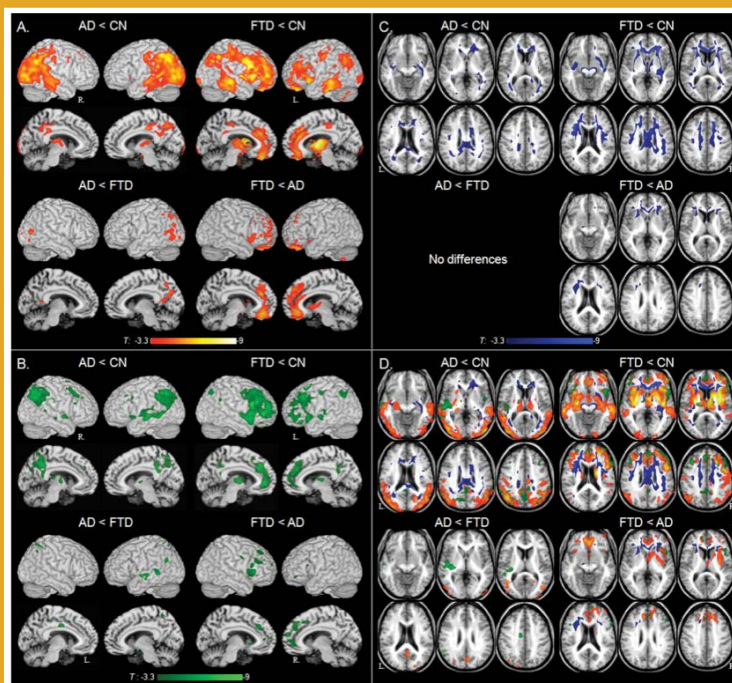
### Future Directions

Although our attempts for joint analyses of multimodal MRI data are just beginning, the gain in information is highly encouraging. However, more work needs to be done. Our current concepts for joint analyses still fall short of incorporating spatial correlations among brain regions. Although cross-correlation tests have been developed for regional relations within a single image modality as a general guideline, generalizing these tests to multimodal imaging is challenging because of the high data dimensionality, large number of multiple statistical testing, and daunting computational requirements. Graphical methods, which treat brain regions as knots and spatial relations as edges, potentially provide an

alternative to cross-correlations. Another major challenge is the development of methods for single-subject classification, the ultimate goal for imaging as a diagnostic tool. Here, advances in machine learning algorithms, such as support vector machines and a Bayesian extension called relevance vector machines, which can be trained on joint analyses of multimodal MRI data, provide promise for single-subject classification.

In summary, we demonstrated that joint analyses of multimodal MRI data provide unique and complementary information compared to conventional univariate analysis. The gain in information opens new avenues for brain imaging and has huge potential for improved early detection, differential diagnosis, and tracking of neurodegenerative diseases.

*Duygu Tosun, PhD, is an associate research scientist and Yu Zhang, MD, is an assistant specialist with the Center for Imaging of Neurodegenerative Diseases at the San Francisco VAMC. Norbert Schuff, PhD, is a professor at CIND and in the Department of Radiology and Biomedical Imaging, UCSF; Michael W. Weiner, MD is the director of CIND and a professor in the Department of Radiology and Biomedical Imaging, UCSF.*



**Figure 3.** Significance maps of systematic brain abnormalities in FTD and AD patients relative to control subjects (AD<CN and FTD<CN) and direct comparisons between AD and FTD (AD<FTD and FTD<AD). (A) GM loss (warm color) and (B) GM hypoperfusion (green color) overlaid on a surface rendered brain template. (C) Reduced WM FA (blue color) in AD or FTD overlaid on an axial brain template. (D) Overlay of the abnormal distributions together. The significant threshold was  $P_{\text{uncorrected}} < 0.001$  for all voxelwise tests. Color scales indicated ranges of significance (T-scores) upon the P threshold.

## Multi-Parametric Anatomic, Functional, and Hyperpolarized Micro-Imaging at Ultra-High Field (14T)

Kayvan R. Keshari, PhD, Subramaniam Sukumar, PhD, Robert Bok, MD, PhD, Mark Van Criekinge, MS, Jason Crane, PhD, David M. Wilson, MD, PhD, Sarah Nelson PhD, Daniel B. Vigneron, PhD, and John Kurhanewicz, PhD

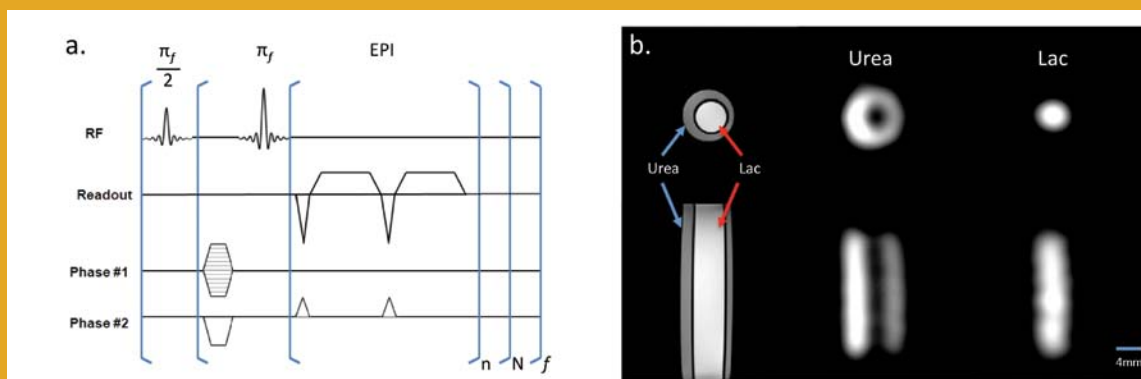
### Introduction

Hyperpolarized magnetic resonance metabolic imaging using dissolution dynamic nuclear polarization (DNP) is an emerging field of MR research poised to make an enormous impact in diagnostic radiology. Through DNP enhancements in the realm of five orders of magnitude, metabolic imaging studies can capture differences in the metabolism of benign and neoplastic tissues in a matter of seconds. In recently published studies performed on a 3T clinical scanner, the metabolism of hyperpolarized [ $1\text{-}^{13}\text{C}$ ]pyruvate was shown to not only discriminate cancer from benign tissue, it also provided measures of aggressiveness and response to therapy. These exciting findings, as well as the development of other hyperpolarized probes, has increased interest in using the many well-characterized murine models available to develop hyperpolarized biomarkers for a variety of human diseases.

To assess physiology and metabolism non-invasively in preclinical murine models of human disease, high-spatial resolution anatomic and functional imaging data are

required to correlate with dynamic hyperpolarized imaging results. To accomplish this, we developed a multi-parametric imaging approach using a new wide-bore, 14T micro-imaging spectrometer, funded by the National Institutes of Health and housed within the Biomedical NMR lab, a Department of Radiology and Biomedical Imaging core imaging facility. The bore size is large enough for murine models and the imaging system has all of the auxiliary anaesthesia, animal handling, and monitoring equipment needed to routinely perform *in vivo* studies. This ultra-high field, micro-imaging spectrometer is also equipped with multi-nuclear channel excite and receive capabilities, fast (100  $\mu\text{sec}$ ) rise time, strong gradients (100 G/cm), and is positioned adjacent to an NIH-funded Oxford Instruments Biotools HyperSense™ Polarizer.

The HyperSense Polarizer can polarize a variety of  $^{13}\text{C}$ -labelled probes, providing NMR signals from the probe and its metabolites that are >15000 times the thermal signal at 14T. This unique combination of high field micro-imaging spectrometer and DNP polarizer provides



**Figure 1.** (a) Diagram of 3D, frequency-specific imaging pulse sequence utilizing both frequency-specific  $90^\circ$  and  $180^\circ$  pulses. (b) Phantom images demonstrating the application of the 3D, frequency-specific imaging sequence with a corresponding reference  $^1\text{H}$  gradient echo image. The inner tube contains  $4\text{M}$  [ $1\text{-}^{13}\text{C}$ ]lactate, while the outer tube contains  $4\text{M}$   $^{13}\text{C}$  Urea.  $f$  = frequency,  $N$ ,  $n = 12$  or  $16$ , resolution of  $1.25\text{mm} \times 1.25\text{mm} \times 1.25\text{mm}$ , Lac = lactate.



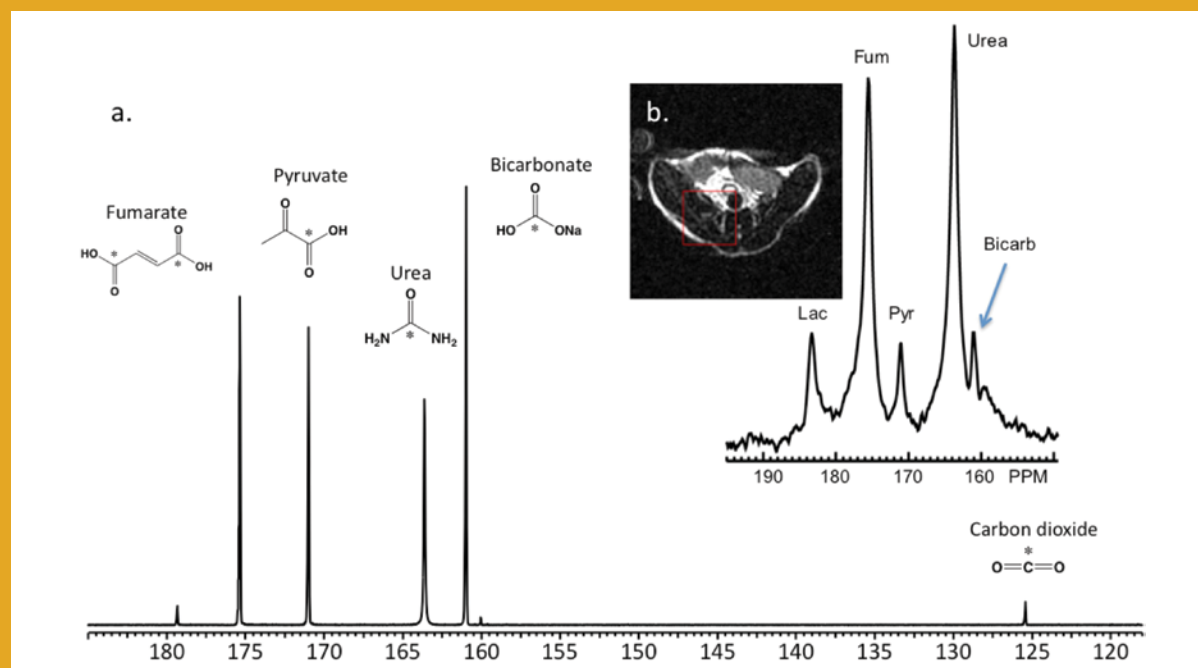
the sensitivity necessary to obtain high-spatial- and temporal-resolution anatomic and functional images (dynamic, contrast-enhanced images and diffusion-weighted images), and hyperpolarized  $^{13}\text{C}$  MR data from murine models. MR imaging at 14T, particularly  $^{13}\text{C}$ -spectroscopic imaging, presents a number of technical challenges. These include having the requisite field homogeneity, RF power and coils, and imaging sequences to perform the studies successfully. We met these challenges and developed a multi-parametric ( $T_2$  MRI, DCE, DWI) MR imaging protocol, similar to what is used clinically, to study new hyperpolarized- $^{13}\text{C}$  probes in a transgenic mouse model of prostate cancer.

### Hyperpolarized- $^{13}\text{C}$ MR Sequence Development at 14T

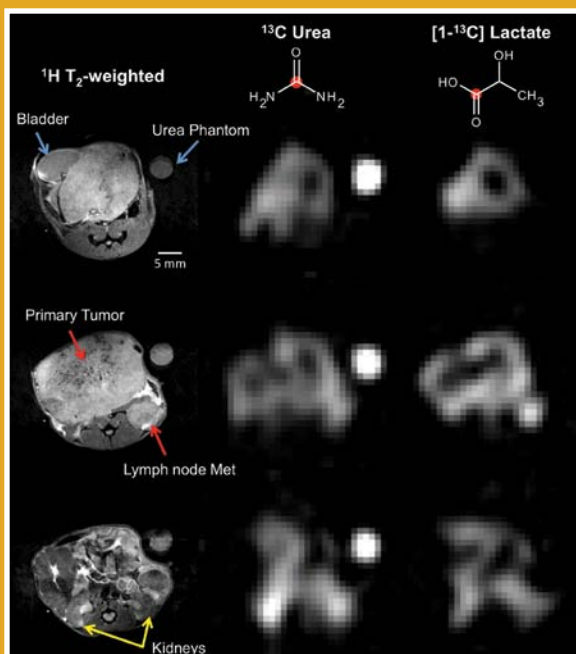
Due to the non-renewable nature of the magnetization and fast  $T_1$  decay, signal sampling needs to minimize the acquisition time and the number of excitation pulses, and maximize the retention of polarized signal. After a  $^{13}\text{C}$  probe is hyperpolarized, it is quickly brought to a liquid state at physiologic conditions for injection into an animal. Hyperpolar-

ized- $^{13}\text{C}$  probes are designed to have long spin-lattice ( $T_1$ ) relaxation times, because this governs both the probe's ability to polarize and the decay of the signal once it is removed from the polarizer. This, along with other spin-relaxation mechanisms, metabolism, and RF saturation, leads to an irreversible loss of the hyperpolarized signal. Additionally, high-field studies are hindered by increased chemical shift dispersion and  $T_2^*$  effects. Due to these obstacles, special pulse sequences are needed to sample the magnetization quickly and efficiently.

Single-shot methods, such as echo-planar imaging (EPI) and spiral imaging can provide high spatial and temporal resolution with a single excitation. They also can be easily interfaced into traditional excitation schemes. A frequency-specific, 3D volume-imaging sequence was designed with a total time of 180ms, allowing for both frequency- and temporal-specificity (1a). This sequence is suitable for multi-hyperpolarized probe studies, utilizing  $180^\circ$ -refocusing pulses to minimize  $T_2^*$ -related signal loss and artifacts. Adapted from a  $^1\text{H}$  3D GRASE approach,



**Figure 2.** (a) Multi-compound polarization of four  $^{13}\text{C}$  biomolecules of interest: fumarate, pyruvate, urea, and bicarbonate *in vitro*. These data were obtained in a 10 mm NMR tube 60 s following dissolution at 11.7T. Levels of polarization achieved were similar to those obtained for the individual compounds performed using an optimized microwave frequency.  $T_1$ 's in solution were similar to those obtained for the separate species. (b) Multi-compound polarization *in vivo* performed in a TRAMP mouse model at 3T.



**Figure 3.** Co-polarization of  $[1-^{13}\text{C}]$ pyruvate and  $^{13}\text{C}$  urea in a late-stage transgenic model of prostate cancer (TRAMP) mouse with corresponding  $T_2$ -weighted anatomic imaging. Slices through the tumor region included the bladder (which has no signal), a slice of tumor with a region of necrosis demonstrating differences in metabolism and perfusion in that region, as well as the kidneys, showing high perfusion relative to the tumor are shown.  $[1-^{13}\text{C}]$ pyruvate and  $^{13}\text{C}$  urea were co-polarized similar to previous studies resulting in concentrations of 80mM for each compound (350 $\mu\text{L}$ , pH=7.5 in 40mM TRIS buffer). The phantom contained 8M  $^{13}\text{C}$  urea in glycerol for both a frequency and spatial reference.

this  $^{13}\text{C}$  imaging sequence requires high performance gradients and accurate  $180^\circ$  pulses, which have been achieved on the Varian wide-bore 14T micro-imager.

Figure 1b demonstrates the frequency specificity of the sequence, with good separation of lactate and urea in a phantom acquired at 14T. Since this acquisition scheme requires only 180ms to acquire a 3D volume, blurring resulting from flow and diffusion is minimized as compared to standard spectroscopic imaging sequences.

#### Co-Polarization - Measuring Perfusion and Metabolism

To date, most hyperpolarized  $^{13}\text{C}$  MR studies in preclinical models have explored the metabolism of  $[1-^{13}\text{C}]$ pyruvate and its conversion to  $[1-^{13}\text{C}]$ lactate. In recent studies, methods have been developed to polarize compounds simultaneously, making it possible to visualize multiple metabolic pathways and other physiologic processes in the same imaging acquisition (Figure 2). This method has been extended to the polarization of four compounds (Figure 2a) and their simultaneous injection into a mouse at 3T to observe all four resonances (Figure 2b). The co-polarization of  $[1-^{13}\text{C}]$ pyruvate and  $^{13}\text{C}$  urea is routinely performed to provide simultaneous measurements of metabolism and perfusion.

In a set of preliminary studies,  $[1-^{13}\text{C}]$ pyruvate and  $^{13}\text{C}$ -urea were co-polarized and injected into a transgenic model of prostate cancer mouse (TRAMP). Hyperpolarized images obtained at 44secs post-injection using 3D frequency-specific imaging and the corresponding  $T_2$ -weighted anatomic images shown in Figure 3, demonstrate heterogeneous perfusion based on hyperpolarized- $^{13}\text{C}$  urea distribution and  $[1-^{13}\text{C}]$ pyruvate metabolism to lactate in this late-stage prostate tumor. Consistent with prior 3T hyperpolarized  $[1-^{13}\text{C}]$ pyruvate studies of the TRAMP model, high levels of hyperpolarized lactate were observed in the primary tumor as well as in regions of lymph node metastasis. The high spatial resolution of the anatomic (0.16mm x 0.16mm x 0.25mm) and hyperpolarized-MR images (1.25mm x 1.25mm x 1.25mm) allows a better assessment of the heterogeneous spatial distribution in perfusion and metabolism. Interestingly, while perfusion and metabolism correlate (i.e., high perfusion and conversion to lactate) in some regions of the tumor, there other regions have low perfusion and high lactate. This mismatch between metabolism and perfusion has been observed in combined FDG PET and perfusion CT imaging studies. It has been postulated that regions of low perfusion and high metabolism are correlated to the ineffectiveness of chemotherapy in tumors.

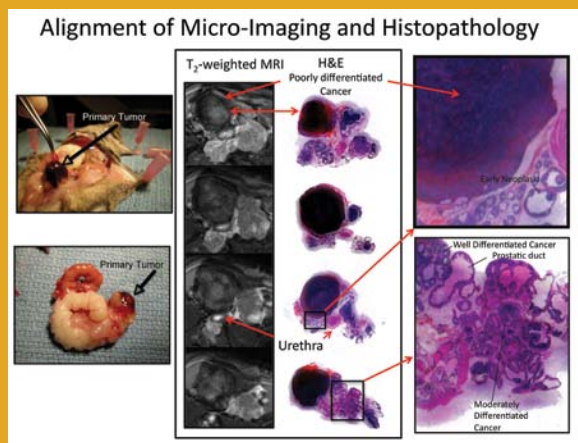
### Combining Multi-Parametric Micro-Imaging with Step-Section Histopathology

In order to better understand this mismatch between metabolism, perfusion, and cancer aggressiveness, a study was undertaken to correlate the MR findings with hypoxia, pathologic grade, and proliferative status. In this study, TRAMP mice were imaged at 14T using a high-spatial resolution  $T_2$ -weighted sequence to provide an anatomical reference, a multi-slice diffusion-weighted imaging sequence to calculate apparent diffusion coefficient (ADC) maps, and 3D, frequency-specific images of co-polarized  $[1-^{13}\text{C}]$ pyruvate and  $^{13}\text{C}$  urea to provide metabolic and perfusion images.

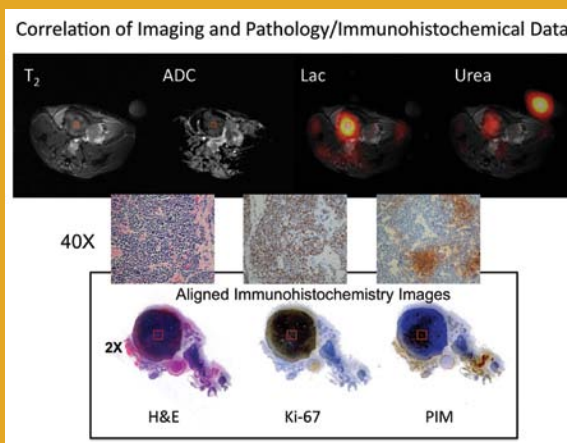
After imaging, the entire tumor and seminal vesicles were surgically removed, embedded in paraffin, and step-sectioned at the same thickness as the MR data. The  $T_2$ -weighted images were aligned to the hematoxylin- and eosin-stained histological sections (Figure 4), providing a direct correlation with adjacent sections stained for Ki-67 (a nuclear stain for proliferation) and pimonidazole (PIM, a stain for hypoxia). (Figure 5) In this moderate stage, regions of poorly, moderately, and well-differentiated tumor were identified and correlated with the hyperpolarized MR data. Similar to previous reports, regions of poorly differentiated tumor had higher levels of hyperpolarized lactate relative to well-differentiated cancer. Additionally, there was decreased ADC in the tumor relative to surrounding muscle, and

larger reductions in ADC in regions of late pathologic stage tumor. These regions also demonstrated high Ki-67 and PIM staining, indicating high rates of cellular proliferation and the presence of hypoxia. However,  $^{13}\text{C}$  urea images were fairly homogeneous across the tumor, even though there were regions with high levels of hypoxia. In ongoing studies, quantitative comparisons of the pathologic, immunohistochemical, and hyperpolarized MR data from TRAMP mice of varying pathologic stage are being conducted to establish the inter-relationship between hyperpolarized metabolic and perfusion biomarkers, pathologic grade, proliferation, and tumor micro-environment.

*Kayvan R. Keshari, PhD is a postdoctoral scholar; Subramaniam Sukumar, PhD is a specialist; Robert Bok, MD, PhD, is an assistant adjunct professor; Mark Van Crielinge, MS, is an engineer; and Jason Crane, PhD is a programmer analyst; David M. Wilson, MD, PhD is an assistant professor in residence in the Neuroradiology Section; Sarah Nelson PhD, is the Margaret Hart Surbeck distinguished professor in Advanced Imaging and director, Surbeck Laboratory; Daniel B. Vigneron, PhD is a professor in residence and co-director, MRI/MRS Specialized Resource Group; and John Kurhanewicz, PhD, is a professor in residence and co-director, Prostate Cancer Research Interest Group in the Department of Radiology and Biomedical Imaging.*



**Figure 4.** Representative gross pathology of a moderate-stage TRAMP prostate tumor.  $T_2$ -weighted images are shown aligned to hematoxylin and eosin (H&E) sections. Regions of well-differentiated and poorly differentiated tissue are readily visible.



**Figure 5.** Representative  $T_2$ -weighted, apparent diffusion coefficient (ADC), hyperpolarized lactate (Lac) and urea images are shown with corresponding histopathology. Regions of poorly differentiated, highly proliferative and hypoxic tissue appear to spatially correlate to increased lactate signal with similar perfusion and decreased ADC values.

## A Replacement Year

By Robert G. Gould, ScD

While less dramatic than last year's enormous expansion in magnetic resonance imaging projects, we completed a number of capital projects and started several new ones, mostly to replace equipment. In spite of the challenging times, the UCSF Medical Center continues to invest in imaging equipment for the department, although we must carefully plan and prioritize our replacement and expansion needs. In the past year, we installed equipment at all our imaging sites on both the inpatient and outpatient sides.

We made notable upgrades to all five of our GE VCT 64-slice CT scanners, located at Parnassus, Mt. Zion, and China Basin. These scanners all have a new reconstruction program, ASIR (Adaptive Statistical Iterative Reconstruction), which can significantly lower patient dose. While the department has always strived to use low-dose imaging factors, this new reconstruction enables further dose reductions without loss in image quality.

### **Parnassus Campus**

With the two new magnets installed in Moffitt, we were able to focus on other modalities. We replaced the two body interventional angiographic rooms (Rooms 8 and 9) sequentially, with only a week between the startup of one new room and the beginning of work to replace the other room. (The rooms share a common control area.) Both now contain identical equipment, a single-plane Philips Allura FD20 ceiling-mounted C-arm. These systems have a flat panel detector and, in addition to DSA, can rotate the C-arm to acquire and reconstruct cross-sectional images. Both systems have all available dose-reduction features, including low pulse rate fluoroscopic imaging, intelligent beam filtering, and an ability to electronically adjust the collimation based on the last image hold. In Room 8, which previously held a floor-mounted C-arm, we changed the table orientation, relocated the door, and moved the equipment racks out of the room to improve workflow and usability of the imaging equipment. Image quality has been excellent.

The Parnassus area also had almost a third of its aging ultrasound equipment fleet replaced, with the purchase of five new units. The new ultrasound units are all Siemens Acuson S2000 systems. These units communicate wire-

lessly, so a patient worklist is available to the technologist and images are sent to PACS without connecting to a network port.

The department continued to expand its digital mobile X-ray units, bringing to five the number of Fuji Go units. These mobile radiographic systems have a CR reader integral to the unit, so that a digital image is produced at the site of acquisition. Standard-size CR cassettes can be used, providing flexibility in clinical use. Two of these units have child-friendly decorations for use in the pediatric wards. These systems connect to the PACS wirelessly.

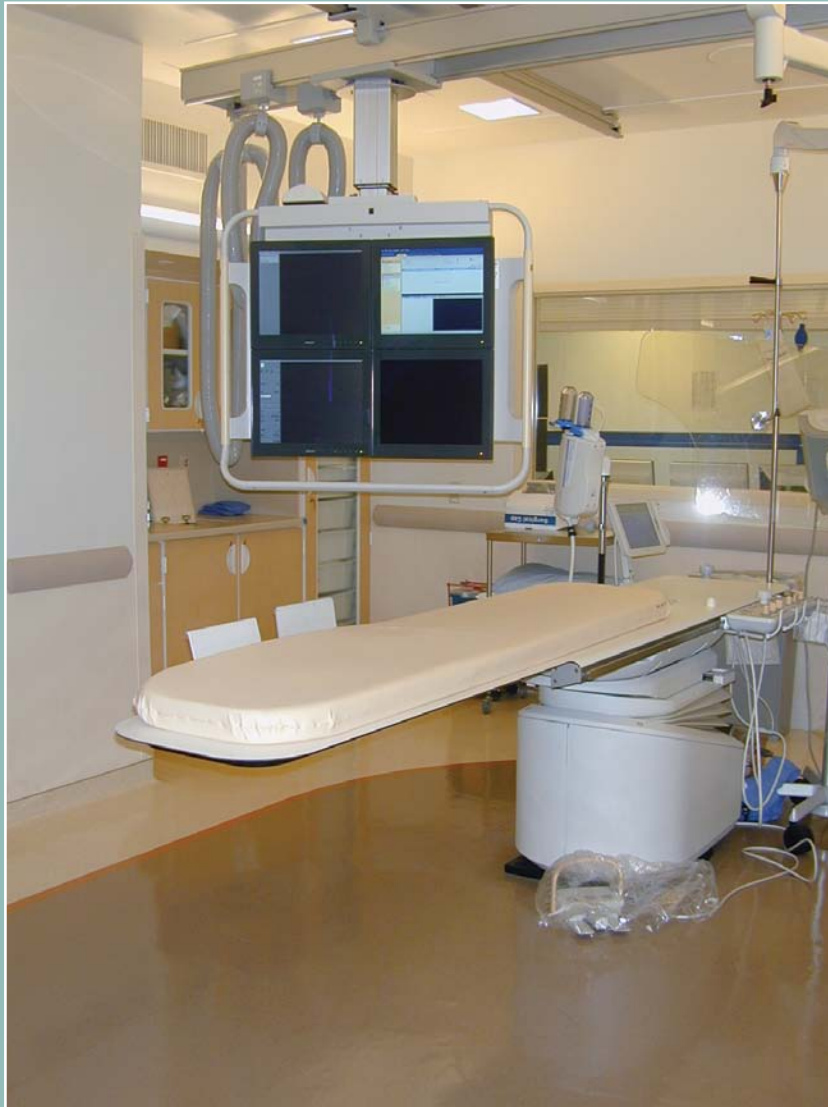Two approved projects are moving through the construction planning stage. A GE 750HD scanner with dual-energy capabilities will replace the 8-slice CT scanner in Long. This scanner will have ASIR hardware and software; the project should be complete by summer of 2011. We also plan to replace two nuclear cameras in Long Hospital with a single SPECT CT unit, the GE Discovery 670. This machine, a new offering from GE, has a 16-slice CT scanner combined with the SPECT gamma camera.

### **Mt. Zion Campus**

Remodeling the Mt. Zion mammographic reading room is complete and the mammographic section is using a new mini-PACS, Sectra IDS7, to display and interpret images. The Sectra PACS can display all types of images, including MR, and has access to reports of prior studies, features that the previous display system lacked. The size of the reading room has been expanded and the workflow significantly improved.

Planning for the replacement of the inpatient CT scanner at Mt. Zion, a 4-slice unit that is the oldest CT at UCSF, is nearing completion, with the start of construction expected in the first quarter of 2011. The new scanner is the GE 750HD. It will have dual-energy imaging capabilities as well as ASIR equipment. We are also in the planning stage for replacement of the body interventional room. We will install a Siemens Artis Zee ceiling-mounted C-arm with rotational capabilities for cross-sectional imaging. We anticipate completion of this project in the second half of 2011.





The new interventional Angiographic Room located on the third floor of Moffitt Hospital.

### China Basin

Two new nuclear gamma cameras, one already installed and one to be installed before the end of 2010, add to the nuclear imaging capabilities at China Basin. This site has PET-CTs, a SPECT camera, and a cyclotron, making this the primary location for out-patient nuclear medicine studies. The installed unit is a GE Ventri cardiac SPECT camera, coupled to the existing GE VCT 64-slice CT. This camera is a cardiac-only device. This allows other types of nuclear imaging studies to be scheduled on the existing SPECT camera at this location. The additional camera installation will be a second GE Infinia Hawkeye, a general purpose SPECT system.

### Upcoming

In this fiscal year we have been approved for several projects at Mt. Zion, namely the replacement of a radiographic room located in a medical office building and the replacement of the inpatient nuclear camera. We also received funds to continue replacing aging ultrasound units. Finally the last <64-slice at UCSF, located on the third floor of Long Hospital, was approved for replacement.

*Robert G. Gould, ScD, is a professor of radiology in residence and vice-chair for Technology and Capital Projects. He oversees the purchase of the department's capital equipment.*

# State-of-the-Art Women's Imaging Services for Breast Cancer Screening and Evaluation at UCSF

Bonnie N. Joe, MD, PhD

A two-year effort has turned the vision of a new Women's Imaging Section at UCSF into reality. A planning committee of staff and faculty, led by Bonnie N. Joe, MD, PhD, planned and implemented major improvements, resulting in a vibrant and modern Women's Imaging Section with integrated clinical and research activities. The section provides comprehensive imaging services to better serve the needs of our patients and referring providers.

The plan emphasized workflow, from scheduling to imaging to reading and reading.

### Full-Field Digital Mammography (FFDM) Implemented

The UCSF Women's Imaging Section went fully digital in March 2009, with the replacement of the last two analog mammography units with Hologic Selenia systems. One of the new systems also enables upright stereotactic biopsies. The added efficiency afforded by 6 FFDM units at Mt. Zion allows us to consolidate all mammography services at the Mt. Zion Cancer Center. Now, a woman can get an appointment within one to two days.

### Breast Imaging Nurse Added

We added a dedicated nurse in September 2009. She acts as a physician extender, patient advocate, and patient care coordinator, to name just a few of her many roles. This nurse and a dedicated scheduler ensure that procedures are properly and efficiently scheduled and that patients are informed about their procedures in advance. Having a dedicated nurse streamlined services and increased the overall satisfaction of patients, physicians, and radiology staff.

### Reading Room Redesigned

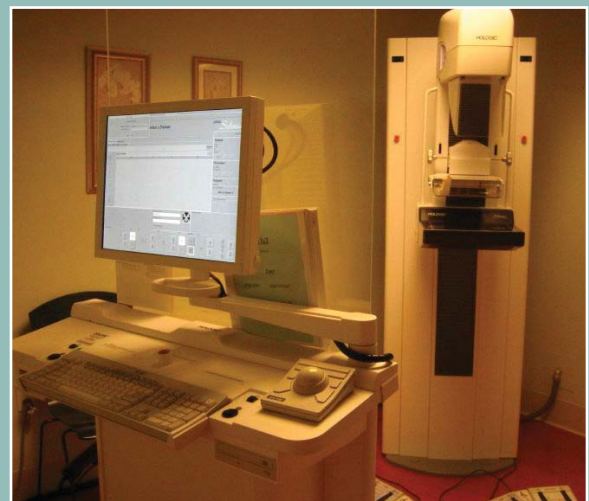
The women's imaging reading room underwent major construction during the fall of 2009. Working extensively and collaboratively with design and construction, a dedicated architect, and radiology faculty and staff, we created a new reading room to address the needs of the expanding service. This new space provided added functionality while remaining in the same footprint on the second floor of the

Cancer Center. The new design added a consultation area for private discussions between patients and clinicians, a separate nurse/scheduler office, and features adjustable tables, lighted keyboards and keypad for better ergonomics.

### SFMR Mammographic Reporting System Retired

After nearly two years of planning, we made a relatively smooth transition in June 2010 to a new breast imaging reporting system created by a local company, Jambayang Research in San Jose. It replaces the infamous San Francisco Mammography Registry mammographic reporting system, which ran for many years on a computer with 512k of RAM. The new system, developed with initial funding from the National Institutes of Health, provides the same functionality of the old SFMR system. It also adds reporting and tracking capabilities for breast ultrasound and MRI data.

The new system is compatible with the National Mammography Database (NMD). Funding for this transition was partially provided by the 2010–2011 Dickson Emeritus Professorship Award, given to Professor Emeritus Edward A. Sickles, MD, FACR. His award paid for migrating data



Digital mammography unit

gathered from the old SFMR database and creating a new database within the breast imaging reporting system. This new database can be used for clinical audits and for research.

### **National Mammography Database Linked**

As a longstanding member of the Breast Cancer Surveillance Consortium (<http://breastscreening.cancer.gov/about/>) it was a natural decision to also participate in the National Mammography Database (NMD) (<https://nrdr.acr.org/portal/NMD/Main/page.aspx>), particularly since the national Mammography Database Committee is chaired by Sickles. Officially launched in July 2009, the NMD is a data registry that provides comparative information for mammography practices which can be used for national and regional benchmarking. Physicians participating in Maintenance of Certification for the American Board of Radiology can use the NMD registry as a practice quality improvement project.

### **Dedicated Mammography Mini-PACS Installed**

The move to digital mammography meant we needed “more than a digital viewbox.” After much planning and analysis, we started implementing a new Mammography mini-ACS from Sectra Medical Systems in January 2010. This workstation can display breast ultrasound and breast MRI and mammography images, and can be customized specifically for mammography workflow. Our goal is to integrate the mammography workstation with the radiology and hospital information systems, breast imaging reporting system, breast MR CAD, and voice recognition.

### **Breast MRI Enhanced**

UCSF was the first institution in Northern California to get a large-bore, whole-body 3T MR scanner capable of performing breast MRI. We perform high resolution breast MRI at 1.5T on a Signa® HDx system from GE Healthcare, Inc., and 3T scans on a MAGNETOM® Verio from Siemens Medical Solutions, Inc.. Both use dedicated multi-channel breast coils from Sentinelle Medical, Inc.

Our volume of breast MR and breast MR biopsies has been steadily increasing since 2007. Part of this increase relates to improved efficiency and access of breast MR biopsy. In the past, breast MR biopsies could take upwards of two hours to perform and were difficult to schedule in a timely fashion. Thanks to process improvements and additional nursing support for biopsy procedures, routine breast MR biopsies are now performed in 30 to 45 minutes. Dedi-



Bonnie N. Joe, MD, PhD, chief,  
Women's Imaging, Mt. Zion  
Medical Center

cated scanner time on Tuesday and Thursday mornings is helping us accomplish our goal of performing breast MR biopsies within one week of the initial breast MRI scan.

### **Breast Imaging Research Supported**

Breast imaging research is closely integrated into our clinical practice. Guided by the Breast Research Interest Group co-led by Nola Hylton, MD, and Joe, research efforts cover a broad range of applications and imaging modalities.

Current programs include breast cancer screening and surveillance, diagnosis and tissue characterization for risk assessment, cancer staging, and treatment response assessment. To date, the breast MRI research program has focused primarily on developing tumor assessment methods for pre-surgical staging and for measuring response to pre-operative treatment for both locally advanced breast cancer and early stage ductal carcinoma *in situ* (DCIS). In both areas, research in breast imaging at UCSF has led to multi-institutional collaborations such as the ACRIN 6657 breast MRI trial led by Hylton, research in quantitative X-ray mammography for breast density assessment (led by John Shepherd, MD), and optical imaging (led by Catherine Klifa, MD) are components of our comprehensive breast imaging research programs.

### **Acknowledgments**

All of these accomplishments were made possible through teamwork and support from many facets of our institution. The Women's Imaging Section physicians would like to acknowledge and thank the people who keep things running on a daily basis: our technologists and nurses, PACS and IT groups, the Breast Imaging Research Group, Mt. Zion film librarians and support staff, and our administrative staff.

*Bonnie N. Joe, MD, PhD, is an associate professor in residence and chief of Women's Imaging, Mt. Zion Medical Center, for the Department of Radiology and Biomedical Imaging.*

## Three New Section Leaders in 2010



### **Elicker Appointed Chief of Cardiac and Pulmonary Imaging**

In February 2010, Brett Elicker, MD, assistant professor of clinical radiology, accepted the position of chief of the Cardiac and Pulmonary Imaging Section.

“One of Brett’s goals for the section is nurturing a productive relationship with the Division of Cardiology,” said Chairman Ron Arenson, MD.

Elicker received his medical degree in 2000 from New York Medical College, New York, NY. He completed an internship in Internal Medicine at Kaiser Permanente in Santa Clara, Calif., followed by a diagnostic radiology residency at the Yale New Haven Hospital in New Haven, Conn. from 2001–2005. He came to UCSF in 2005 as a Clinical Fellow in Cardiac and Pulmonary Imaging and joined the faculty of Radiology and Biomedical Imaging in July 2006.



### **Hernandez Pampaloni Becomes Chief of Nuclear Medicine**

In January 2010, Miguel Hernandez Pampaloni, MD, PhD, accepted the position of chief of Nuclear Medicine.

Hernandez Pampaloni obtained his medical degree from the Complutense University School of Medicine in Madrid, Spain. He completed training in Nuclear Medicine at the San Carlos Hospital, Complutense University, followed by a PhD in 1998. Hernandez Pampaloni was a Postdoctoral Fellow in Cardiovascular Nuclear Medicine at the David Geffen School of Medicine at UCLA. He was a Clinical Research Fellow in PET Cardiology at the Imperial College of Medicine, London, England. He completed a residency in Nuclear Medicine and worked at the University of Pennsylvania School of Medicine in Philadelphia 2004 to 2009. He joined the UCSF Nuclear Medicine section as an assistant professor in residence in February 2009.



### **MacKenzie Appointed Chief of Pediatric Radiology**

John MacKenzie, MD, assistant professor of Radiology in residence, became chief of Pediatric Radiology in July 2010.

MacKenzie will be responsible for “preparing all aspects of the Pediatric Radiology Section for the new Children’s and Women’s Hospital at Mission Bay,” said Chairman Ron Arenson, MD.

MacKenzie graduated from the Albert Einstein College of Medicine in New York. He interned at the Hospital of the University of Pennsylvania, where he later trained in Musculoskeletal MRI. He was a Radiology resident at Brigham and Women’s Hospital and held a fellowship in Pediatric Radiology at Children’s Hospital of Philadelphia. He is board-certified in both Diagnostic and Pediatric Radiology. He previously was on the faculty of the Lucille Packard Children’s Hospital at Stanford University, where he was chief of Pediatric Musculoskeletal Imaging.



## New Faculty Appointments



### **Jesse Courtier, MD**

*Assistant Clinical Professor  
Pediatric Radiology*

Jesse Courtier received his medical degree from the University of Iowa College of Medicine in Iowa City, in 2003. After an internship in preliminary surgery at the University of Hawai'i, Courtier completed a four-year diagnostic radiology residency at the University of Kansas, Wichita. In 2009, he finished a one-year abdominal imaging fellowship at UCSF, followed by a pediatric radiology fellowship that was completed in 2010. As a member of the department's Radiation Oversight Committee, Courtier coordinated the creation of new pediatric CT guidelines. He is also

involved in medical education, serving on the Resident Education Committee as a pediatric radiology representative. Courtier says "I enjoy taking an active role in resident education and attempt to develop novel methods of teaching essential material in pediatric radiology." In July 2010, Courtier accepted an assistant clinical professor position in Pediatric Radiology, UCSF.



### **Michael D. Hope, MD**

*Assistant Professor in Residence  
Cardiac and Pulmonary Imaging*

Michael D. Hope earned his medical degree in June 2004 from Stanford University Medical Center in Palo Alto, Calif. The following year, he did a one-year internal medicine internship at California Pacific Medical Center

in San Francisco. In 2009, Hope completed a four-year diagnostic radiology residency at UCSF, followed by a one-year clinical fellowship in Cardiopulmonary Imaging, completed in 2010. Hope has extensive research experience, with 12 peer-reviewed publications. His primary research interest is MR blood flow imaging in the clinical management of patients with cardiovascular disease. Hope accepted a position as assistant professor in Cardiac and Pulmonary Imaging in July 2010.



### **Adam J. Jung, MD, PhD**

*Assistant Professor of Clinical  
Radiology  
Veterans Affairs Medical Center*

Adam J. Jung received his medical degree in 2003 from Texas A & M Health Science Center, College Station, Texas. In 2009, he completed a

four-year combined diagnostic radiology residency and PhD program at the University of Texas Health Science Center in San Antonio. From 2009-2010 he was a clinical fellow in the Abdominal Imaging section of the Department of Radiology and Biomedical Imaging at UCSF. Jung lists his primary areas of research interest as “looking at prostate cancer using multiparametric MRI techniques and high-frequency transrectal ultrasound” and is interested in “how these modalities compare when attempting to stage prostate cancers using surgical histopathology.” In July 2010, Jung accepted an assistant professor of clinical radiology position in Abdominal Imaging at the VAMC



### **Roland Krug, PhD**

*Assistant Professor in Residence  
MQIR/China Basin*

Roland Krug received his PhD in Medical Physics in 2003 from the German Cancer Research Center in Heidelberg, Germany. This was followed with

three years of postgraduate training as a postdoctoral fellow in the Department of Radiology and Biomedical Imaging at UCSF. Since 2006, Krug has been a research specialist in the Musculoskeletal Quantitative Imaging Research Group at China Basin. Krug's research interests include the technical development of magnetic resonance imaging methods, as well as advanced digital image processing algorithms. In particular, his research focuses on pulse sequence development and image reconstruction methods for *in vivo*, high-resolution MRI at high and ultra-high strengths (7 Tesla) to enhance image acquisition for quantitative bone, cartilage, and meniscus analysis. In addition to his research, Krug enjoys teaching and mentoring students. He has taught advanced principles of sequence programming and sequence implementations on GE scanners – a skill many graduate students and postdoctoral researchers need for their advanced projects. In July 2010, Krug accepted a position as assistant professor in residence in the Musculoskeletal and Quantitative Imaging Research group in the Department of Radiology and Biomedical Imaging.



### **David N. Sandman, MD**

*Assistant Professor of Clinical  
Radiology  
Musculoskeletal Imaging*

David Sandman attended medical school at Loyola University, Stritch School of Medicine, in Maywood, Ill., receiving his medical degree in 2003, and completing a one-year fellowship in internal medicine in 2004. He completed a diagnostic radiology residency at the University of Illinois at Chicago Medical Center and School of Medicine (2005-2006) and Rhode Island Hospital and Alpert Medical School of Brown University in Providence, RI. Sandman completed a one-year clinical fellowship in musculoskeletal radiology at the David Geffen School of Medicine, University of California, Los Angeles in 2010. He served as a consultant radiologist at St. Francis Medical Center in Lynwood, Calif. from 2009-2010. Sand-

man's research interests include MR evaluation of asymptomatic lateral collateral ligament complexes in the ankle and attempting to establish a prevalence of abnormal-appearing ligaments in asymptomatic subjects. Future interests include MR imaging of joint injuries with arthroscopic correlation. Sandman came to UCSF as an assistant professor of clinical radiology in July 2010.



**Thomas H. Urbania, MD**

*Assistant Professor of Clinical*

*Radiology*

*Cardiac and Pulmonary Imaging*

*San Francisco General Hospital*

Thomas H. Urbania attended the University of Pennsylvania School of Medicine, Philadelphia, receiving his medical degree in 2004. A one-year internship in medicine at Pennsylvania Hospital in Philadelphia followed. He completed a four-year diagnostic radiology residency in 2009 and a one-year Cardiac and Pulmonary Imaging fellowship in 2010 at UCSF. Interested in both teaching and research, Urbania says he is "interested in using

information technology to improve the practice of radiology and radiology education." Urbania accepted the position of assistant professor of clinical radiology in July 2010.



**David M. Wilson, MD, PhD**

*Assistant Professor in Residence*

*Neuroradiology*

After receiving his medical degree and PhD in a combined program at Columbia University, New York, in 2004, David M. Wilson did a one-year internship at the University of Hawai'i, Honolulu. Following this, Wilson completed a four-year diagnostic radiology residency at UCSF in 2009. He completed a one-year clinical instructorship in the section of neuroradiology in 2010. Wilson has published several peer-reviewed publications and many abstracts, and received The Margulis Society Resident Research Award in 2009. In July, 2010, Wilson accepted the position of assistant professor in residence.



**Dorota Jakubowski Wisner, MD, PhD**

*Assistant Professor in Residence*

*Women's Imaging, Mt. Zion*

Dorota Jakubowski Wisner earned her PhD in Physics (2002) and her medical degree (2004) from the University of California, Irvine. She completed a one-year internship at Scripps Mercy Hospital, San Diego, Calif., in 2005. This was followed by a four-year diagnostic radiology residency at UCSF from 2005-2009. In 2009, while a resident at UCSF, Wisner received the Lucy Frank Squire Distinguished Resident Award in Diagnostic Radiology from the American Association for Women Radiologists. In 2010, she finished a one-year clinical fellowship in Women's Imaging at UCSF. Wisner's areas of interest include cancer, breast, ductal carcinoma *in situ*, mammography, and ultrasound. Wisner accepted the position of assistant professor in residence, in the Women's Imaging section at Mt. Zion, in July 2010.

## Honors and Awards

### **Ronald L. Arenson, MD**

Keynote speaker at the American Board of Radiology Foundation Summit: "Improving Patient Care Through e-Communication in Imaging"

Keynote speaker, 2010 AUR-Philips Academic Faculty Development Program: "The Future of Academic Radiology"

Inaugural Theodore J. Castele, MD, Lecturer at Case Western Reserve University: "The Future of Academic Radiology"

### **David E. Avrin, MD, PhD**

Speaker, American Board of Medical Specialties at the White House-sponsored National Policy Forum in Arlington, Va.: "Aligning Method of Certification and Health Information Technology Policy and Implementation," March 2010

### **Valerie Cardenas-Nicholson, PhD**

Promoted to Associate Adjunct Professor

### **Peter W. Callen, MD**

Recipient, Outstanding Alumni Award 2010



Chairman Ron Arenson, MD, presents the Outstanding Alumni Award to Peter W. Callen, MD

### **Soonmee Cha, MD**

Co-recipient, Hideyo Minagi Outstanding Teacher Award, 2010

### **Jesse Courtier, MD**

Co-recipient, Outstanding Fellow/Clinical Instructor Teaching Award, 2010

### **Brett M. Elicker, MD**

Co-recipient, Hideyo Minagi Outstanding Teacher Award, 2010

### **Alisa D. Gean, MD**

Represented UCSF as a San Francisco Mayoral Delegate at the 30th anniversary of the San Francisco/Shanghai Sister City relationship and San Francisco Week events at the Shanghai World Expo in China

### **Christine M. Glastonbury, MBBS**

Named to Best Doctors in America for Radiology/Neuroradiology

First Prize for a Scientific Exhibit at the Combined Otolaryngology Spring Meeting, CT and MR

Second author and co-editor, *Expert DDx in the Head and Neck*. Harnsberger HR, Glastonbury CM, Michel MM, Koch B et al. Lippincott, Williams & Wilkins/Amirsys. April 2009

### **Grant T. Gullberg, PhD**

Recipient, 2010 Society of Nuclear Medicine Computer and Instrumentation Council's Ed Hoffman Memorial Award for outstanding scientific contributions to the field of SPECT imaging and nuclear medicine

### **Roland G. Henry, PhD**

Promoted to Professor in Residence

### **Michael D. Hope, MD**

First Prize, Young Investigator Award, North American Society for Cardiovascular Imaging, 37th Annual Meeting, October 2009



**John Kurhanewicz, PhD**

Recipient, Dean's Recognition for Excellence in Teaching, 2009, UCSF School of Pharmacy

Recipient, GE Healthcare's MR Thought Leader Award at the 17th Annual Scientific Meeting of the International Society for Magnetic Resonance in Medicine

**Thomas M. Link, MD, PhD**

Radiology Editor's Recognition Award 2010, with special distinction

Founder's Lecturer of the International Skeletal Society, Washington, DC, 2009: "Advances in Imaging of Osteoporosis and Osteoarthritis"

**Sharmila Majumdar, PhD**

Recipient, Patellofemoral Research Excellence Award, 7th Biennial International Society of Arthroscopy, Knee Surgery and Orthopaedic Sports Medicine Congress, Osaka, Japan

Author, *Advances in MRI of the Knee for Osteoarthritis*. 1st edition; World Scientific; (March 31, 2010)

**Alastair J. Martin, PhD**

Promoted to Adjunct Professor


**Susanne G. Mueller, MD**

Promoted to Associate Adjunct Professor

**Pratik Mukherjee, MD, PhD**

Appointed Chair of the Research Committee of the American Society of Neuroradiology

Appointed to the Executive Committee of the ASNR



Alisa Gean, MD, with San Francisco Mayor Gavin Newsom in Shanghai, China

Appointed a member of the Annual Meeting Program Committee of the International Society of Magnetic Resonance in Medicine

**Sarah J. Nelson, PhD**

Meet-the-Expert speaker on the topic "Magnetic Resonance Imaging of Solid Tumors," AACR 2010 Annual Meeting, Washington, DC

**Karen Ordovás, MD**

Recipient, 2010-11 American Roentgen Ray Scholar Award



Chairman Ron Arenson, MD, presents Hideyo Minagi Outstanding Teaching Award to Co-recipient Soonmee Cha, MD



Chairman Ron Arenson, MD, presents Hideyo Minagi Outstanding Teaching Award to Co-recipient Brett M. Elicker, MD



Lynne Steinbach, MD, (second from left) ISMRM fellow, Stockholm, Sweden

**Liina Poder, MD**

Promoted to Associate Professor of Clinical Radiology

**Ernest J. Ring, MD**

Recipient, Vascular and Interventional Society of Radiology's 2010 ATLAS (A Teacher, Leader, and Scholar) Award

**Edward A. Sickles, MD**

Recipient, 2010-2011 Ed Dickson Emeritus Professorship Award

**Rebecca Smith-Bindman, MD**

Visiting Research Scientist 2009-2010, Radiation Epidemiology Branch, National Cancer Institute, National Institutes of Health, Bethesda, Md.

Invited Expert, Congressional Hearing: Medical Radiation: An Overview of the Issues, US House of Representatives, Energy and Commerce Committee, Subcommittee on Health

Invited to present at the Food and Drug Administration's Center for Devices and Radiological Health: Collecting Radiology Dose Information: What Needs to Be Done

Nominated to the Imaging Efficiency Steering Committee, National Quality Forum

Nominated to the American Board of Medical Specialties/American Board of Radiology/American College of Radiology/Physician Consortium for Performance Review Patient Radiation Dose Work Group

**Lynne S. Steinbach, MD**

Author, *MRI of the Upper Extremity: Shoulder, Elbow, Wrist and Hand*, Lippincott Williams and Wilkins. 1st edition (October 28, 2009)

Fellowship, International Society of Magnetic Resonance in Medicine

Radiology Editor's Recognition Award 2010, with special distinction

Secretary, International Skeletal Society

Nominating Committee Chair, International Society of Magnetic Resonance in Medicine

**Lori M. Strachowski, MD**

Promoted to Clinical Professor

**Thomas H. Urbania, MD**

Co-recipient, Outstanding Fellow/Clinical Instructor Teaching Award, 2010

**Z. Jane Wang, MD**

2010-2012 RSNA Scholar Award

**W. Richard Webb, MD**

2009 William Manchester Lecturer, Dalhousie University, Halifax, Nova Scotia, Canada

**David M. Wilson, MD, PhD**

RSNA Resident/Fellow Research Grant, 2009

## Clinical Faculty Honored for Their Contributions

**Camilla Lindan, MD**, associate clinical professor in the Department of Radiology and Biomedical Imaging, was one of three UCSF volunteer faculty members who received Special Recognition Awards from the UCSF Association of Clinical Faculty (ACF) at its 2009 annual dinner.

A neuroradiologist with Kaiser Permanente in San Francisco, Lindan may be best known for the “Head CT Survival Guide” lecture she gives to first-year residents before they begin call. She also reads images with radiology residents at San Francisco General Hospital and teaches pediatric residents when they rotate through Kaiser. Lindan serves on the ACF Council and on the Margulis Society Board of Directors. She has collaborated with UCSF Neurology and Radiology faculty on several pediatric research projects. Of all her various activities at UCSF, she says she gets the greatest joy from teaching.

The ACF dinner recognizes the entire UCSF volunteer clinical faculty, who taught more than 116,000 hours in the 2009-2010 academic year. “I was especially pleased to be included in a group of honorees that included Erik Gaensler, who was promoted to clinical professor,” Lindan said. “Eric has devoted countless hours to teaching UCSF diagnostic radiology residents and neuroradiology fellows.” Lindan and **Erik H. L. Gaensler, MD**, both completed their Radiology residencies and Neuroradiology fellowships at UCSF and are previous recipients of the Outstanding Clinical Faculty Award.



UCSF Chancellor Susan Desmond-Hellmann, MD, MPH, (left) and UCSF School of Medicine Dean Sam Hawgood, MBBS, (right) joined Lindan at the ACF Awards Banquet in November 2009.



The ACF dinner: Mark W. Wilson, MD, (on the right) professor in residence and chief of radiology, SFGH, presented Lindan's award. They were seated with ACF members (l-r) Erik Gaensler, MD and Geoffrey Riley, MD.

## Hylton Named to Scientific Advisory Council



Nola Hylton, PhD

who have already made significant contributions to the field.” Council members receive \$250,000 in grant money each year of their two-year terms.

**Nola Hylton, PhD**, professor in residence and co-director of the Breast Cancer Research Interest Group, is among the first group of scholars named to the Susan G. Komen for the Cure's Scientific Advisory Council. The 46 council members are “established senior scholars and leaders in the field of breast cancer

As a council member, Hylton will participate in Komen's scientific peer review process for research grants and applications. Other duties include evaluating scientific evidence and clinical/public health realities in development of policy positions and chairing or participating in professional scientific conferences, think tank meetings, and state-of-the-science reviews.

“I am quite honored and excited at the prospect of working with an organization that has done so much to support breast cancer research,” Hylton said.

Susan G. Komen for the Cure® is the global leader of the breast cancer movement, having invested nearly \$1.5 billion since 1982.



## Retired in 2010


### **CHARLES B. HIGGINS, M.D.**

Charles B. Higgins, MD, professor of radiology, retired in January after over 27 years in the Department of Radiology and Biomedical Imaging. He retired at the rank of distinguished professor. He continues to contribute his clinical, research, and teaching skills to the department as a professor emeritus.

Higgins is a graduate of Jefferson Medical College in Philadelphia and underwent subspecialty residency, research, and fellowship training at the University of California, Los Angeles, University of California, San Diego, and Stanford Medical Centers.

Higgins has been actively involved in laboratory research involving cardiovascular physiology and pharmacology and cardiac imaging, especially magnetic resonance imaging, for over 25 years. He has conducted clinical and laboratory research on cardiovascular application of MRI since 1983 at the University of California Medical Center in San Francisco. Higgins was the director of a NIH-funded research-training grant in cardiac imaging for nearly 20 years. More than 100 research fellows have worked under his supervision at UCSF.

He was awarded the Distinguished Scientific Achievement Award of the American Heart Association in 1990, the Outstanding Researcher Award of the RSNA in 2000, and the Outstanding Alumnus of Jefferson Medical College in 2001. He is an honorary member of many international societies of radiology and cardiology including an honorary member of the European Society of Radiology. He has also delivered 36 titled lectureships in the United States and abroad. He is or has been a member of the editorial boards of 14 scientific journals and is currently a member of the editorial boards of *Circulation*, the *American Journal of Cardiology*, and the *Journal of American College of Cardiology*, the *Journal of Magnetic Resonance Imaging*, and the *Journal of Cardiovascular MR*.





## In Memoriam: T. Hans Newton, MD

T. Hans Newton, MD, a gifted educator, author, mentor, and a superb physician and neuroradiologist died on June 6 with his family by his side. Newton was among the select group of amazing physicians who came to UCSF in the 1960s and started the strong tradition of clinical neuroscience that today is recognized the world over. He was buried in Ashland, Oregon, where his daughter Judy and her husband, UCSF Radiology alumnus Gary Hansen, MD, live with their two daughters.

Thomas Hans Newton was born in 1925 in Berlin, Germany. His immediate family left Germany before World War II to start a new life in Portland, Oregon. Young Hans enrolled in grade school at age 11, speaking no English. His undergraduate years at the University of California, Berkeley were interrupted by military service in the Navy, but he graduated with a BA in 1949. He received his MD at UCSF in 1952. After a year's internship at the University of Wisconsin and a year as a UCSF medicine resident, Newton completed his residency in radiology at the Peter Bent Brigham Hospital under Merrill Sosman, MD. As was common at that time, Newton then spent 18 months as a fellow in Stockholm, Zurich, and London. In London, he trained in neuroradiology at the National Hospital for Nervous Diseases, Queens Square. He joined UCSF in 1959, where he remained on the faculty for 50 distinguished years.

Newton's academic accomplishments and awards are myriad. He founded the section of neuroradiology at UCSF, and had a hand in training more than 160 fellows over a span of 40 years. His multi-volume text *Radiology of the Skull and Brain*, otherwise known as "Newton and Potts," was the "red bible" of neuroradiology for decades. With the advent of CT and MR, he continued his contributions with *Modern Neuroradiology*, a four-volume text still considered a standard. He was one of 13 founding members and past-president of the American Society of Neuroradiology, which awarded him its first gold medal. He was an honorary member of the European Society of Neuroradiology, past-president of the Western Neuroradiologic Society, and served on the editorial boards of most of the leading journals in radiology.

Among his accomplishments were the introduction of the Seldinger technique for cerebrovascular angiogra-

phy in the United States, the first embolization of a spinal arteriovenous malformation, and the introduction of computed tomography and MR imaging at UCSF. He was a superb angiographer with meticulous

attention to detail and a quick eye. As his and UCSF's reputations spread, UCSF became a center for training academic radiologists from around the globe. His seminal publications include articles on the arteriography of cerebrovascular occlusive disease in the *New England Journal of Medicine* in 1962, descriptions of arteriovenous malformations and fistula of the posterior fossa in 1966 and 1968, and a classic article entitled "Involvement of the dural arteries in intracranial arteriovenous malformations" published with Sven Cronquist in 1969.

Newton's love of travel and exploring different cultures took him and his life-long companion and spouse, Pat Newton to the far reaches of the globe. They hiked the mountains of Nepal to reach Everest base camp, boated through the Amazon rainforest, and climbed Mt. Kenya. Through his mid-sixties, Newton could beat all the fellows in the two-mile race around the base of Mt. Tamalpais before one of the frequent barbeques at the Newton home in Kentfield. He was most proud of his daughters, Judy, an attorney and Diane, a neuroradiologist, as well as his five grandchildren.



### The Newton Lecture: A Living Legacy

"Dr. Hans Newton leaves a lasting legacy in the science and practice of neuroradiology, here at UCSF and throughout the world," said William P. Dillon, MD. "His many friends and colleagues will miss him, but take comfort in knowing that his contributions endure through the many trainees that he inspired and the patients he helped throughout his career."

His legacy also endures through the annual T. Hans Newton Honorary Lecture at UCSF. Each October, a leading expert speaks on an aspect of neuroradiology. The 2010 lecture and memorial service were held on October 13.

## Diagnostic Radiology Residency Program 2010

It was a special year, orchestrated by an incredibly competent and perceptive triumvirate of chief residents: Reema Munir, MD, Peter Jun, MD, and Dave Naeger, MD. They were always one step ahead, anticipating and neutralizing problems before they happened. They also improved the residency program with new ideas, the most significant of which was the implementation of the Resident Clinical Educator Track. Jun spearheaded the implementation of the resident-run Brant and Helms Club and programmed the web-based conference evaluation by residents, in addition to an interactive calendar for call and rotation scheduling.

External recognition of leadership and scholarly activity included the selection of Sharon Kwan, MD, as an ACR Research Fellow, Naeger completing his term as the president of the American Alliance of Academic Chief Residents, and the service of Vinil Shah, MD, as the president of the Resident and Fellow Section of the California Radiological Society.

Kwan received the RSNA Research and Education Foundation award and the Margulis Society Outstanding Resident Research award. Her published research included topics on image-guided biopsies and the utilization of interventional oncology treatments in the United States. She is staying on at UCSF as a Body Interventional fellow, planning an academic career.

Naeger received the UCSF Elmer Ng outstanding resident award.

Four of our residents, Kwan, Gloria Chiang, MD, Naeger, and Tim Shepherd, MD, PhD, participated in the full-year research option through the T32 grant, and all were highly productive. Chiang works in neuroimaging MR cognitive studies, including Alzheimers, and Shepherd works in high-field, high-resolution MR. Three received departmental seed grants as well, evidence of the department's commitment to resident research.

Shilpa Kumbhani, MD, and Lauren Raher, MD, received certificates of merit for their joint RSNA educational exhibit.

All in all, our residents received a total of 95 months of research time (up to a maximum of 12 months total per four-year residency). They presented or published numerous projects, and traveled far and wide, including several resident presentations at the ISMRM in Stockholm. Some



Diagnostic Radiology residents enjoy RSNA 2009

of the resident authors not mentioned above are Jose Diaz-Hernandez, MD, Peter Jun, MD, Maureen Kohi, MD, Judong Pan, MD, PhD, Andrew Phelps, MD, Rainer Poley, MD, Fabio Settecasse, MD, and Vinil Shah, MD, Alexander Keedy, MD, and Shilpa Kumbhani, MD.

While we are preparing for the transition in the ABR Board Examination procedure over the next few years, we note that all of this year's graduating class passed their oral exams. We are delighted that the vast majority have chosen to stay at UCSF for fellowship training and career development, with a couple going elsewhere for personal reasons.

Our residents have diverse outside interests and community activities, ranging from civic opera participation (Divya Sridhar, MD) to enhancing education for girls and young women in Pakistan (Nayela Keen, MD).

One highlight not to be overlooked is the notification of five-year accreditation of our residency program by the RRC and ACGME.

A strong group finished a close second at the AUR film panel competition. We will be back!

The academic year follows a certain rhythm: advancement of our graduates to fellows, arrival of the new residents, and then all too soon, the fall and the application process. Fall turns into winter with the rush of RSNA. This year, we had 12 trainees presenting and attending RSNA, most for the first time, with a lot of excitement and energy. The winter is all about interviewing and assessing the applicants. In the late winter and spring, we see the maturation of our residents of all years, watching them become excellent radiologists, and we see the seniors studying for the oral boards.

We have already seen the promise of our new chief residents: Settecasse, Shah, and Phelps. And we have greeted our new and impressive resident class.

The plans for this year include expanding our core curriculum, facilitating the participation of senior residents in mini-fellowships, and an end-of-year and end-of-rotation web-based clinical case assessment for our residents. We look forward to our annual welcome event hosted by our program director, the annual UCSF RSNA gathering, and the Margulis Society Gala fundraiser celebrating 20 years of alumni support for UCSF Diagnostic Radiology Resident education and research.

### **Presentations and Posters**

**Gloria Chiang, MD:** Abstract presentation, American Society of Neuroradiology (ASNR) annual meeting 2009, Chiang GC, Tosun D, Mueller S, Zhang Y, Ching C, Schuff N, Weiner MW. "ASL-MRI Detects Perfusion Differences in Cognitively Normal ApoE2 and ApoE4 Carriers: A Possible Explanation for Alzheimer Protection versus Risk"; Research presentation, UCSF, 2010, "Multimodal Imaging Correlates of the Alzheimer's-protective ApoE2 Genetic Polymorphism"

**Jose Diaz-Hernandez, MD:** RSNA education exhibit 2009, "Optimizing the Clinical Usefulness of CT Colonography (CTC): Becoming Familiar with Common Pitfalls and Learning Strategies to Resolve Them"

**Thomas A. Hope, MD:** Presentation, International Society for Magnetic Resonance in Medicine Annual Meeting, Stockholm, Sweden, May 2010: Hope TA, Hope MD, Miller DC, Markl M, Kvitting JE, Higgins CB, Herfkens RJ. "Long Term Follow-Up of Patients Status Post Valve-Sparing Aortic Surgery with 4D-Flow." RSNA, November 2009: Hope TA, Chaopathomkul B, LeBoit PE, High WA, Rogut VS, Herfkens RJ, Brasch RC. "Nephrogenic Systemic Fibrosis in Rats treated with Erythropoietin and Intravenous Iron"

**Peter Jun, MD:** RSNA education exhibit 2009, "The Big Squeeze: Radiologic Diagnosis and Endovascular Treatment of Cerebral Vasospasm Following Aneurysmal Subarachnoid Hemorrhage"

**Maureen P. Kohi, MD:** RSNA education exhibit 2009, "Imaging Manifestations of Cardiopulmonary Complications Following Lung Transplantation"

**Sharon W. Kwan, MD:** RSNA education exhibit 2009, "Evaluation of the Portal Venous System with Transarterial CT Portography: Indications, Technique, and Examples" and



Chief Residents 2010–11: Fabio Settecasse, MD, Vinil Shah, MD, Andrew Phelps, MD

"Hemodialysis Catheters: Are You Just Going with the Flow? Make an Informed Choice!"; Research presentation, UCSF, 2010, "National Trends and Utilization Patterns of Biopsy and Interventional Oncology Services"

**David M. Naeger, MD:** National Institute of Biomedical Imaging and Bioengineering T32 Training Grantees Meeting 2010, Naeger DM, Higgins CB, De Marco T, Muzzarelli S, Ordovas KG, "Border Zone Delayed Contrast Enhancement in Hypertrophic Cardiomyopathy: Comparison to Occlusive Myocardial Infarctions"; RSNA education exhibit 2009, Naeger DM, Elicker BM, Ordovas KG, Higgins CB. "Coronary CTA (CCTA) in the Evaluation of Coronary Artery Bypass Grafts (CABG)"; Research presentation, UCSF, 2010, "Cardiac MR Spectroscopy, Hypertrophic Cardiomyopathy, and More"

**Judong Pan, MD, PhD:** Presentation, International Society for Magnetic Resonance in Medicine Annual Meeting, Stockholm, Sweden, May 2010, Pan J, Stehling C, Muller-Hocker C, Schwaiger BJ, Lynch J, and Link TM. "Vastus lateralis/vastus Medialis Ratio Impacts Presence and Degree of Knee Joint Abnormalities and Cartilage T2 Determined with 3T MRI: An Analysis from the Incidence Cohort of the Osteoarthritis Initiative"

**Andrew Phelps, MD:** Poster presentation, Association of University Radiologists Annual Meeting, San Diego, March 2010, "Anatomy Education: Cost Comparison of Computers and Cadavers"

**Rainer N. Poley, MD:** RSNA education exhibit 2009, "Accidental Pediatric Head Trauma: Spectrum of Disease and Imaging Findings"

**Lauren B. Raher, MD:** RSNA education exhibit 2009, "DISI or VISI? An Easy Approach to Pathology of the Scapholunate and Lunotriquetral Ligament Complexes"

**Fabio Settecasse, MD:** Presentation, American Society of Neuroradiology, 48th Annual Meeting, Boston, Mass, May,



2010. F Settecase, W Lin, M Wintermark. "Vertebrobasilar Calcification on CT and its Association with Acute Posterior Circulation Infarction"; Presentation, International Society for Magnetic Resonance in Medicine 18th Scientific Meeting, Stockholm, Sweden, May, 2010, F Settecase, A Bernhardt, L Evans, V Malba, M Wilson, AJ Martin, RL Arenson, S Hetts. "Cooling of Resistive and RF Heating of Steerable Catheter Microwires for Interventional MRI"

**Vinil Shah, MD:** RSNA education exhibit 2009, "Imaging Characteristics of Diffuse Liver Disease: Using an Algorithmic Problem-solving Approach to Arrive at a Concise Differential Diagnosis"

**Timothy M. Shepherd, MD, PhD:** Presentation, International Society for Magnetic Resonance in Medicine Annual Meeting, Stockholm, Sweden, May 2010, Coauthor, "Reduced field-of-view diffusion imaging of the brain at 7-T"; Invited presenter, National Institute of Health/National Institute of Child Health and Human Development on "Developing Magnetic Resonance Microscopy for Human Nervous Tissue" (Peter Basser, PhD Laboratory, NIH); Abstract presentation, American Society of Neuroradiology annual meeting 2009, "Targeted high-resolution diffusion MRI of the medial temporal lobes at 3-T"; UCSF research presentation, 2010, "MRI Characterization of the Functional Organization of the Medial Temporal Lobes"

## Publications

**Thomas A. Hope, MD:** Hope TA, High WA, LeBoit PE, Chaopathomkul B, Rogut VS, Herfkens RJ, Brasch RC. "Nephrogenic Systemic Fibrosis in Rats treated with Erythropoietin and Intravenous Iron." *Radiology*. 2009 Nov;253(2):390-8; Hope TA, Hope MD, Purcell DD, von Morze C, Vigneron DB, Alley MT, Dillon WP. "Evaluation of intracranial stenoses and aneurysms with accelerated 4D flow." *Magn Reson Imaging*. 2010 Jan;28(1):41-6

**Alexander W. Keedy, MD:** RSNA scientific paper 2009, "The Value of Three-dimensional Modeling and Interactivity in Teaching Anatomy to Medical Students: A Comparison with a Traditional Two-dimensional Atlas-type Approach"

**Maureen P. Kohi, MD:** RSNA scientific paper 2009, "Can Two Wrongs Make a Right? MR Assessment of Combined Pulmonary Stenosis and Insufficiency in Tetralogy of Fallot"

**Shilpa R. Kumbhani, MD:** RSNA scientific paper 2009, "Endorectal T2-weighted MR Imaging for the Detection of Recurrent Prostate Cancer after External Beam Radiation Therapy: Accuracy of Different Interpretative Approaches"

**Sharon W. Kwan, MD:** Kwan SW, Bhargavan M, Kerlan RK, Sunshine JS. "Advanced Imaging Technology's Impact on How Biopsies are Done and Who Does Them." *Radiology*. Accepted pending revision, 2010; Kwan SW, Kerlan RK, Sunshine JS. "Utilization of Interventional Oncology Treatments in the United States." *J Vasc Interv Radiol*. 2010 May 15. (Epub ahead of print)

**Michael Lu, MD:** Hunsaker AR, Lu MT, Goldhaber SZ, and Rybicki FJ. Imaging in Acute Pulmonary Embolism With Special Clinical Scenarios. *Circulation Cardiovasc Imaging* 2010; 3: 491-500

**David M. Naeger, MD:** Naeger DM, Martin JN, Sinclair E, Hunt PW, Bangsberg DR, Hecht F, Hsue P, McCune JM, Deeks SG. "Cytomegalovirus-specific T Cells Persist at Very High Levels During Long-term Antiretroviral Treatment of HIV Disease." *PLoS ONE* 5(1): e8886. doi:10.1371/journal.pone.0008886; Naeger DM, Chang S, Kolli P, Shah V, Huang W, Thoeni RF. "Neutral vs. positive oral contrast: sensitivity, specificity, interpretation time and confidence in diagnosing acute appendicitis with contrast-enhanced CT (CECT)." *The British Journal of Radiology*, accepted. Pending publication; Joseph T, Naeger DM, Qayyum A. "The Obesity Epidemic: The Role of Radiology" *Applied Radiology*, accepted in present form.

**Rainer N. Poley, MD:** "Accidental Pediatric Head Trauma: Spectrum of Disease and Imaging Findings." Education exhibit RSNA 2009, Selected for publication in *Radiographics*.

**Timothy M. Shepherd, MD, PhD:** First author, 2011 Functional Neuroradiology book chapter "Epilepsy: Clinical Applications of DTI"

**Katherine To'o, MD:** RSNA scientific paper 2009, "Computed Tomography Evaluation of Imaging Features That Predict Variceal Hemorrhage"

## Grants

**Gloria Chiang, MD:** UCSF Department of Radiology and Biomedical Imaging seed grant

**Thomas A. Hope, MD:** RSNA resident research grant

**Sharon W. Kwan, MD:** UCSF Department of Radiology and Biomedical Imaging seed grant

**David M. Naeger, MD:** UCSF Department of Radiology and Biomedical Imaging seed grant

**Timothy M. Shepherd, MD, PhD:** UCSF Department of Radiology and Biomedical Imaging seed grants 2009-2010; 2010-2011



## The Nuclear Medicine Training Program


In July 2010, the UCSF Department of Radiology and Biomedical Imaging graduated its first residents in the new three-year residency curriculum: David M. Carlson, MD, and Nhan T. Nguyen, MD. This new curriculum complies with the ACGME requirements for graduate medical education in nuclear medicine. Perhaps the most significant change is the additional year of residency to incorporate computed tomography training for PET/CT. Nuclear medicine residents now rotate on a diagnostic radiology service and interpret CTs.

Carlson and Nguyen completed 26 months on the Nuclear Medicine service, rotating through Moffitt and China Basin and 10 months on Moffitt CT (5 months Abdominal Imaging and 5 months Chest). They gained experience in all diagnostic and therapeutic applications of nuclear medicine. “The amount of CT experience they received is unprecedented for nuclear medicine residents and has prepared them well for PET/CT interpretation,” said Miguel Hernandez Pampaloni, MD, PhD, chief of Nuclear Medicine. “We aim to ensure that residents are comfortable interpreting non-contrast and contrast-enhanced diagnostic CTs in addition to the FDG-PET component.”

Both also trained outside of UCSF in coronary CTA, completing a CME course that included 50 live cases and the systematic interpretation of 150 mentored case studies. This course enabled them to fulfill the Level 2 certification requirements of the ACC/AHA and the ACR Practice Guideline for the Performance and Interpretation of Cardiac CT.

UCSF’s nuclear residents meet the qualifications outlined in the ACR Practice Guidelines for:

- Performing and Interpreting Diagnostic CT
- Use of Intravascular Contrast Media, Performance and Interpretation of CTA
- Thoracic CT
- CT for the Detection of Pulmonary Embolism in Adults
- CT of the Abdomen
- CT of the Pelvis



Cha and Naeger, 2010–2011 Nuclear Medicine Fellows

During their training, Nguyen and Carlson attended graduate bioengineering courses taught by UCSF Radiology faculty, which included courses on the physics of X-ray, CT, MR, nuclear medicine, optical, and molecular imaging. They recently attended the Society of Nuclear Medicine annual meeting in Salt Lake City. Highlights included sessions on new antibody treatments for lymphoma, advances in nuclear cardiology, and the correlation of nuclear brain imaging with MRI, especially as it applies to patients with Alzheimer’s disease or those with refractory seizures.

Carlson is now completing a one-year CT fellowship at UCSF, pursuing his interest in oncologic PET/CT. In November he will present an education exhibit at RSNA entitled “DLP and Me—Understanding the Radiation Exposure Information Provided by Your CT Scanner.” Nguyen is working at Kaiser Permanente in Vallejo and in a clinical research capacity with Carina Mari, MD at the San Francisco Veterans Affairs Medical Center.

For the 2010–2011 academic year, the Nuclear Residency program welcomed two one-year fellows: Susan Cha, MD, who completed her radiology residency at Thomas Jefferson University and David Naeger, MD, who completed his radiology residency at UCSF.

## First-Year Diagnostic Radiology Residents 2010



### **Ramon F. Barajas, Jr., MD**

**MD 2009** University of California  
San Francisco, School of Medicine,  
San Francisco

**2009-2010** Internal Medicine  
Internship, Kaiser Permanente,  
San Francisco, Calif.

**2009** Alpha Omega Alpha

#### **Research:**

**2009-2010** Department of Radiology  
and Biomedical Imaging, UCSF

**2007-2008** Biomedical Research  
Program, UCSF

**2007-2008** Doris Duke/Pathways  
to Careers in Clinical and  
Translational Research Fellow,  
UCSF

**2005-2006** Dean's Summer Research  
Associate, UCSF

#### **Selected Publications:**

Barajas RF Jr, Hodgson JG, Chang  
JS, Vandenberg SR, Yeh RF, Parsa AT,  
McDermott MW, Berger MS, Dillon  
WP, Cha S. Glioblastoma multiforme


regional genetic and cellular expres-  
sion patterns: influence on anatomic  
and physiologic MR imaging. *Radiol-  
ogy*. 2010 Feb;254(2):564-76.

Barajas RF Jr, Chang JS, Segal MR,  
Parsa AT, McDermott MW, Berger  
MS, Cha S. Differentiation of recur-  
rent glioblastoma multiforme from  
radiation necrosis after external  
beam radiation therapy with dynamic  
susceptibility-weighted contrast-  
enhanced perfusion MR imaging.  
*Radiology*. 2009 Nov;253(2):486-96.

Barajas RF, Collins DE, Cha S,  
Geschwind MD. Adult-onset drug-  
refractory seizure disorder associated  
with anti-voltage-gated potassium-  
channel antibody. *Epilepsia*. 2010  
Mar;51(3):473-7.

Barajas RF Jr, Rubenstein JL, Chang  
JS, Hwang J, Cha S. Diffusion-  
weighted MR imaging derived  
apparent diffusion coefficient is  
predictive of clinical outcome in  
primary central nervous system  
lymphoma. *AJNR Am J Neuroradiol*.  
2010 Jan;31(1):60-6.

Barajas RF Jr, Sughrue ME, McDer-  
mott MW. Large falcine meningioma  
fed by callosomarginal branch suc-  
cessfully removed following contra-  
lateral interhemispheric approach.  
*J Neurooncol*. 2010 Mar;97(1):127-31.



### **Amaya M. Basta, MD**

**MD 2009** University of Washington,  
School of Medicine, Seattle

**2009-2010** Internal Medicine  
Internship, Boise Veterans Affairs  
Medical Center, Boise, Ida.

**2007** Alpha Omega Alpha

#### **Research:**

**2007-2008** Department of  
Emergency Medicine, University of  
Washington, and the Seattle Police  
Department, Seattle

**2004-2005** Harborview Injury  
Prevention and Research Center,  
Harborview Medical Center,  
Seattle, Wash.

#### **Publications:**

Basta AM, Blackmore CC, Wessells  
H. Predicting urethral injury from  
pelvic fracture patterns in male  
patients with blunt trauma. *J Urol*.  
2007 Feb;177(2):571-5.



### **Nancy J. Benedetti, MD**

**MD 2009** Stanford University, School of Medicine, Stanford, Calif.

**2009-2010** Preliminary Medicine Internship, Kaiser Permanente, Santa Clara, Calif.

#### **Research:**

**2008-2009** Department of Radiology and Biomedical Imaging, UCSF

**2006-2007** Division of Research, Kaiser Permanente, Oakland, Calif.

**2005** Novartis Institutes for Biomedical Research, Cambridge, Mass.

#### **Publications:**

Reed M, Benedetti N, Brand R, Newhouse JP, Hsu J. Perspectives from deductible plan enrollees: plan knowledge and anticipated care-seeking changes. *BMC Health Serv Res.* 2009 Dec 29;9:244

Benedetti N, Aslam R, Wang ZJ, Joe BN, Fu Y, Yee J, Yeh BM. Delayed enhancement of ascites after i.v. contrast material administration at CT: time course and clinical correlation. *AJR Am J Roentgenol.* 2009 Sep;193(3):732-7.

Reed M, Fung V, Price M, Brand R, Benedetti N, Derosé SF, Newhouse JP, Hsu J. High-deductible health insurance plans: efforts to sharpen a blunt instrument. *Health Aff (Millwood).* 2009 Jul-Aug;28(4):1145-54.

Benedetti NJ, Desser TS, Jeffrey RB. Imaging of hepatic infections. *Ultrasound Q.* 2008 Dec;24(4):267-78.

Ballard DW, Reed ME, Wang H, Arroyo L, Benedetti N, Hsu J. Influence of patient costs and requests on emergency physician decision-making. *Ann Emerg Med.* 2008 Dec;52(6):643-650.



### **Stephanie Chan, MD**

**MD 2009** Stanford University, Stanford, Calif.

**2009-2010** Internal Medicine Internship, Kaiser Permanente, Santa Clara, Calif.

#### **Research:**

**2008-2010** Departments of Radiology and Medical Informatics, Stanford University, Stanford, Calif.

**2003-2005** Department of Psychiatry, Stanford University, Stanford, Calif.

#### **Publications:**

Chan S, Murphy GM Jr. A computational method for using the public human EST database for SNP detection in the H1 Histamine Receptor Gene. *Stanford Biologist* 2005; 7:39-44



### **Akash Kansagra, MD**

**MD 2009** University of California, San Diego

**2009-2010** Surgery Internship, University of California, San Diego

**MS 2005** Physics, University of California, Irvine

#### **Research:**

**2006-2009** Department of Radiology, University of California, San Diego

**2003-2004** Department of Physics, Massachusetts Institute of Technology, Cambridge, Mass.


#### **Publications:**

Kansagra AP, Menon JP, Yarbrough CK, Urbaniak K, Waters JD, Borys E, Jandial R. Balamuthia mandrillaris meningoencephalitis in an immunocompromised patient. Case report. *J Neurosurg.* 2009 Aug;111(2):301-5.



Kansagra AP, Wong EC. Mapping of vertebral artery perfusion territories using arterial spin labeling MRI. *J Magn Reson Imaging*. 2008 Sep;28(3):762-6.

Kansagra AP, Wong EC. Quantitative assessment of mixed cerebral vascular territory supply with vessel encoded arterial spin labeling MRI. *Stroke*. 2008 Nov;39(11):2980-5.



### Yuo-Chen Kuo, MD

**MD 2009** University of Pennsylvania, Philadelphia,

**2009-2010** Transitional Internship, Maimonides Medical Center, Brooklyn, NY

**2009** Alpha Omega Alpha

#### Research:

**2003-2005** Department of Pharmacology, University of Pennsylvania, Philadelphia

**2006-2009** Department of Radiology, University of Pennsylvania, Philadelphia

#### Publications:

Kuo YC, Mondschein JI, Soulen MC, Patel AA, Nemeth A, Stavropoulos SW, Kelly PD, Itkin M, Solomon JA, Shlansky-Goldberg RD, Trerotola SO. Drainage of collections associated with hernia mesh: is it worthwhile? *J Vasc Interv Radiol*. 2010 Mar;21(3):362-6.

Kuo YC, Levine MS. Erosion of Anterior Cervical Plate into Pharynx with Pharyngotracheal Fistula. *Dysphagia*. 2010 Jan 21. (Epub)

Kuo YC, Shlansky-Goldberg RD, Mondschein JI, Stavropoulos SW, Patel AA, Solomon JA, Soulen MC, Kwak A, Itkin M, Chittams JL, Trerotola SO. Large or small bore, push or pull: a comparison of three classes of percutaneous fluoroscopic gastrostomy catheters. *J Vasc Interv Radiol*. 2008 Apr;19(4):557-63.



### Parham Moftakhar, MD

**MD 2008** David Geffen School of Medicine, University of California, Los Angeles

**2009-2010** Neurosurgery Resident, Cedars-Sinai Medical Center, Los Angeles, Calif.

**2008-2009** General Surgery

Internship, Cedars-Sinai Medical Center, Los Angeles, Calif.

#### Research:

**2006-2007** Cerebral Blood Flow Laboratory, University of California, Los Angeles

#### Publications:

Moftakhar P, Hauptman JS, Malkasian D, Martin NA. Cerebral arteriovenous malformations. Part 1: cellular and molecular biology. *Neurosurg Focus*. 2009 May;26(5):E10

Moftakhar P, Hauptman JS, Malkasian D, Martin NA. Cerebral arteriovenous malformations. Part 2: physiology. *Neurosurg Focus*. 2009 May;26(5):E11.

Grewal NS, Moftakhar P, Frykman PK. Fibromatosis presenting as a sacrococcygeal mass. *J Pediatr Surg*. 2009 Mar;44(3):637-9.

Lee DJ, Moftakhar P, Glenn TC, Vespa PM, Martin NA. Intra-arterial calcium channel blocker infusion for treatment of severe vasospasm in traumatic brain injury: case report.

*Neurosurgery*. 2008 Nov;63(5):E1004-6; discussion E1006.

Moftakhar P, Fan X, Hurvitz CH, Black KL, Danielpour M. Long-term survival in a child with a central nervous system medulloblastoma. *J Neurosurg Pediatr*. 2008 Nov;2(5):339-45.





### **Olufoladare Olorunsola, MD**

**MD 2009** Columbia University, New York, NY

**2009–2010** Internal Medicine Internship, Cedars-Sinai Medical Center, Los Angeles, Calif.

**2009** Alpha Omega Alpha

#### **Research:**

**2006** Dean's Grant Research Fellow, Columbia University, New York, NY



### **Anand S. Patel, MD**

**MD 2009** Harvard University, Boston, Mass.

**2009–2010** Medicine Internship, Beth Israel Deaconess Medical

Center, Harvard University, Boston, Mass.

#### **Research:**

**2005–2010** Division of Health Sciences and Technology, Harvard-MIT; Department of Radiology, Beth Israel Deaconess Medical Center, Boston, Mass.

**2002–2005** University of Pennsylvania, School of Medicine, Philadelphia

#### **Publications:**

Patel AS, Reigada D, Mitchell CH, Bates SR, Margulies SS, Koval M. Paracrine stimulation of surfactant secretion by extracellular ATP in response to mechanical deformation. *Am J Physiol Lung Cell Mol Physiol*. 2005 Sep;289(3):L489-96.

Daugherty BL, Mateescu M, Patel AS, Wade K, Kimura S, Gonzales LW, Guttentag S, Ballard PL, Koval M. Developmental regulation of claudin localization by fetal alveolar epithelial cells. *Am J Physiol Lung Cell Mol Physiol*. 2004 Dec;287(6):L1266-73.

#### **Patents:**

Patel AS, Duan Q, Robson PM, McKenzie CME, Sodickson DK. A Simple Noniterative Principal Component Technique for Rapid Noise Reduction in Parallel MR Images. U.S. Patent Application No. 12/152,940 filed on May 19, 2008.



### **Robin O. Price, MD**

**MD 2009** Stanford University, Stanford, Calif.

**PhD 2009** Stanford University, Stanford, Calif.

#### **Research:**


**2008** Department of Radiology, Stanford University, Stanford, Calif.

#### **Publications:**

Price RO, Jeffrey RB, Vasanawala SS. Appendiceal hyperemia and/or distention is not always appendicitis: appendicitis mimicry in the pediatric population. *Clin Imaging*. 2009 Sep-Oct;33(5):402-5.

Cetas JS, Price RO, Crowe J, Velenovsky DS, McMullen NT. Dendritic orientation and laminar architecture in the rabbit auditory thalamus. *J Comp Neurol*. 2003 Apr 7;458(3):307-17.

Velenovsky DS, Cetas JS, Price RO, Sinex DG, McMullen NT. Functional subregions in primary auditory cortex defined by thalamocortical terminal arbors: an electrophysiological and anterograde labeling study. *J Neurosci*. 2003 Jan 1;23(1):308-16.



**Ricky T. Tong, MD, PhD**

**MD 2009** Stanford University, Stanford Calif.

**2009–2010** Preliminary Medicine Internship, California Pacific Medical Center, San Francisco, Calif.

**PhD 2005** Massachusetts Institute of Technology, Cambridge, Mass.

**Research:**

**2006–2009** Molecular Imaging Program, Stanford University, Stanford, Calif.

**2006–2010** Department of Radiology, Stanford University, Stanford, Calif.

**2008** Department of Radiation Oncology, Stanford University, Stanford Calif.

**2001–2005** Department of Radiation Oncology at Massachusetts General Hospital, Harvard Medical School, Boston, Mass.

**Publications:**


Kuo WT, Tong RT, Hwang GL, Louie JD, Lebowitz EA, Sze DY, Hofmann LV. High-risk retrieval of adherent and chronically implanted IVC filters: techniques for removal and management of thrombotic complications. *J Vasc Interv Radiol.* 2009 Dec;20(12):1548-56.

Huang X, Ding L, Bennewith KL, Tong RT, Welford SM, Ang KK, Story M, Le QT, Giaccia AJ. Hypoxia-inducible mir-210 regulates normoxic gene expression involved in tumor initiation. *Mol Cell.* 2009 Sep 24;35(6):856-67.

Sutton EJ, Tong RT, Gillis AM, Henning TD, Weinberg VA, Boddington S, Haas-Kogan DA, Matthay K, Sha V, Gooding C, Coakley FV, Daldrop-Link H. Decreased aortic growth and middle aortic syndrome in patients with neuroblastoma after radiation therapy. *Pediatr Radiol.* 2009 Nov;39(11):1194-202.

Jain RK, Tong RT, Munn LL. Effect of vascular normalization by anti-angiogenic therapy on interstitial hypertension, peritumor edema, and lymphatic metastasis: insights from a mathematical model. *Cancer Res.* 2007 Mar 15;67(6):2729-35.

Xu L, Cochran DM, Tong RT, Winkler F, Kashiwagi S, Jain RK, Fukumura D. Placenta growth factor overexpression inhibits tumor growth, angiogenesis, and metastasis by depleting vascular endothelial growth factor homodimers in orthotopic mouse models. *Cancer Res.* 2006 Apr 15;66(8):3971-7.



**David N. Tran, MD**

**MD 2009** Stanford University, Stanford, Calif.

**2009–2010** Surgery Internship, Stanford University, Stanford, Calif.

**Research:**

**2008** Abdominal Imaging, Department of Radiology and Biomedical Imaging, UCSF

**2006–2010** Biodesign Program, Stanford University, Stanford, Calif.

**2005–2010** Department of Radiology, Stanford University, Stanford, Calif.

**Patents:**

60/782,837, Patent pending (filed March 19, 2007). Energy generating systems for implanted medical devices. Inventors: David N. Tran, Afraaz Irani, Melani Wyld, Peter Young, Mark Bianco, Tony Li.

**Publications:**

Roos JE, Rakshe T, Tran DN, Rosenberg J, Straka M, El-Helw T, Sofilos MC, Napel S, Fleischmann D. Lower extremity CT angiography (CTA): initial evaluation of a knowledge-based centerline estimation algorithm for femoro-popliteal artery (FPA) occlusions. *Acad Radiol*. 2009 Jun;16(6):646-53.

Tran DN, Straka M, Roos JE, Napel S, Fleischmann D. Dual-energy CT discrimination of iodine and calcium: experimental results and implications for lower extremity CT angiography. *Acad Radiol*. 2009 Feb;16(2):160-71.

Tran DN, Fleischmann D, Rakshe T, Roos JE, Rosenberg J, Straka M, Napel S. Femoropopliteal artery centerline interpolation using contralateral shape. *Med Phys*. 2007 Sep;34(9):3428-35.

**John-Paul J. Yu, MD, PhD**

**MD 2009** University of Illinois, Urbana-Champaign, Ill.

**2009-2010** Internal Medicine Internship, St. Mary's Medical Center, San Francisco, Calif.

**PhD 2006** University of Illinois, Urbana-Champaign, Ill.

**2008** Alpha Omega Alpha

**Research:**

**2008** The Johns Hopkins School of Medicine, Baltimore, Md.

**Publications:**

Kemp M, Bae B, Yu JP, Ghosh M, Leffak M, Nair SK. Structure and function of the c-myc DNA-unwinding element-binding protein DUE-B. *J Biol Chem*. 2007 Apr 6;282(14):10441-8.

Li B(\*), Yu JP(\*), Brunzelle JS, Moll GN, van der Donk WA, Nair SK. Structure and mechanism of the lantibiotic cyclase involved in nisin biosynthesis. *Science*. 2006 Mar 10;311(5766):1464-7. (\*) equal contribution.

## Second-, Third-, and Fourth-Year Diagnostic Radiology Residents 2010–2011

### **Second-Year Residents**

Marjan Bolouri, MD  
Matthew Bucknor, MD  
Abby Deans, MD, PhD  
D. Thor Johnson, MD, PhD  
Lauren Hollowell, MD  
Alexander Keedy, MD  
Kevin Koo, MD  
John Mongan, MD, PhD  
Victor Sai, MD  
Ronnie Sebro, MD  
Leo Sugrue, MD, PhD  
S. Jarrett Wrenn, MD, PhD  
Etay Ziv, MD, PhD

### **Third-Year Residents**

Vishal Agarwal, MD  
Ingrid Burger, MD, PhD  
Renu Chundru, MD  
Thomas Hope, MD  
Nazia F. Jafri, MD  
Marc A. Laberge, MD  
Michael T. Lu, MD  
Ginger Merry, MD, MPH  
Michael A. Ohliger, MD, PhD  
J. Gabe Schneider, MD  
Ania J. Szary, MD  
Jason F. Talbott, MD, PhD  
Kiarash Vahidi, MD

### **Fourth-Year Residents**

Gloria Chia-Yi Chiang, MD  
Jose Juan Diaz-Hernandez, MD  
Adam Farkas, MD  
Jeffrey J. Hom, MD  
K. Pallav Kolli, MD  
Moirra A. O’Riordan, MD  
Judong Pan, MD, PhD  
Maria Parayno, MD  
Andrew Phelps, MD, Chief  
Fabio Settecasse, MD, Chief  
Vinil N. Shah, MD, Chief  
Timothy M. Shepherd, MD, PhD  
Divya Sridhar, MD  
Andrew G. Taylor, MD, PhD  
Max C. Wu, MD, PhD



## Clinical Fellows/Instructors 2010–2011

Abraham Ahmed, MD  
*Abdominal Imaging*

Spencer Behr, MD  
*Abdominal Imaging*

Natasha Brasic, MD  
*Interventional Radiology*

Karen Brown, MD  
*Musculoskeletal Imaging*

David M. Carlson, MD  
*Computed Tomography*

Jay Catena, MD  
*Neuroradiology*

Susan H. Cha, MD  
*Nuclear Medicine*

Benjamin A. Cohen, MD  
*Neuroradiology*

Daniel L. Cooke, MD  
*Neurointerventional*

Hamed Farid, MD  
*Neurointerventional*

Garney Fendley, MD  
*Cross Sectional Imaging (VAMC)*

Angelo Grasparil, MD  
*Pediatrics*

Taylor Jordan, MD  
*Abdominal Imaging*

Peter Jun, MD  
*Neuroradiology*

Amy W. Kao, MD  
*Musculoskeletal*

Nayela Keen, MD  
*Neuroradiology*

Trisha M. Kim, MD  
*Breast Imaging/Ultrasound*

Warren Kim, MD  
*Neurointerventional*

Maureen P. Kohi, MD  
*Interventional Radiology*

Stephen Kralik, MD  
*Neuroradiology*

Shilpa R. Kumbhani, MD  
*Abdominal Imaging/Breast Imaging*

Sharon W. Kwan, MD  
*Interventional Radiology*

Paulette Lebda, MD  
*Ultrasound/Breast Imaging*

Marianne Moon, MD  
*Breast Imaging/Ultrasound*

Heather G. Moreno, MD  
*Breast Imaging/Abdominal Imaging*

Reema Munir, MD  
*Breast Imaging/Abdominal Imaging*

David M. Naeger, MD  
*Pulmonary and Cardiac Imaging/  
Nuclear Medicine*

Ramin Naeini, MD  
*Neuroradiology*

Thomas B. Nguyen, MD  
*Ultrasound/Breast Imaging (SFGH)*

Nandini Patel, MD  
*Neuroradiology*

Rainer N. Poley, MD  
*Interventional*

Lauren Raher, MD  
*Abdominal Imaging/Breast Imaging*

Ramin Saket, MD  
*Neuroradiology*

Peter Shen, MD, PhD  
*Neuroradiology*

Bruno Soares, MD  
*Neuroradiology*

Simon Tam, MD  
*Cross Sectional Imaging (SFGH)*

James Tatum, MD  
*Neurointerventional*

David Thoma, DO  
*Musculoskeletal Imaging*

Jeffrey Tsai, MD  
*Cross Sectional Imaging (VAMC)*

Alina Uzelac, DO  
*Neuroradiology*

Phillip Vinh, DO  
*Abdominal Imaging*

Cuong Vuong, MD  
*Breast Imaging/Ultrasound*

Sun J. Young, MD  
*Neuroradiology*

## Diagnostic Radiology and Nuclear Medicine Residency Graduates—Class of 2010

Congratulations to our 2010 graduates. We wish them success in their new positions.

### Residents in Diagnostic Radiology

**Peter Jun, MD**

Fellowship in Neuroradiology, UCSF

**Nayela Keen, MD**

Fellowship in Neuroradiology, UCSF

**Maureen P. Kohi, MD**

Fellowship in Interventional  
Radiology, UCSF

**Shilpa R. Kumbhani, MD**

Fellowship in Abdominal Imaging  
and Breast Imaging, UCSF

**Sharon W. Kwan, MD**

Fellowship in Interventional  
Radiology, UCSF

**Heather G. Moreno, MD**

Fellowship in Abdominal Imaging  
and Breast Imaging, UCSF

**Reema Munir, MD**

Fellowship in Abdominal Imaging  
and Breast Imaging, UCSF

**David M. Naeger, MD**

Fellowship in Nuclear Medicine  
and Cardiac and Pulmonary  
Imaging, UCSF

**Rainer N. Poley, MD**

Fellowship in Interventional  
Radiology, UCSF

**Lauren Raher, MD**

Fellowship in Abdominal Imaging  
and Breast Imaging, UCSF

**Katherine To'o, MD**

Fellowship in Body Imaging,  
Stanford University



Graduation 2010: (l-r) Peter Jun, MD, Sharon W. Kwan, MD, Rainer N. Poley, MD, Maureen P. Kohi, MD, David M. Naeger, MD, Chairman Ronald L. Arenson, MD, Program Director Aliya Qayyum, MBBS, Lauren Raher, MD, Nayela Keen, MD, Heather G. Moreno, MD, Shilpa R. Kumbhani, MD, Katherine To'o, MD, Reema Munir, MD, Associate Program Director David E. Avrin, MD, PhD.

## Residents in Nuclear Medicine

**David M. Carlson, MD**

Fellowship in Computed Tomography, UCSF

**Nhan T. T. Nguyen, MD**

Pool Physician, Kaiser Permanente, Vallejo, Calif.



2010 Nuclear Medicine  
residency graduate  
Nhan T.T. Nguyen, MD



2010 Nuclear Medicine residency graduate David M. Carlson, MD,  
(left) with Chief and Program Director Miguel Hernandez Pampaloni,  
MD, PhD (right)

## The Margulis Society

The highlight of The Margulis Society's activities in 2010 was the inaugural Margulis Society Alumnus lecture held on March 17. William R. Brody, MD, PhD, president of the Salk Institute spoke on "Imaging, Health Care and the Model T Ford." His thought-provoking presentation explored the challenges inherent in providing high-quality health care and offered ideas on how to attain excellence in health care. His roles in academia and innovative research fields provided a unique perspective on health care issues. Prior to his leadership role at The Salk Institute, Brody served as the president of The Johns Hopkins University. He received his MD and PhD from Stanford University and completed his diagnostic radiology residency training at UCSF.

Alumni, faculty, and residents who attended the lecture were honored to have the opportunity to hear Brody speak, to see him again, or to meet him for the first time. This biennial lecture will recognize a distinguished UCSF Radiology alumnus who has succeeded in life, academia, or the private sector.

### Kwan Awarded for Outstanding Resident Research

Senior resident Sharon Kwan, MD, received the 2010 Margulis Society Outstanding Resident Research Award at the department's commencement dinner on June 4. During her residency, Kwan received a National Institutes of Health T-32 training grant and a departmental seed grant and was an author on several published articles. In addition, she was honored with the RSNA Research and Education Foundation 2010 Roentgen Resident Research Award.

"Dr. Kwan has been very productive as a resident, working on multiple publications and demonstrating great promise in her research efforts," said Christopher J. Schultz, MD, president of The Margulis Society, who presented the award. Schultz noted that Kwan will continue at UCSF as a fellow in the Interventional Radiology section.

### Career Conference 2010

Residents and fellows gathered at the home of board member Donna Hoghooghi, MD, for this year's annual Margulis Society career evening on July 28. This event provides a venue for residents and fellows to gain information on



Margulis Society Career Conference Panelists 2010: (l-r, top row) Drs. Chris Schultz, Jim Chen, Erik Gaensler, David Avrin, Ron Arenson, (l-r, bottom row) Jeffrey Dieden, Aliya Qayyum, Mike Rizzo, Derk Purcell, Donna Hoghooghi.

careers in academia and private practice tracks and the current job climate. The strong alumni base in the Department of Radiology and Biomedical Imaging allows residents and fellows to benefit from the experience of our alumni. Everyone enjoyed the informal discussions about career paths.

### 20th Anniversary Coming in 2011

Next year is the 20th anniversary of the Margulis Society. Since 1991, the Society has pursued our goal of supporting and enhancing resident and fellow training at UCSF. The Society lends financial support to many aspects of the department's residency and fellowship teaching programs, while fostering a continuing relationship among alumni, trainees, and faculty.

Mark your calendars for our anniversary gala and fundraiser on Saturday, March 12, 2011 at the Olympic Club in downtown San Francisco. Guests will enjoy an evening of food, music, and dancing as well as an exciting live auction. We hope you will be able to join the celebration.

REMEMBER TO SAVE THE EVENING OF  
SATURDAY, MARCH 12, 2011  
FOR THE  
***Margulis Society***  
***20th Anniversary Gala Fundraiser***  
OLYMPIC CLUB  
*Downtown San Francisco*



## Margulis Society Board of Directors

Christopher J. Schultz, MD  
*President*

Diego E. Ruiz, MD  
*President-Elect*

Donna Hoghooghi, MD  
*Immediate Past-President*

## Board Members:

Ronald L. Arenson, MD  
James S. Chen, MD, PhD  
Nick G. Costouros, MD  
Jeffrey D. Dieden, MD  
Erik H.L. Gaensler, MD  
Christine M. Glastonbury, MBBS  
Christopher K. Hoffman, MD

Camilla E. Lindan, MD  
Vincent D. McCormick, MD  
Peter S. Moskowitz, MD  
Derk D. Purcell, MD  
Aliya Qayyam, MBBS  
Gautham P. Reddy, MD, MPH  
Volney F. Van Dalsem, MD  
Benjamin M. Yeh, MD

## Faculty, Alumni and Residents Enjoy the Inaugural Margulis Alumnus Lecture and Reception

March 17, 2010



William R. Brody, MD, PhD, and  
Ron Arenson, MD



Drs. Richard Sollitto, Volney Van Dalsem, and Bill Dillon



Dr. Sharon Kwan with speaker  
William R. Brody, MD, PhD



(l-r) Jim DeMartini, MD, Kathryn Efird, Susan  
Wall, MD, Richard Sollitto, MD, Terril Efird, MD



Dr. Brody accepts plaque  
from Dr. Peter S. Moskowitz



(l-r) Drs. Hideyo Minagi, Ingrid Burger, Andrew  
Phelps, Charles Gooding, and Thor Johnson



Inaugural Margulis Alumnus Lecture, March 17, 2010



Drs. Avanti Ambekar and  
Pallav Kolli

PHOTOGRAPHS BY ELISABETH FALL PHOTOGRAPHY

## The Margulis Society Donor List

The Margulis Society gratefully acknowledges the following individuals for their generous contributions. This list reflects gifts made between July 1, 2009 and June 30, 2010.

Ashley Aiken, MD  
 Avanti Ambekar, MD  
 Shalin Amin, MD  
 Ronald L. Arenson, MD \*  
 David E. Avrin, MD, PhD  
 John J. Baehr, III, MD  
 Irene Balcar, MD  
 A. James Barkovich, MD  
 Susan Barrows, MD  
 Courtney Bloomer, MD  
 James Branscom, MD  
 Miriam A. Bredella, MD  
 William R. Brody, MD, PhD \*  
 Ben Maurice Brown, MD  
 Thomas J. Bryce, MD  
 Elizabeth S. Burnside, MD, MPH  
 Kevin J. Callahan, MD  
 Marianna Caponigro, MD  
 John J. Carolan, MD  
 Margaret H. Chaffey, MD  
 Frank S.H. Chang, MD  
 Saadia Chaudhary, MD  
 Mark Z.K. Chen, MD  
 Jing S. Chen, MD  
 James S. Chen, MD, PhD  
 Daryl H. Chinn, MD  
 Iris B.S. Choo, MD  
 Nathaniel A.H. Chuang, MD \*  
 Fergus V. Coakley, MD  
 Jeremy D. Collins, MD  
 Cirrelda Cooper, MD \*  
 Nick G. Costouros, MD  
 Geoffrey I. Criqui, MD  
 Ms. Cathy Ann Cronin-Pastrano  
 Lawrence E. Crooks, PhD \*

Tracey A. Dellaripa, MD  
 Wm. James DeMartini, MD  
 Jeffrey D. Dieden, MD  
 William P. Dillon, MD  
 Christopher F. Dowd, MD  
 Terril A. Efird, MD  
 Thomas H. Farquhar, MD  
 Vickie A. Feldstein, MD  
 Charles E. Fiske, MD  
 Kathleen M. Flores-Dahms, MD  
 Russell C. Fritz, MD  
 Erik H.L. Gaensler, MD  
 Alisa Gean, MD \*  
 Christine Glastonbury, MBBS  
 John S. Gletne, MD  
 James L. Gorder, MD  
 Roy L. Gordon, MD  
 Michael B. Gotway, MD \*  
 Richard C. Gross, MD  
 Elizabeth A. Guillaumin, MD \*  
 Stanley F. Handel, MD  
 Lawrence P. Harter, MD  
 Steven W. Hetts, MD  
 Daniel R. Hightower, MD  
 Christopher K. Hoffman, MD \*  
 Donna Hoghooghi, MD  
 Julian B. Holt, MD  
 Patricia Rhyner Hudgins, MD  
 Hedvig Hricak, MD  
 John C. Hunter, MD  
 Richard P. Jacobs, MD  
 Pamela S. Jensen, MD  
 James O. Johnston, MD  
 Peter J. Julien, MD  
 Peter Jun, MD

---

\*Donation of \$1000 or more

Carl Kalbhen, MD  
Amita Kamath, MD  
Leon G. Kaseff, MD  
Jane J. Kim, MD  
Donald R. Kirks, MD  
Jeffrey S. Klein, MD  
Naveen N. Kumar, MD  
Anthony G. Laglia, MD  
Annie P.W. Lai, MD  
Faye C. Laing, MD  
Magge Lakshmi, MD  
Theodore C. Larson, III, MD  
Edward A. Lebowitz, MD  
F. Chaney Li, MD  
Camilla E. Lindan, MD  
Lawrence Litt, MD, PhD  
Rose Liu, MD  
Jay Mall, MD  
Vincent D. McCormick, MD  
Marcia J. McCowin, MD  
Kathleen M. McKenna, MD  
Edward M. Miller, MD  
Hideyo Minagi, MD \*  
James M. Moorefield, MD  
Peter S. Moskowitz, MD  
Brian K. Nagai, MD  
James A. Nelson, MD  
T. Hans Newton, MD  
John D. Noonan, MD  
David Norman, MD  
Karen Ordovás, MD  
Dennis S. Orwig, MD  
Chad C. Palmer, MD  
Kent D. Pearson, MD  
Kathryn L. Pearson Peyton, MD  
Donald J. Ponec, MD  
Mark J. Popovich, MD  
Derk D. Purcell, MD  
Aliya Qayyum, MBBS  
Gautham P. Reddy, MD, MPH  
Stanley B. Reich, MD  
Gregory Rogalski, MD  
Diego E. Ruiz, MD  
H.Q. Sakai, MD \*

David A. Saloner, PhD  
John D. Schrumpf, MD  
Christopher J. Schultz, MD \*  
David M. Scovill, MD  
Clark L. Searle, MD  
William J. Shea, MD  
Douglas J. Sheft, MD  
Edward A. Sickles, MD \*  
Rita E. Sohlich, MD  
Mr. Robert M. Stafford  
Lynne S. Steinbach, MD  
Susan K. Stevens MD  
Lori M. Strachowski, MD  
Yee-Li Sun, MD  
Judy K. Tam, MD  
Frank R. Tamura, MD  
Robert C. Taylor, DDS  
Corito S. Tolentino, MD  
Ronald R. Townsend, MD  
Volney F. Van Dalsem III, MD  
Nina S. Vincoff, MD  
Thienkhai Vu, MD, PhD  
Susan D. Wall, MD  
Z. Jane Wang, MD  
Nikunj P. Wasudev, MD  
Antonio Westphalen, MD  
A. Alan White, MD  
Michael Williams, MD  
John S. Wilson, Jr., MD  
Stephen P. Yeagle, MD  
Benjamin M. Yeh, MD  
Melissa B. Yu, MD  
Esther L. Yuh MD, PhD  
Gregory G. Zaharchuk, MD

Special thanks to the following corporate donors  
for their generous support of the  
Inaugural Margulis Society Alumnus Lecture:

**Philips Healthcare**

**Siemens Medical Solutions**

## Alumni News 2010

**1967**

**Douglas J. Sheft, MD**, of Tiburon, Calif., a radiologist at St. Francis Memorial Hospital in San Francisco, was awarded the Outstanding Clinical Faculty Award at commencement by the UCSF Department of Radiology and Biomedical Imaging.



Ron Arenson presents Outstanding Clinical Faculty Award to Douglas Sheft

**1971**

**Jesse Kahn, MD**, of Carmel, Calif. and his wife Carol have two new grandsons, Mason and Zack, both born in 2009. He writes that he is doing some “fill-in” radiology for the Salinas Group and that “life is good ... enjoying bridge, including class instruction, photography, and hiking.” He volunteers at the U.S. Open in Pebble Beach each June and sends his “best to all my fellow UCSF residents.”



Jesse Kahn enjoys his off-time at the U.S. Open

**1973**

**Faye Laing, MD**, of Washington, DC, joined the radiology faculty at Georgetown, where she works with her fellow UCSF radiology residents: **Jim Spies, MD**, department chair (UCSF resident, 1984) and **Cirrelda Cooper, MD**, department vice-chair (UCSF resident, 1984).

**1979**

**Michael P. Federle, MD**, of Palo Alto, Calif, was named the 2010 Society of Gastrointestinal Radiologists (SGR) Walter Bradford Cannon Medalist. A professor of diagnostic radiology at Stanford University, Federle was honored during the 2010 Abdominal Radiology Course in Orlando, Fla., at the SGR awards ceremony.

**1980**

**Gary M. Glazer, MD**, of Palo Alto Calif. was awarded the Radiological Society of North America’s highest honor, the Gold Medal, in November 2009. Glazer is the chair of the Department of Radiology at Stanford University.

**1991**

**Ziv J. Haskal, MD**, of Cockeysville, Md., was named editor of the *Journal of Vascular and Interventional Radiology* for a five-year term. Haskal is vice-chair and a professor of radiology and surgery, chief of vascular and interventional radiology, and director of interventional oncology and image-guided therapy at the University of Maryland Medical Center in Baltimore.

**1996**

**Suzanne E. Anderson, MD**, of Sydney, Australia, gave the European Congress of Radiology’s 2010 Josef Lissner honorary lecture in Vienna, Austria, where she was thrilled to see several UCSF faculty and alumni in the audience. Anderson is chair of medical imaging at Sydney Medical School, University of Notre Dame in Sydney. Recently, she contributed to writing the formal radiology registrar training program and syllabus and the musculoskeletal syllabus for nationwide use in Australia and New Zealand, and organizing the radiology registrar scientific research presentation process for the Royal College of Australian and New Zealand Radiologists. On a personal note, her eight-year-old son Salomon is “truly bilingual, well travelled, and superb at both skiing and tennis!” She sends greetings and says “Thank you to UCSF!”



Anderson called her week’s work with ISS OutReach in Thailand, “one of the best experiences” she has had.



**2002**

**Michael A. Carducci, MD**, of Las Vegas, Nev., and his wife Anne sent recent photos of Dana, five and Rafael, two. They say that this year “Dana will be starting Kindergarten and Rafa will be hanging out with Mom.”



Michael Carducci, MD, and daughter Dana with son Rafael (inset)

**2006**

**Susan Hobbs, MD, PhD**, of Rochester, NY is an assistant professor and head of the Cardiothoracic Imaging section

in the Department of Imaging Sciences at the University of Rochester Medical Center.

**2009**

**Michael Ringler, MD**, of Rochester, Minn. is now on staff in the Musculoskeletal Division of the Department of Radiology at the Mayo Clinic in Rochester.

**Amita Kamath, MD, MPH**, of New York City, NY, has joined the Abdominal Imaging Department of Mount Sinai Medical Center as an assistant professor of Radiology. Her area of expertise is Body MRI, and particular areas of interest are female pelvis, liver, kidney, and pancreas imaging.

**2005**

## Wirt Writes from Afghanistan



Michael Wirt in body armor (about 50 lbs).

Michael Wirt, MD, is serving as the Task Force Surgeon for Task Force STRIKE, 502nd Infantry Regiment, 2nd Brigade Combat Team, 101st Airborne Division (Air Assault) in Kandahar province, Afghanistan. He provides health care to more than 5,700 soldiers, along with medical assistance and training to members of the Afghan National Security Forces. The primary wartime function of the Brigade's Medical Section is to coordinate and facilitate medical evacuation (MEDEVAC) missions for wounded soldiers on the battlefield and track casualties through the entire evacuation process.

“Believe it or not, from the middle of a virtual desert, I am doing some radiology! We have basic digital X-ray and ultrasound (performed by yours truly) at our Forward Operating Base Clinic (using the term clinic somewhat loosely). Our facility serves as both a primary care clinic and field trauma resuscitation point. Through the wonders of teleradiology, I can follow the imaging studies of our soldiers through their journey from Kandahar to Landstuhl, Germany and on to the U.S. It only took me two months to figure out how to get it all connected, but it has proven to be a valuable

resource in our patients' care, not to mention, keeping me reading film.

“One of our non-combat roles is enabling the Afghan people to improve their healthcare infrastructure. We conduct health *shuras* (meetings) with local leaders and health representatives, physicians, and village elders. In lieu of providing direct care and medical supplies, we work with the government of Afghanistan to generate sustainable programs for communities, administered by their physicians and health workers. It is one of the most rewarding components of the mission. No shura is complete without food and tea. The Afghan hospitality is wonderful.

“My time in the Neuroradiology section provided me with a foundation to overcome obstacles and challenges, just the ticket for my year in Afghanistan.”



Soldiers conducting a MEDEVAC procedure.

## Surbeck Young Investigators Awards

Dorothy Ahrens

The fourth Annual Surbeck Young Investigators Awards produced some surprise “firsts” this year. Peder Larson, PhD, took first place out of the 18 scholars who submitted work. Larson was a Surbeck Scholar in 2009, making him the first scholar to receive honors in consecutive years. Karl Saldanha and Christopher Ward with co-author Humsa Venkatesh tied for second place honors. This was the first time co-authors shared an award. Cornelius von Morze took third place.

Awardees presented their work to a capacity audience on February 26 in Bakar Auditorium at the new Helen Diller Family Comprehensive Cancer Center. Professor Sarah J. Nelson, PhD, director of the Surbeck Laboratory of Advanced Imaging and Richard Gowen, PhD, president of the Board of the INDJNC Foundation moderated.

### First Place: Larson’s Study of Fast Dynamic 3-D MRSI

Top honors went to Peder Larson for “Fast Dynamic 3D MRSI with Compressed Sensing and Multiband Excitation Pulses for Hyperpolarized  $^{13}\text{C}$ ,” Peder E. Z. Larson, Simon Hu, Michael Lustig, Adam B. Kerr, Sarah J. Nelson, John Kurhanewicz, John M. Pauly, Daniel B. Vigneron.

In summary: Hyperpolarized  $^{13}\text{C}$  MRSI provides unique metabolic tissue information, which can improve the distinction of cancerous tissue. The hyperpolarized signal decays to thermal equilibrium rapidly, requiring rapid imaging techniques. Imaging the dynamic perfusion and conversion of the metabolites provides additional tissue information, but requires methods that use hyperpolarization efficiently. We developed a time-resolved 3D MRSI method for hyperpolarized  $^{13}\text{C}$  by combining compressed sensing methods for acceleration and multiband excitation pulses to use the magnetization efficiently. This method achieved a two-second temporal resolution with full volumetric coverage of a mouse. Metabolites were observed for up to 60 seconds following injection of hyperpolarized  $[1-^{13}\text{C}]\text{-pyruvate}$ . The compressed sensing acquisition used random-phase encoded gradient blips to introduce sampling pattern incoherency, a pattern that we varied for each time point to create random undersampling in four dimensions. The multiband excitation pulse had a smaller



Dr. Gowen, President of the INDJNC, presents first place award to Dr. Peder Larson.

flip angle for the  $[1-^{13}\text{C}]\text{-pyruvate}$  substrate because it was more highly concentrated than its metabolic products ( $[1-^{13}\text{C}]\text{-lactate}$  and  $[1-^{13}\text{C}]\text{-alanine}$ ). As a result, the pulse used less of the overall hyperpolarization per excitation. Combining compressed sensing acceleration and multiband excitations enabled us to observe perfusion and uptake of the pyruvate, and the conversion dynamics to lactate and alanine throughout a volume with high spatial and temporal resolution.

Larson graduated from Stanford University’s Department of Electrical Engineering, and has worked as a post-doctoral scholar in Professor Daniel Vigneron’s lab since August 2007.

### Three Authors Share Second Place

Karl Saldanha’s article, “Micrometer-sized Iron Oxide Particle Labeling of Mesenchymal Stem Cells for Magnetic Resonance Imaging Based Monitoring of Cartilage Tissue Engineering,” Karl Saldanha, Ryan Doan, Kristy M. Ainslie, Sharmila Majumdar, put him among the second-place winners. The article is under review by *Magnetic Resonance Imaging*.

Saldanha is a fourth-year graduate student in the UCB/UCSF joint graduate program in Bioengineering, working in Professor Sharmila Majumdar's lab. He received a BS in Bioengineering from UC Berkeley in 2005, where he also completed the Management of Technology program.

Also receiving second place awards were co-authors Chris Ward and Humsa Venkatesh for their article, "Non-invasive Detection of Target Modulation following Phosphatidylinositol-3-Kinase Inhibition using Hyperpolarized  $^{13}\text{C}$  Magnetic Resonance Spectroscopy," Christopher S. Ward, Humsa S. Venkatesh, Myriam M. Chaumeil, Alissa H. Brandes, Mark VanCrickinge, Hagit Dafni, Subramaniam Sukumar, Sarah J. Nelson<sup>1</sup>, Daniel B. Vigneron, John Kurhanewicz, C. David James, Daphne A. Haas-Kogan, Sabrina M. Ronen.

Ward and Ventaksh are staff research associates in Associate Professor Sabrina Ronen's lab. Ward received his BA in chemistry from Carleton College in 2007 and will start a PhD program in Toxicology and Environmental Health in the fall of 2010. Venkatesh received her BS from UC Berkeley and will start medical school in the fall.

#### **Von Morze Awarded Third Place**

The paper, "Reduced Field of View Diffusion Weighted Imaging of the Brain at 3T and 7T," Cornelius von Morze, Douglas A.C. Kelley, Timothy M. Shepherd, Suchandrima Banerjee, Duan Xu, Christopher P. Hess earned Cornelius von Morze, PhD, third place. The article is in press with *Magnetic Resonance Imaging*.



(l-r, top row) Chris Ward, Dr. Peder Larson, Cornelius von Morze, (l-r, bottom row) Humsa Venkatesh, and Karl Saldhana

Von Morze is a post-doctoral scholar in Professor Daniel Vigneron's lab. He graduated from the UCB/UCSF joint graduate program in Bioengineering.

The Margaret Hart Surbeck Laboratory of Advanced Imaging is dedicated to advancing imaging techniques for biological and medical applications. The Young Investigator Awards provide small grants for career development and are funded through the INDNJC Foundation honoring Margaret Hart Surbeck.



## The Henry I. Goldberg Center for Advanced Imaging Education

In 2010, the Henry I. Goldberg Learning Center fundamentally changed its approach to leadership with the creation of the Medical Student Education Committee. This committee brings together a group of faculty and resident educators committed to improving and re-imagining the role of radiology in physician training at UCSF. The committee oversees all areas of radiology education for the School of Medicine with each member concentrating on a specific area of interest. It also serves as an important sounding board for discussing new educational ideas and plans for implementing them. The Medical Student Education Committee members include: Brett Elicker, MD, Vickie Feldstein, MD, Christine Glastonbury, MBBS, David Naeger, MD, Andrew Phelps, MD, Rajiv Sawhney, MD, Gabe Schneider, MD, Lynne Steinbach, MD, Khai Vu, MD, PhD, and Emily Webb, MD. A big thanks to this team for all of their efforts this year.

One of the committee's first areas of focus was reframing the radiology content in the preclinical core curriculum. Progress to date includes redesigning and expanding the number of multidisciplinary labs and small group teaching sessions which combine radiology content with either pathology or clinical oncology material. Other new radiology correlation materials were developed for teaching in the anatomy labs. These efforts will provide medical students better exposure to the field of radiology early in their stud-

ies and in diverse academic settings, not limited to the lecture hall.

The committee is also hard at work honing the curriculum for the numer-

ous electives offered by the Department of Radiology and Biomedical Imaging. One exciting change is a "core" lecture series for medical students enrolled in various senior electives at Parnassus, San Francisco General Hospital, and the Veterans Affairs Medical Center. Students from all sites will gather at the Learning Center one day a week to benefit from this series of lectures on fundamental radiology topics.

The committee also needed to find a fantastic Education Coordinator who could keep the entire show running. We were very lucky to recruit Melinda Parangan-Chu for this position. She serves as an invaluable liaison between our department and the medical school. We are confident her efforts will have an enormous beneficial impact on students.

Many UCSF faculty, volunteer faculty, fellows, and residents give generously of their time in all of the Goldberg Learning Center's programs. Our residents in particular have increased their contributions in recent months, developing new lectures for the senior electives and designing new learning assessments. Their efforts are very much appreciated and we hope will help some of them recognize a passion for teaching that will lead them into careers in academic radiology.

The Henry I. Goldberg Center for Advanced Imaging Education is the hub for medical student education in the Department of Radiology and Biomedical Imaging. The center coordinates radiology lectures and labs in the pre-clinical core curriculum, provides imaging workshops during clinical clerkships, and offers a variety of classroom and clinical radiology electives designed to expose medical students to different areas of emphasis within the field.

For more information about the Goldberg Learning Center's activities, please contact Melinda Parangan-Chu ([Melinda.Parangan-Chu@radiology.ucsf.edu](mailto:Melinda.Parangan-Chu@radiology.ucsf.edu)) or visit our website at [radiology.ucsf.edu/education/medical-students](http://radiology.ucsf.edu/education/medical-students).



Emma Webb, MD, chair, Medical Student Education Committee.



Medical students enjoy pizza after completing the 140.03 Radiology elective in Goldberg Center.



## Radiology Postgraduate Education

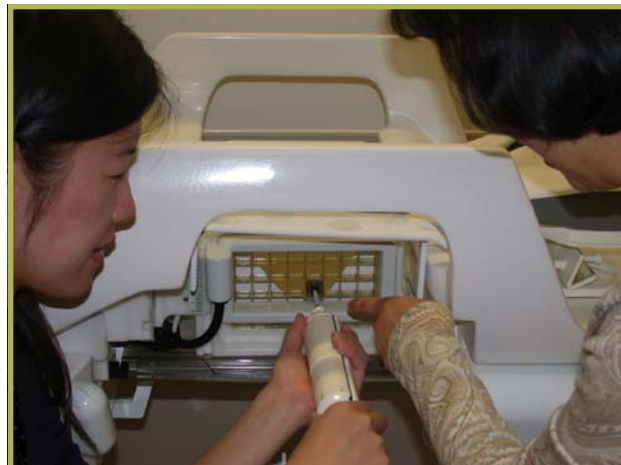The Department of Radiology and Biomedical Imaging continues its efforts to provide outstanding postgraduate courses in a variety of settings and educational formats. Known for excellence in content, delivery, and organization, Radiology Postgraduate Education instituted many new initiatives this past year, with more to come in 2011.

### CME Courses Earn Attendee Praise

Our first **UCSF Radiology Highlights** course, offered in October 2009, garnered outstanding reviews from the attendees for its modified format of 20-minute focused, clinically relevant presentations. One attendee commented “I expected this to be a good course, but it was excellent! It exceeded my expectations. I would come back again.” The second offering, held a year later, included two Self-Assessment Modules (SAM), case-based sessions utilizing audience response systems and a new feature: film panels. Panels on abdominal, ultrasound, and neuroimaging showed how the speakers reached their differential diagnoses on unknown cases. Watch for the third annual **UCSF Radiology Highlights** course in the fall of 2011.

In June 2010, more than 100 attendees joined us in Bermuda for our **Brain, Body, and Breast Imaging** course chaired by Lori Strachowski, MD, chief of Women’s Imaging at San Francisco General Hospital. After high-quality presentations in the morning, the attendees were free to enjoy the many attractions and activities in Bermuda, ranging from its pink sand beaches, and historical forts and towns to snorkeling along majestic coral reefs and fascinating shipwrecks. For the faculty, the highlight of the trip was a reception hosted by Dr. Maureen Burke, a local radiologist who regularly attends UCSF courses. At her oceanfront home, the speakers and their families had an opportunity to talk shop with Burke and three other local radiologists.

UCSF continues to be a leader in Virtual Colonoscopy training. Judy Yee, MD, vice-chair of radiology and chief of radiology service at the Veterans Affairs Medical Center, organizes these two-and-a-half day intensive hands-on workshops three times a year. The workshops include a half-day devoted to workstation orientation and participants receive a copy of her textbook, “Virtual Colonoscopy.”



Drs. Belinda Chang, course director, and Bonnie Joe, chief, Women’s Imaging, demonstrate MRI-guided breast biopsy.

Attendees benefit from small group, hands-on workstation training and review 50 proven, ACR-approved, virtual colonoscopy cases. Check our 2011 calendar (pg. 61) for next year’s workshop dates.

Each year we offer three **Breast Imaging** courses: a January course on the Big Island of Hawaii, a March course in San Francisco, and one in November in the Palm Springs area. The Hawaii and Palm Springs courses include an optional Digital Mammography Mini-Course, so attendees can complete their required initial eight hours in full-field digital mammography. In 2010, the San Francisco course offered a new, hands-on workshop on stereotactic and MRI-guided breast biopsy. Several vendors provided equipment so attendees could familiarize themselves with various machines and practice targeting. Attendees rated this hands-on component highly: “Excellent! Having the multiple vendors was terrific.” The next Breast Imaging course in San Francisco will be March 18-20, 2011 at The Westin Market Street San Francisco Hotel. It will include an expanded hands-on breast biopsy workshop.

### UCSF Radiology Meetings Go Green

We are making our meetings more environmentally sensitive. For example, instead of paper copies, each attendee now receives a high-resolution electronic syllabus. The electronic



Vancouver, British Columbia, international CME destination 2011

version allows the attendee to view the images in color and to zoom in on images, something a paper syllabus can't do. Other green efforts include reducing our environmental footprint at our courses, for example by using water stations rather than individual water bottles; providing coffee cups or mugs that can be washed rather than disposable "to go" cups and selecting hotels with the best environmentally sensitive practices.

### **New Topics and New Locations for 2011**

We will offer a new course, **Cardiovascular and Pulmonary Imaging**, on January 30-February 1 in Indian Wells (Palm Springs), Calif. Chaired by Brett Elicker, MD, chief of Cardiac and Pulmonary Imaging, the course features two of UCSF's most well-known faculty, Charles Higgins, MD, and W. Richard Webb, MD. This three-day course will be followed by **Abdominal and Pelvic Imaging** led by Linda Poder, MD. Both courses will be held at a new venue,

the Miramonte Resort & Spa, located in the heart of Palm Springs Valley. The Well Spa at the Miramonte was named in "Top Ten Resort Spas in North America and the Caribbean" by Condé Nast Traveler.

For our 2011 international offering we will travel north to Vancouver, British Columbia, home of the 2010 Winter Olympics. Join us on June 20-24 at the historic Fairmont Vancouver Hotel, located in the heart of the city close to shops and a wealth of entertainment options. Thomas Link, MD, PhD, chief of Musculoskeletal Imaging will chair the course, featuring guest speakers from the University of British Columbia. Known for its spectacular scenery and energetic lifestyle, Vancouver lies between majestic coastal mountains and the tides of the Pacific Ocean. Special rates will be offered for pre- or post-course stays at The Fairmont Chateau Whistler, nestled at the base of Blackcomb Mountain. Experience the energy and excitement of the recent Olympic Games with an abundance of summer activities and events. Vancouver is the perfect starting point for an Alaskan cruise, if you wish to extend your vacation.

Our speakers and staff are always pleased to welcome alumni at our postgraduate courses. Our travel courses make the perfect destination for a class reunion, combining education, vacation, and camaraderie in distinctive settings. If we can help facilitate your reunion activities in conjunction with a postgraduate course, please contact us at [cme@radiology.ucsf.edu](mailto:cme@radiology.ucsf.edu) or speak with Katie Murphy, Event and Alumni Coordinator. Please remember to take advantage of the \$50 alumni discount when you register for courses. We look forward to seeing you at one of our 2011 offerings. If you have suggestions for new topics or venues for us, please feel free to contact us; we are always open to new ideas.

# 2011 Radiology CME Calendar

## **January 3–7, 2011**

Imaging and Intervention on the Mayan Riviera  
The Fairmont Mayakoba Resort – Playa del Carmen, Mexico

## **January 9–14, 2011**

Breast Imaging & Digital Mammography  
The Fairmont Orchid – Kona, Hawaii

## **January 16–21, 2011**

Body Imaging: Hot Topics in the Tropics  
The Fairmont Orchid – Kona, Hawaii

## **January 30–February 1, 2011**

Cardiovascular and Pulmonary Imaging  
Miramonte Resort and Spa – Indian Wells, California

## **February 2–4, 2011**

Abdominal and Pelvic Imaging: CT/MR/US  
Miramonte Resort and Spa – Indian Wells, California

## **February 13–18, 2011**

Neuro and Musculoskeletal Imaging  
The Fairmont Orchid – Kona, Hawaii

## **February 24–26, 2011**

Virtual Colonoscopy Workshop  
UCSF China Basin Research Center – San Francisco, California

## **March 6–11, 2011**

UCSF Radiology Annual Review  
The Fairmont San Francisco – San Francisco, California

## **March 13–18, 2011**

Spring Training for Radiologists  
The Fairmont Scottsdale Resort – Scottsdale, Arizona

## **March 18–20, 2011**

Breast Imaging Update  
The Westin San Francisco Market Street – San Francisco, California

## **May 22–27, 2011**

Practical Applications in Diagnostic Radiology  
Tenaya Lodge at Yosemite National Park – Fish Camp, California

## **June 9–11, 2011**

Virtual Colonoscopy Workshop  
UCSF China Basin Research Center – San Francisco, California

## **June 20–24, 2011**

Body and Bone in British Columbia  
The Fairmont Vancouver – Vancouver, British Columbia

## **August 15–19, 2011**

Imaging Update in the Mountains  
Hotel Terra Jackson Hole – Teton Village, Wyoming

## **September 15–17, 2011**

Virtual Colonoscopy Workshop  
UCSF China Basin Research Center – San Francisco, California

## **September 12–16, 2011**

Interventional Radiology Review  
UCSF Parnassus Campus – San Francisco, California

## **October 2–7, 2011**

Women's Imaging in Wine Country  
The Fairmont Sonoma Mission Inn & Spa – Sonoma, California

## **October 17–21, 2011**

UCSF Radiology Highlights  
San Francisco, California

## **October 30–November 4, 2011**

Diagnostic Radiology Seminars  
Hyatt Regency Resort and Spa – Maui, Hawaii

## **November 7–11, 2011**

Breast Imaging and Digital Mammography  
Palm Springs, California

## **December 4–9, 2011**

Imaging Warm-Up in the Caribbean  
The Westin Resort St. John – St. John, US Virgin Islands

## **2011–12 CALENDARS NOW AVAILABLE ONLINE!**

**For further information please contact:**

Radiology Postgraduate Education, UCSF School of Medicine  
3333 California Street, Suite 375, San Francisco, CA 94143-0629

Tel: 415/476-5731 Fax: 415/476-9213 E-mail: [cme@radiology.ucsf.edu](mailto:cme@radiology.ucsf.edu) Web: <http://radiology.ucsf.edu/postgrad>

*Course dates and locations are subject to change without notice before publication of a final brochure.*

*Please visit our website for the most current information.*

## Imaging Research Symposium Highlights Departmental Research and Second Bruce Hasegawa Award

The Department of Radiology and Biomedical Imaging's Seventh Annual Imaging Research Symposium "provided a snapshot of the diversity and depth of the excellence in research in our department. It brought the achievements of high school, college, medical and graduate students, post-docs, fellows, residents, and faculty to the forefront," according to Sharmila Majumdar, PhD, vice-chair of research.

It also was the occasion for bestowing the Second Annual Bruce Hasegawa Award on R. Dana Carpenter, PhD.

This year 103 abstracts were submitted, an increase of almost 20% over last year. A committee selected 18 abstracts for oral presentation and 62 for posters arrayed in the Milberry Union conference room.

As participants arrived at Cole Hall for the symposium they could review posters and talk with representatives of the department's 11 Research Interest Groups and Specialized Resource Groups.

Galatea Kazakia, PhD, and Esther Yuh, MD, PhD, headed this year's symposium planning committee and moderated the oral presentations, which covered a variety of multi-modality research topics and approaches to research. Christopher Drake, PhD, and Cornelius von Morze, PhD, received awards for Outstanding Speaker Presentation. Marram Olson, BS, and Laleh Jalilian, MD, received awards for Outstanding Poster.



R. Dana Carpenter accepts the Hasegawa Award.

### Carpenter Receives Hasegawa Award

Hasegawa award recipient R. Dana Carpenter, PhD, is a research scientist working in the Musculoskeletal CT Imaging Research Group directed by Thomas Lang, PhD.

In presenting the award, Department Chairman Ron Arenson, MD, noted Carpenter's many links to UCSF Radiology: "Tom Lang was Dr. Bruce Hasegawa's first postdoctoral scholar, so it is good to see his mentoring tradition continues. In addition, Dana's father, Paul Carpenter, MD, graduated from our diagnostic radiology residency program in 1975."

In his remarks, Carpenter said, "This award should serve as a reminder to all of us in the field of imaging research. Especially as young investigators, we often get caught up in the everyday details and intricacies of our very specialized research projects. But at the core of that work, the real goal is to improve our ability to diagnose and treat diseases and to improve patient care. I think that Bruce Hasegawa really exemplified this idea. It may be a lofty goal to hope that all of our projects will affect patient care as much as he did, but I think it is a worthy goal, and it's one that we should all strive to achieve."

The Bruce Hasegawa award recognizes a radiology and biomedical imaging graduate student or postdoctoral scholar. It is generously funded by Hasegawa's childhood friend, Dr. Gordon Honda. He and his wife Ruri attended the award reception.

Carpenter's family, wife Mary Beth and daughter Layla (who celebrated her first birthday the same day) joined him on September 1 to see him accept the second annual Hasegawa award.



## The Lanna Lee Award

Patients and employees at the Ambulatory Care Center's Radiology Department are in the "very caring hands" of Robert Holland, RT, and the recipient of the 2010 Lanna Lee Award. Director of Radiology Operations Kathy Knoerl described Holland as "a perfect example of Lanna Lee's work ethic." The award is given annually to the outstanding technologist in the Department of Radiology and Biomedical Imaging.

Holland, who retired in June 2010, joined the department in 1992 as a radiologic technologist. Over his years of service in an outpatient setting, many patients asked for him by name and remember his kind manner and exemplary skills. "His calm demeanor and constant professionalism are well-suited for a busy outpatient department like ours," Knoerl said. "He was always looking at ways to assist the patient and in his spare time he designed and built devices that improved patient positioning and comfort. I appreciated these unique skills, as it was both a service to patients while producing quality images."

As a primary technologist for the Ambulatory Care Surgery Center, the surgeons appreciated Holland's attention to detail and skilled use of the equipment. He was known for his excellent customer service and his ability to anticipate the radiologist's or surgeon's requests.

Holland also served as a clinical instructor for the City College of San Francisco Radiologic Technology Program and mentored many students who rotated through UCSF, along with new technologists hired in the department. "



Svetlana Lee, daughter of Lanna Lee, with Robert Holland, RT.

*The Lanna Lee Award was established in memory of Lanna Lee, a senior radiology technologist who died on her way home from work in 1989 during the Loma Prieta earthquake. Lee was a role model for others, always working with a smile and delivering excellent care to her patients. Since her death, this award is given annually in her honor. Her family regularly attends the award celebration to share in the knowledge that her spirit lives on.*

## Faculty Roster

### Chairman

#### Ronald L. Arenson, MD

Alexander R. Margulis Distinguished Professor

### Executive Vice-Chair

#### William P. Dillon, MD

Professor of Radiology  
Elizabeth A. Guillaumin Chair in Neuroradiology

### Vice-Chairs

#### David E. Avrin, MD, PhD

Professor of Clinical Radiology  
Vice-Chair, Informatics

#### Fergus V. Coakley, MD

Professor in Residence  
Vice-Chair, Clinical Affairs

#### Robert G. Gould, ScD

Professor in Residence  
Vice-Chair, Technology and Capital Projects

#### Sharmila Majumdar, PhD

Professor in Residence  
Vice-Chair, Research

#### Susan D. Wall, MD

Professor Emeritus  
Vice-Chair, Academic Affairs

#### Mark W. Wilson, MD

Professor in Residence  
Vice-Chair, San Francisco General Hospital

#### Judy Yee, MD

Professor in Residence  
Vice-Chair, Veterans Affairs Medical Center

### Abdominal Imaging

#### Rizwan Aslam, MD

Associate Clinical Professor

#### David E. Avrin, MD, PhD

Professor of Clinical Radiology

#### Seerat Aziz, MD

Assistant Clinical Professor

#### Fergus V. Coakley, MD

Professor in Residence and Chief

#### Bonnie N. Joe, MD, PhD

Associate Professor in Residence

#### Adam Jung, MD

Assistant Professor of Clinical Radiology

#### Liina Poder, MD

Associate Professor of Clinical Radiology

#### Aliya Qayyum, MBBS

Professor in Residence  
Director, Residency Program

#### Richard Sollitto, MD

Clinical Professor

#### Ruedi F.-L. Thoeni, MD

Professor in Residence

#### Z. Jane Wang, MD

Assistant Professor in Residence

#### Emily (Emma) M. Webb, MD

Assistant Professor of Clinical Radiology

#### Stefanie Weinstein, MD

Assistant Clinical Professor

#### Antonio C. Westphalen, MD

Assistant Professor in Residence

#### Benjamin M. Yeh, MD

Associate Professor in Residence

### Ambulatory Care Center

#### Helen B. Galvin, MD

Clinical Professor

#### Steven H. Ominsky, MD

Clinical Professor Emeritus

#### Richard A. Sollitto, MD

Clinical Professor and Chief

### Brain Behavior Research

#### Interest Group

#### Linda Chao, PhD

Associate Adjunct Professor

#### Roland G. Henry, PhD

Professor in Residence

#### Christopher P. Hess, MD, PhD

Assistant Professor in Residence

#### Tracy Luks, PhD

Assistant Adjunct Professor

#### Pratik Mukherjee, MD, PhD

Associate Professor in Residence and Co-Director

#### Srikantan S. Nagarajan, PhD

Professor in Residence and Co-Director

### Brain Cancer Research Interest Group

#### Soonmee Cha, MD

Associate Professor In Residence and Co-Director

#### Roland G. Henry, PhD

Professor in Residence

#### Tracy R. McKnight, PhD

Associate Professor in Residence

#### Sarah J. Nelson, PhD

Professor of Radiology and Co-Director  
Margaret Hart Surbeck Distinguished Professor in Advanced Imaging

#### Sabrina M. Ronen, PhD

Associate Professor in Residence

### Breast Cancer Research Interest Group

#### Belinda Chang, MD

Assistant Professor of Clinical Radiology

#### Nola M. Hylton, PhD

Professor in Residence and Co-Director

#### Bonnie N. Joe, MD, PhD

Associate Professor in Residence and Co-Director

#### John A. Shepherd, PhD

Assistant Professor in Residence

### Cardiac And Pulmonary Imaging

#### Brett M. Elicker, MD

Assistant Professor of Clinical Radiology and Chief

#### Charles B. Higgins, MD

Professor Emeritus

**Michael Hope, MD**

Assistant Professor in Residence

**Karen Ordovás, MD**

Assistant Professor in Residence

**Thomas Urbania, MD**

Assistant Professor of Clinical Radiology

**Center For Imaging of  
Neurodegenerative Disease—VAMC**

**Linda L. Chao, PhD**

Associate Adjunct Professor

**Dieter J. Meyerhoff, PhD**

Professor in Residence

**Susanne G. Mueller, MD**

Associate Adjunct Professor

**Norbert Schuff, PhD**

Adjunct Professor

**Colin Studholme, PhD**

Associate Professor in Residence

**Michael W. Weiner, MD**

Professor in Residence and Director

**Informatics and Image Processing/  
Display Specialized Resource Group**

**Ronald L. Arenson, MD**

Alexander R. Margulis Distinguished  
Professor

**David E. Avrin, MD, PhD**

Professor of Clinical Radiology and  
Director

**Jeremy Durack, MD**

Assistant Professor of Clinical Radiology

**Robert G. Gould, ScD**

Professor in Residence

**Colin Studholme, PhD**

Associate Professor in Residence

**Judy Yee, MD**

Professor in Residence

**Interventional Radiology**

**David E. Avrin, MD, PhD**

Professor of Clinical Radiology

**Miles Conrad, MD**

Assistant Clinical Professor

**Jeremy Durack, MD**

Assistant Professor of Clinical Radiology

**Nicholas Fidelman, MD**

Assistant Professor of Clinical Radiology

**Roy L. Gordon, MD**

Professor in Residence

Associate Chair, Quality Care and Patient  
Safety

**Robert K. Kerlan, Jr., MD**

Professor of Clinical Radiology and Chief

**Jeanne M. LaBerge, MD**

Professor in Residence

**Ernest Ring, MD**

Professor Emeritus

**Rajiv Sawhney, MD**

Clinical Professor

**Mark W. Wilson, MD**

Professor in Residence

**Mount Zion Medical Center**

**Philip A. Brodey, MD**

Clinical Professor

**Belinda Chang, MD**

Assistant Professor of Clinical Radiology

**Helen B. Galvin, MD**

Clinical Professor

**Bonnie N. Joe, MD, PhD**

Associate Professor in Residence

**Robert K. Kerlan, Jr., MD**

Professor of Clinical Radiology

**Steven H. Ominsky, MD**

Clinical Professor Emeritus

**Edward A. Sickles, MD**

Professor Emeritus

**Richard A. Sollitto, MD**

Clinical Professor and Chief  
Associate Chair, Radiology, Mt. Zion  
Medical Center

**Dorota Wisner, MD, PhD**

Assistant Professor in Residence

**MRI/MRS Specialized  
Resource Group**

**Nola M. Hylton, PhD**

Professor in Residence

**John Kurhanewicz, PhD**

Professor in Residence

**Sharmila Majumdar, PhD**

Professor in Residence

**Alastair J. Martin, PhD**

Adjunct Professor

**Sarah J. Nelson, PhD**

Margaret Hart Surbeck Distinguished  
Professor in Advanced Imaging

**Sabrina Ronen, PhD**

Associate Professor in Residence

**David A. Saloner, PhD**

Professor in Residence

**Daniel B. Vigneron, PhD**

Professor in Residence and Co-Director

**Michael F. Wendland, PhD**

Adjunct Professor and Co-Director

**Duan Xu, PhD**

Assistant Professor in Residence

**Xiaoliang Zhang, PhD**

Associate Professor in Residence

**Musculoskeletal and Quantitative  
Imaging Research Interest Group**

**Galatea J. Kazakia, PhD**

Assistant Professor in Residence

**Roland Krug, PhD**

Assistant Professor in Residence

**Thomas F. Lang, PhD**

Professor in Residence

**Xiaojuan Li, PhD**

Associate Adjunct Professor

**Thomas M. Link, MD, PhD**

Professor in Residence and Co-Director

**Sharmila Majumdar, PhD**

Professor in Residence and Co-Director

**David Sandman, MD**

Assistant Professor of Clinical Radiology

**Musculoskeletal Imaging**

**Thomas M. Link, MD, PhD**

Professor in Residence and Chief

**David Sandman, MD**

Assistant Professor of Clinical Radiology

**Lynne S. Steinbach, MD**

Professor of Clinical Radiology

**Neurointerventional Radiology**

**Christopher F. Dowd, MD**

Clinical Professor

**Van V. Halbach, MD**

Clinical Professor

**Steven W. Hetts, MD**

Assistant Professor in Residence

**Randall T. Higashida, MD**

Clinical Professor and Chief

## Neurodegenerative Diseases Research Interest Group

**Valerie Cardenas-Nicholson, PhD**  
Associate Adjunct Professor

**Linda Chao, PhD**  
Associate Adjunct Professor

**Timothy Durazzo, PhD**  
Assistant Adjunct Professor

**Christopher P. Hess, MD, PhD**  
Assistant Professor in Residence

**Dieter J. Meyerhoff, PhD**  
Professor in Residence

**Susanne G. Mueller, MD**  
Associate Adjunct Professor

**Norbert Schuff, PhD**  
Adjunct Professor and Co-Director

**Michael W. Weiner, MD**  
Professor in Residence and Co-Director

**Wang Zhan, PhD**  
Assistant Adjunct Professor

## Neuroradiology

**A. James Barkovich, MD**  
Professor in Residence

**Soonmee Cha, MD**  
Associate Professor In Residence

**Cynthia T. Chin, MD**  
Associate Professor of Clinical Radiology

**William P. Dillon, MD**  
Professor and Chief

**Alisa D. Gean, MD**  
Clinical Professor

**Christine Glastonbury, MD**  
Associate Professor of Clinical Radiology

**Orit A. Glenn, MD**  
Associate Professor in Residence

**Christopher P. Hess, MD, PhD**  
Assistant Professor in Residence

**Jane Kim, MD**  
Assistant Professor of Clinical Radiology

**Pratik Mukherjee, MD, PhD**  
Associate Professor in Residence

**David Norman, MD**  
Clinical Professor Emeritus

**Esther L. Yuh, MD, PhD**  
Assistant Professor in Residence

**David M. Wilson, MD, PhD**  
Assistant Professor in Residence

## Neurovascular/Neurointerventional Research Interest Group

**William P. Dillon, MD**  
Professor

**Christopher F. Dowd, MD**  
Clinical Professor

**Van V. Halbach, MD**  
Clinical Professor

**Steven W. Hetts, MD**  
Assistant Professor in Residence and  
Co-Director

**Randall T. Higashida, MD**  
Clinical Professor

**Alastair J. Martin, PhD**  
Adjunct Professor

**David A. Saloner, PhD**  
Professor in Residence and Co-Director

## Nuclear Medicine

**Elias H. Botvinick, MD**  
Professor in Residence

**Michael W. Dae, MD**  
Professor in Residence

**Randall A. Hawkins, MD, PhD**  
Professor

**Carina Mari Aparici, MD**  
Assistant Professor in Residence

**Eugene T. Morita, MD**  
Clinical Professor Emeritus

**Miguel Hernandez Pampaloni,  
MD, PhD**  
Assistant Professor in Residence and  
Chief

## Nuclear-Optical Specialized Resource Group

**Stephen Bacharach, PhD**  
Adjunct Professor

**Elias H. Botvinick, MD**  
Professor in Residence

**Michael W. Dae, MD**  
Professor in Residence

**Robert G. Gould, ScD**  
Professor in Residence

**Randall A. Hawkins, MD, PhD**  
Professor

**Jiang He, PhD**  
Assistant Adjunct Professor

**Ella Fung Jones, PhD**  
Assistant Adjunct Professor

**Carina Mari Aparici, MD**  
Assistant Professor in Residence

**Miguel Hernandez Pampaloni,  
MD, PhD**

Assistant Professor in Residence

**Henry F. VanBrocklin, PhD**  
Professor in Residence and Director

**Youngho Seo, PhD**  
Assistant Adjunct Professor

## Pediatric Radiology

**Robert C. Brasch, MD**  
Professor in Residence

**Pierre-Alain Cohen, MD**  
Clinical Professor

**Jesse Courtier, MD**  
Assistant Clinical Professor

**John MacKenzie, MD**  
Assistant Professor in Residence and  
Chief

## Pediatric/Fetal Research Interest Group

**A. James Barkovich, MD**  
Professor in Residence and Director

**Vickie A. Feldstein, MD**  
Professor of Clinical Radiology

**Orit A. Glenn, MD**  
Associate Professor in Residence

**Ruth B. Goldstein, MD**  
Professor and Chief

**Roland G. Henry, PhD**  
Professor in Residence

**Pratik Mukherjee, MD, PhD**  
Associate Professor in Residence

**Colin Studholme, PhD**  
Associate Professor in Residence

**Daniel B. Vigneron, PhD**  
Professor in Residence

**Duan Xu, PhD**  
Assistant Professor in Residence

## Prostate Cancer Research Interest Group

**Fergus V. Coakley, MD**  
Professor in Residence and Co-Director

**John Kurhanewicz, PhD**  
Professor in Residence and Co-Director



**Susan Noworolski, PhD**  
Assistant Adjunct Professor

**Aliya Qayyum, MBBS**  
Professor in Residence

**Sabrina Ronen, PhD**  
Associate Professor in Residence

**Daniel B. Vigneron, PhD**  
Professor in Residence

**Antonio C. Westphalen, MD**  
Assistant Professor in Residence

#### **San Francisco General Hospital**

**Richard S. Breiman, MD**  
Clinical Professor

**Miles Conrad, MD**  
Assistant Clinical Professor

**Pierre-Alain Cohen, MD**  
Clinical Professor

**Alisa D. Gean, MD**  
Clinical Professor

**Steven W. Hetts, MD**  
Assistant Professor in Residence

**Jane Kim, MD**  
Assistant Professor of Clinical Radiology

**Terry C.P. Lynch, MD**  
Clinical Professor

**Hideyo Minagi, MD**  
Clinical Professor Emeritus

**Sujal M. Nanavati, MD**  
Assistant Clinical Professor

**Alexander V. Rybkin, MD**  
Assistant Clinical Professor

**Mathem Saeed, PhD**  
Adjunct Professor

**Lori M. Strachowski, MD**  
Clinical Professor

**Ruedi F.-L. Thoeni, MD**  
Professor in Residence

**Thomas Urbania, MD**  
Assistant Professor of Clinical Radiology

**Thienkhai Vu, MD, PhD**  
Assistant Clinical Professor

**W. Richard Webb, MD**  
Professor Emeritus

**Mark W. Wilson, MD**  
Professor in Residence and Chief

**Esther L. Yuh, MD, PhD**  
Assistant Professor in Residence

#### **Surbeck Laboratory for Advanced Imaging**

**Robert Bok, MD, PhD**  
Assistant Adjunct Professor

**Christopher P. Hess, MD, PhD**  
Assistant Professor in Residence

**Douglas Kelley, PhD**  
Associate Adjunct Professor

**John Kurhanewicz, PhD**  
Professor in Residence

**Sharmila Majumdar, PhD**  
Professor in Residence

**Sarah J. Nelson, PhD**  
Margaret Hart Surbeck Distinguished  
Professor in Advanced Imaging and  
Director

**Sabrina M. Ronen, PhD**  
Associate Professor in Residence

**Daniel B. Vigneron, PhD**  
Professor in Residence

**Duan Xu, PhD**  
Assistant Professor in Residence

**Xiaoliang Zhang, PhD**  
Associate Professor in Residence

#### **Ultrasound**

**Seerat Aziz, MD**  
Assistant Clinical Professor

**Peter W. Callen, MD**  
Professor in Residence

**Vickie A. Feldstein, MD**  
Professor of Clinical Radiology

**Roy A. Filly, MD**  
Professor Emeritus

**Ruth B. Goldstein, MD**  
Professor and Chief

**Liina Poder, MD**  
Associate Professor of Clinical Radiology

**Rebecca Smith-Bindman, MD**  
Professor in Residence

**Lori M. Strachowski, MD**  
Clinical Professor

#### **Veterans Affairs Medical Center**

**Rizwan Aslam, MD**  
Associate Clinical Professor and Chief  
of CT

**Linda L. Chao, PhD**  
Associate Adjunct Professor

**Timothy Durazzo, PhD**  
Assistant Adjunct Professor

**Adam Jung, MD**  
Assistant Professor of Clinical Radiology

**Christine M. Glastonbury, MBBS**  
Associate Professor and Chief of  
Neuroradiology

**Virginia J. Griswold, MD**  
Associate Clinical Professor

**Carina Mari Aparici, MD**  
Assistant Professor in Residence

**Marcia J. McCowin, MD**  
Clinical Professor

**Dieter J. Meyerhoff, PhD**  
Professor in Residence

**Susanne Mueller, MD**  
Associate Adjunct Professor

**David A. Saloner, PhD**  
Professor in Residence

**Rajiv Sawhney, MD**  
Clinical Professor

**Norbert Schuff, PhD**  
Adjunct Professor

**Colin Studholme, PhD**  
Associate Professor in Residence

**Michael W. Weiner, MD**  
Professor in Residence

**Stefanie Weinstein, MD**  
Assistant Clinical Professor

**Judy Yee, MD**  
Professor in Residence and Chief

**Benjamin M. Yeh, MD**  
Associate Professor in Residence and  
Assistant Chief

**Wang Zhan, PhD**  
Assistant Adjunct Professor

#### **Women's Imaging at Mt. Zion**

**Belinda Chang, MD**  
Assistant Professor of Clinical Radiology

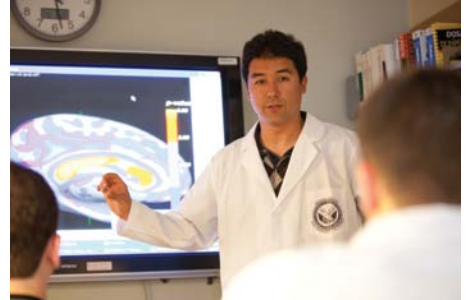
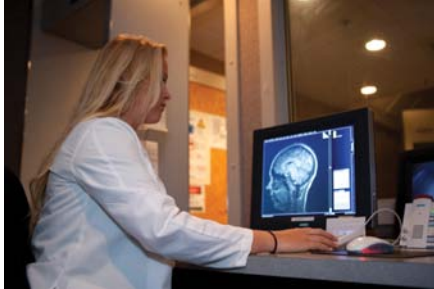**Helen B. Galvin, MD**  
Clinical Professor

**Bonnie N. Joe, MD, PhD**  
Associate Professor in Residence and  
Chief

**Edward A. Sickles, MD**  
Professor Emeritus

**Dorota Wisner, MD, PhD**  
Assistant Professor in Residence

## The Year in Pictures







## Research Directions



### ABDOMINAL IMAGING

Fergus V. Coakley, MD, Chief

#### Research Directions:

- The promotion of evidence-based abdominal imaging, including validating or debunking commonly held opinions and assumptions
- Advanced modifications of MRI and CT techniques to optimize assessment of hepatic, biliary, and renal disease
- Combined MRI and MRSI in localizing and staging prostate cancer
- Advanced hepatic imaging, including multi-detector CT, CT cholangiography, new hepatobiliary MR contrast agents, and MR cholangiopancreatography
- Radiological evaluation of diffuse liver disease, including cirrhosis, pseudocirrhosis, and nonalcoholic hepatitis
- Dynamic contrast-enhanced MRI and CT to assess solid organs and tumors in the abdomen and pelvis
- 3D rendering of CT and MR images, including projectional and volumetric applications, and CT colonography

#### Recent Key References:

Ghotb A, Noworolski SM, Madden E, Scherzer R, Qayyum A, Pannell J, Ferrell L, Peters M, Tien PC. Adipose tissue and metabolic factors associated with steatosis in HIV/HCV coinfection: histology versus magnetic resonance spectroscopy. *J Acquir Immune Defic Syndr*. 2010 Oct 1;55(2):228-231.

Jha P, Poder L, Wang ZJ, Westphalen AC, Yeh BM, Coakley FV. Radiologic mimics of cirrhosis. *AJR Am J Roentgenol*. 2010 Apr;194(4):993-9.

Stengel JW, Webb EM, Poder L, Yeh BM, Smith-Bindman R, Coakley FV. Acute appendicitis: clinical outcome in patients with an initial false-positive CT diagnosis. *Radiology*. 2010 Jul;256(1):119-26.

Wang ZJ, Webb EM, Westphalen AC, Coakley FV, Yeh BM. Multi-detector row computed tomographic appearance of celiac ganglia. *J Comput Assist Tomogr*. 2010 May-Jun;34(3):343-7.

Westphalen AC, Coakley FV, Roach M 3rd, McCulloch CE, Kurhanewicz J. Locally recurrent prostate cancer after external beam radiation therapy: diagnostic performance of 1.5-T endorectal MR imaging and MR spectroscopic imaging for detection. *Radiology*. 2010 Aug;256(2):485-92.

### BRAIN BEHAVIOR RESEARCH INTEREST GROUP

Srikantan Nagarajan, PhD, Co-Director

Pratik Mukherjee, MD, PhD, Co-Director

#### Research Directions:

The vision of the Brain-Behavior RIG is to:

- Understand the relationship between brain and behavior in health and disease
- Integrate information from molecules to mind
- Translate neuroimaging advances to the clinic

Our specific mission is to:

- Map and analyze functional activation in the brain
- Map and analyze structural and functional network connectivity in the brain
- Identify neurophysiological and neuroanatomical correlates of behavior in health and disease

Specific projects involve:

- Understanding the neural bases of sensory and motor function, speech, language, learning, memory, attention, executive function, and social cognition as measured by brain structure, function, and connectivity in the healthy and in a variety of diseases
- Developing biological, brain-based markers for diagnosis, monitoring disease progression, and response to therapies





- Developing and disseminating powerful, state-of-the-art computational tools and resources for multimodal structural and functional brain imaging
- Developing novel brain-based therapies

Our activities involve these specific populations:

- Healthy young adults, normally developing children, and normal aging adults
- Patients with:
  - Epilepsy
  - Traumatic brain injury
  - NeuroENT (tinnitus, spasmodic dysphonia)
  - Neuropsychiatric illnesses (schizophrenia, depression, PTSD, lupus, Gulf War Syndrome)
  - Multiple sclerosis, movement disorders (Parkinson's disease, focal hand dystonia), prion diseases (CJD)
  - Neurodevelopmental disorders (autism, agenesis of the corpus callosum, cerebral palsy)
  - Neurodegenerative diseases (Alzheimer/MCI, FTD, ALS, semantic dementia, PPA)
  - Brain tumors
  - Cerebrovascular disease (stroke, AVM, sickle cell disease)

#### Recent Key References:

Dale CL, Findlay AM, Adcock RA, Vertinski M, Fisher M, Genevsky A, Aldebot S, Subramaniam K, Luks TL, Simpson GV, Nagarajan SS, Vinogradov S. Timing is everything: neural response dynamics during syllable processing and its relation to higher-order cognition in schizophrenia and healthy comparison subjects. *Int J Psychophysiol*. 2010 Feb;75(2):183-93.

Edwards E, Nagarajan SS, Dalal SS, Canolty RT, Kirsch HE, Barbaro NM, Knight RT. Spatiotemporal imaging of cortical activation during verb generation and picture naming. *Neuroimage*. 2010 Mar;50(1):291-301.

Haacke EM, Duhaime AC, Gean AD, Riedy G, Wintermark M, Mukherjee P, Brody DL, DeGraba T, Duncan TD, Elovic E, Hurley R, Latour L, Smirniotopoulos JG, Smith DH. Common data elements in radiologic imaging of traumatic brain injury. *J Magn Reson Imaging*. 2010 Sep;32(3):516-43.

Wipf DP, Owen JP, Attias HT, Sekihara K, Nagarajan SS. Robust Bayesian estimation of the location, orientation, and time course of multiple correlated neural sources using MEG. *Neuroimage*. 2010 Jan 1;49(1):641-55.

Zumer JM, Nagarajan SS, Krubitzer LA, Zhu Z, Turner RS, Disbrow EA. MEG in the macaque monkey and human: Distinguishing cortical fields in space and time. *Brain Res*. 2010 Jul 23;1345:110-24.



#### BRAIN CANCER RESEARCH INTEREST GROUP

Soonmee Cha, MD, Co-Director

Sarah J. Nelson, PhD, Co-Director

#### Research Directions:

Evaluating patients with brain tumors is a major focus for imaging research at UCSF and is an important application for the development of novel MR imaging and spectroscopy techniques. This research is performed in close collaboration with the Brain Tumor Research Center, which includes a broad array of basic scientists and clinical researchers engaged in multi-disciplinary, translational research studies with a common disease focus. The researchers in the brain tumor RIG have substantial NIH and other agency grant funding to support their work. Key methodologies being applied to understand the underlying mechanisms of response to therapy and to validate *in vivo* parameters include the *ex vivo* analysis of image-guided tissue samples and the use of NMR spectroscopy in cell and pre-clinical model systems. *In vivo* imaging methodologies under consideration include these mechanisms for probing anatomic, vascular, structural, and metabolic properties of brain tumors:

- Applying T2-weighted magnitude and phase images acquired with 3T and 7T whole body scanners for visualizing heterogeneity in the region of T2 hyperintensity caused by local changes in susceptibility due to hemorrhage and other treatment effects
- Measuring changes in vascular properties using arterial-spin labeling, dynamic contrast-enhanced and perfusion-weighted imaging for patients receiving anti-angiogenic therapies
- Assessing the changes in diffusion tensor imaging for mapping connectivity by applying tractography to visualize the disruption in normal tissue structure caused by the tumor, and in the pre-operative analysis of the patient for surgical planning purposes
- Evaluating metabolically abnormal, non-enhancing tumor to quantify disease burden, plan treatment, and assess treatment response using 1H MRSI and hyperpolarized C-13 metabolic imaging

- Identifying parameters that contribute to the characterization of lesions which are non-enhancing on post-Gadolinium T1-weighted images to assess tumor burden and select the most appropriate treatments
- Correlating non-invasive imaging parameters with the genetic and molecular properties of tumors to identify lesions that are likely to have a poor outcome and to tailor therapy to individual patients
- Investigating the metabolic profile of primary/recurrent tumor with *ex vivo* HRMAS of image-guided biopsies to identify disease pathways that are affected and could be targeted for therapeutic intervention
- Developing new surrogate metabolic markers of disease progression based on association of *ex vivo* and *in vivo* metabolic profiles and imaging data

## Recent Key References:

Cha S. Brain Tumor Imaging: Pretherapy. Special Collections. *AJNR Amer J Neuroradiol* 2010

Barajas RF Jr, Chang JS, Segal MR, Parsa AT, McDermott MW, Berger MS, Cha S. Differentiation of recurrent glioblastoma multiforme from radiation necrosis after external beam radiation therapy with dynamic susceptibility-weighted contrast-enhanced perfusion MR imaging. *Radiology*. 2009 Nov;253(2):486-96.

Barajas RF Jr, Hodgson JG, Chang JS, Vandenberg SR, Yeh RF, Parsa AT, McDermott MW, Berger MS, Dillon WP, Cha S. Glioblastoma multiforme regional genetic and cellular expression patterns: influence on anatomic and physiologic MR imaging. *Radiology*. 2010 Feb;254(2):564-76.

Bian W, Khayal IS, Lupo JM, McGue C, Vandenberg S, Lamborn KR, Chang SM, Cha S, Nelson SJ. Multiparametric characterization of grade 2 glioma subtypes using magnetic resonance spectroscopic, perfusion, and diffusion imaging. *Transl Oncol*. 2009 Dec;2(4):271-80.

Khayal IS, Polley MY, Jalbert L, Elkhaled A, Chang SM, Cha S, Butowski NA, Nelson SJ. Evaluation of diffusion parameters as early biomarkers of disease progression in glioblastoma multiforme. *Neuro Oncol*. 2010 Sep;12(9):908-16.

Park I, Larson PE, Zierhut ML, Hu S, Bok R, Ozawa T, Kurhanewicz J, Vigneron DB, Vandenberg SR, James CD, Nelson SJ. Hyperpolarized <sup>13</sup>C magnetic resonance metabolic imaging: application to brain tumors. *Neuro Oncol*. 2010 Feb;12(2):133-44. Epub 2010 Jan 25.

Srinivasan R, Phillips JJ, Vandenberg SR, Polley MY, Bourne G, Au A, Pirzkall A, Cha S, Chang SM, Nelson SJ. *Ex vivo* MR spectroscopic measure differentiates tumor from treatment effects in GBM. *Neuro Oncol*. 2010 Jul 20. [Epub ahead of print]



## BREAST CANCER RESEARCH INTEREST GROUP

Nola Hylton, PhD, Co-Director

Bonnie N. Joe, MD, Co-Director

## Research Directions:

The Breast RIG's research aims are to advance imaging-based approaches for breast cancer diagnosis, leading to earlier detection, reduction of disease recurrence, and improved survival. Our major research areas include:

- MRI and spectroscopy to assess breast tumor response to neo-adjuvant chemotherapy. UCSF is the lead institution for the national ACRIN 6657/I-SPY breast cancer clinical trial testing MRI and molecular biomarkers to predict treatment response and survival for women receiving neoadjuvant chemotherapy for locally advanced breast cancer.
- Computer-aided tools for real-time measurement of MRI biomarkers for breast cancer
- MRI of ductal carcinoma in situ for staging and assessing response to hormonal treatment
- Quantitative mammographic breast density measurement for breast cancer risk assessment
- MRI-directed tissue biopsy for radiologic-pathologic correlation of imaging and molecular biomarkers
- MRI measurement of breast density and tissue composition

## Recent Key References:

Aliu SO, Wilmes LJ, Moasser MM, Hann BC, Li KL, Wang D, Hylton NM. MRI methods for evaluating the effects of tyrosine kinase inhibitor administration used to enhance chemotherapy efficiency in a breast tumor xenograft model. *J Magn Reson Imaging* 2009;29:1071-9.

Chang CB, Lvoff NM, Leung JW, Brenner RJ, Joe BN, Tso HH, Sickles EA. Solitary dilated duct identified at mammography: outcomes analysis. *AJR Am J Roentgenol*. 2010 Feb;194(2):378-82.

Dorgan JF, Liu L, Klifa C, Hylton N, Shepherd JA, Stanczyk FZ, Snetselaar LG, Van Horn L, Stevens VJ, Robson A, Kwitrovich PO Jr, Lasser NL, Himes JH, Pettie Gabriel K, Kriska A, Ruder

EH, Fang CY, Barton BA. Adolescent diet and subsequent serum hormones, breast density, and bone mineral density in young women: results of the Dietary Intervention Study in Children follow-up study. *Cancer Epidemiol Biomarkers Prev*. 2010 Jun;19(6):1545-56.

Garwood ER, Kumar AS, Baehner FL, Moore DH, Au A, Hylton N, Flowers CI, Garber, J, Lesnikowski BA, Hwang ES, Olopade O, Port ER, Campbell M, Esserman LJ. Fluvastatin reduces proliferation and increases apoptosis in women with high grade breast cancer. *Breast Cancer Res Treat*. 2010 Jan;119(1):137-44.

Klifa C, Carballido-Gamio J, Wilmes L, Laprie A, Shepherd J, Gibbs J, Fan B, Noworolski S, Hylton N. Magnetic resonance imaging for secondary assessment of breast density in a high-risk cohort. *Magn Reson Imaging*. 2010 Jan;28(1):8-15.

Laidevant AD, Malkov S, Flowers CI, Kerlikowske K, Shepherd JA. Compositional breast imaging using a dual-energy mammography protocol. *Med Phys*. 2010 Jan;37(1):164-74.

Wang SC, Joe BN, Esserman LJ. Magnetic resonance imaging is more accurate than mammography for assessing response to neoadjuvant chemotherapy in a breast cancer patient with significant calcifications. *Reports in Medical Imaging*, April, 2009 Volume 2009(2):35-40.



## CARDIAC AND PULMONARY IMAGING

Brett M. Elicker, MD, Chief

### Research Directions:

- Cardiac CT angiography
  - CTA assessment of coronary allograft vasculopathy after heart transplantation
  - Use of cardiac CTA for pre-surgical clearance
  - Use of cardiac CTA for definitive emergency room evaluation of atypical chest pain
  - Evaluation of coronary atherosclerosis in patients with HIV infection
- Cardiac CT
  - Evaluation of pulmonary venous anatomy in atrial fibrillation

- Characterization of myocardial ischemic injury by contrast-enhanced MRI and CT

### ■ High-resolution CT

- High-resolution CT diagnosis of lung disease
- Clinical outcomes following negative CT for acute pulmonary embolism
- Predictors of poor outcome in patients with acute PE diagnosed by helical CT

### ■ Cardiac MRI

- Use of novel cardiac MRI techniques and computational modeling for the quantitative assessment of ventricular performance in congenital heart disease
- Use of multidimensional flow techniques for quantitative assessment of flow dynamics in congenital heart disease
- MRI to assess cardiac function after repair of tetralogy of Fallot; correlation with clinical outcomes
- MRI to assess cardiac function in the single ventricle patient after Fontan palliation; correlation with clinical outcomes
- Endovascular therapy and hemodynamic assessment using MRI guidance

### Recent Key References:

Cannavale A, Ordovas KG, Higgins CB. Magnetic Resonance Imaging of Hypertrophic Cardiomyopathy. *J Thorac Imaging*. 2010 Sep 4. [Epub ahead of print]

Chung JH, Mitsumori LM, Ordovas KG, Elicker BM, Higgins CB, Reddy GP. Heart as a Source of Stroke: Imaging Evaluation With Computed Tomography. *J Thorac Imaging*. 2010 Aug 31. [Epub ahead of print]

Elicker BM, Golden JA, Ordovas KG, Leard L, Golden TR, Hays SR. Progression of native lung fibrosis in lung transplant recipients with idiopathic pulmonary fibrosis. *Respir Med*. 2010 Mar;104(3):426-33.

Elicker BM, Schwartz BS, Liu C, Chen EC, Miller SA, Chiu CY, Webb WR. Thoracic CT findings of novel influenza A (H1N1) infection in immunocompromised patients. *Emerg Radiol*. 2010 Jul;17(4):299-307. Epub 2010 Jan 29.

Hope MD, Hope TA, Meadows AK, Ordovas KG, Urbania TH, Alley MT, Higgins CB. Bicuspid aortic valve: four-dimensional MR evaluation of ascending aortic systolic flow patterns. *Radiology*. 2010 Apr;255(1):53-61.

Hope MD, Meadows AK, Hope TA, Ordovas KG, Saloner D, Reddy GP, Alley MT, Higgins CB. Clinical evaluation of aortic coarctation with 4D flow MR imaging. *J Magn Reson Imaging*. 2010 Mar;31(3):711-8.

## INFORMATICS AND IMAGE PROCESSING/DISPLAY SPECIALIZED RESOURCE GROUP


David E. Avrin, MD, PhD, Director

### Research and Development Directions:

Our SRG demonstrated realized success on multiple fronts and demonstrated new initiatives this year in both informatics infrastructure and image processing and analysis.

- **RSNA Image Sharing Initiative:** As expected, RSNA finalized the contract for this exciting project to replace the physical CD of imaging studies, and UCSF is one of the five development sites. Our role is to define the overall architecture of this complex project, and the hard work is being done by Wyatt Tellis, PhD, with oversight from Arenson and Avrin. A working version will be demonstrated at RSNA in November. A key portion of this project is patient control of the electronic transport of their imaging studies from one institution or provider to another. This project is a significant piece of the national effort towards HER (Electronic Health Records) and portability of patient data.
- **Research PACS and Quantitative Imaging:** Under the direction of Tuhin Sinha, PhD, the infrastructure for research PACS consisting of multiple “instances,” one for each defined research project, has been successfully created. Sinha also created workflow tools for image-centric research, as well as a recharge mechanism. We are hoping to create and host a research PACS Core for the entire institution. Capabilities include anonymization for HIPAA and CHR compliance. On a related front, Sinha has assumed responsibility for the Quantitative Image Processing Center (QUIP-C) and extended beyond 3D to include diffusion and other types of derived image data for clinical as well as research purposes.
- **Image Processing:** Colin Studholme, PhD, and Valerie Cardenas-Nicolson, PhD, continue their sophisticated voxel-wise analysis of image data. Dr. Studholme’s focus is on mapping to an anatomic model in the presence of motion, for fetal MR and neonatal brain MR. Cardenas-Nicolson focuses on multi-dimensional and multi-modality modeling and analysis for neurodegeneration.
- **Report Mining:** Dr. Tellis has developed a beta version of new tool to rapidly perform Natural Language Processing (NLP) text searches of our report stream for retrospective clinical research and education. Early feedback from select members of the department has been overwhelmingly positive. This effort complements other significant advances in the department data mining capabilities for the operational side.
- **New Projects:** Avrin and Arenson recently submitted a \$2 million proposal to CMS for their MID project to determine if Decision Support Systems (DSS) for Radiology Order Entry

(ROE) could decrease the number of unnecessary MR and CT studies ordered on Medicare beneficiaries. This was submitted in conjunction with the leadership of the medical staff, in keeping with UCSF efforts to practice evidence-based imaging.



## INTERVENTIONAL RADIOLOGY

Robert K. Kerlan, Jr., MD, Chief

### Research Directions:

- Joint project with Transplant Service for implantation of pancreatic islet cells
- Joint project with Transplant Service for downstaging hepatocellular carcinoma in potential transplant candidates
- Joint project with Abdominal Imaging in using MR diffusion imaging to differentiate flow abnormalities from hepatocellular carcinoma
- Joint project with Pediatric Surgery to create gastrojejunostomies and percutaneous jejunostomies using magnets
- Assessing the role of interventional radiology in managing complications related to the creation of ileal pouches following proctectomy
- Use of expandable metallic stents in the airways
- Joint project with Urology on RF ablation of small renal masses
- Assessing the safety of transdiaphragmatic drainages

### Recent Key References:

Bhagat N, Fidelman N, Durack JC, Collins J, Gordon RL, Laberge JM, Kerlan RK Jr. Complications Associated with the Percutaneous Insertion of Fiducial Markers in the Thorax. *Cardiovasc Intervent Radiol*. 2010 Jul 27 [Epub ahead of print]

Kerlan RK Jr, LaBerge JM. Fistula first, stent graft second. *N Engl J Med*. 2010 Feb 11;362(6):550-2.

Mission JF, Kerlan RK Jr, Tan JH, Fang MC. Rates and predictors of plans for inferior vena cava filter retrieval in hospitalized patients. *J Gen Intern Med*. 2010 Apr;25(4):321-5.

Roberts JP, Venook A, Kerlan R, Yao F. Hepatocellular carcinoma: Ablate and wait versus rapid transplantation. *Liver Transpl*. 2010 Aug;16(8):925-9.





## MARGARET HART SURBECK LABORATORY OF ADVANCED IMAGING

Sarah J. Nelson, PhD, Director

Daniel B. Vigneron, PhD, Associate Director

### Research Directions:

Development of high-field, 3T and 7T MR techniques with improved sensitivity and specificity that more effectively address fundamental problems in biology and medicine, most notably:

- New algorithms for reconstructing spatial and temporal responses of biological systems and quantifying the resultant multi-dimensional and multi-spectral images
- New strategies for designing high-frequency RF coils and coil arrays that address electromagnetic problems and computational electromagnetism in *in vivo* MR at high fields using the FDTD and other finite element methods
- Applications of novel RF coil designs for *in vivo* MRI and spectroscopy
- Implementing parallel imaging strategies for anatomic, vascular, and spectroscopic imaging sequences in the musculoskeletal system, prostate, and brain
- Dynamic contrast-enhanced and perfusion-weighted imaging
- Phase and susceptibility-weighted imaging
- High-resolution angiography of neurovascular disease
- Developing faster, more reliable methods to acquire and process diffusion MRI
- Integrating studies on the human scanners with *ex vivo* analyses of tissue samples using high-resolution magic angle spinning NMR spectroscopy
- Improving and translating 3T MR spectroscopy sequences for prostate and brain in routine clinical use
- Applying and developing high-resolution MRI, MR spectroscopy, and MR diffusion imaging techniques at 7T
- Developing hyperpolarized C-13 agents and integrating novel

data acquisition and analysis procedures

- Applying hyperpolarized C-13 metabolic imaging in cell systems and pre-clinical models to evaluate cancer and other diseases
- Developing new methods for hyperpolarized C-13 metabolic imaging in patients

Scientists in the Surbeck Lab continue to develop hands-on educational programs in high-field MR that are available to undergraduate and graduate students, medical students, and research fellows.

### Recent Key References:

Hu S, Lustig M, Balakrishnan A, Larson PE, Bok R, Kurhanewicz J, Nelson SJ, Goga A, Pauly JM, Vigneron DB. 3D compressed sensing for highly accelerated hyperpolarized (13)C MRSI with *in vivo* applications to transgenic mouse models of cancer. *Magn Reson Med*. 2010 Feb;63(2):312-21.

Larson PE, Bok R, Kerr AB, Lustig M, Hu S, Chen AP, Nelson SJ, Pauly JM, Kurhanewicz J, Vigneron DB. Investigation of tumor hyperpolarized [1-13C]-pyruvate dynamics using time-resolved multiband RF excitation echo-planar MRSI. *Magn Reson Med*. 2010 Mar;63(3):582-91.

Park I, Larson PE, Zierhut ML, Hu S, Bok R, Ozawa T, Kurhanewicz J, Vigneron DB, Vandenberg SR, James CD, Nelson SJ. Hyperpolarized 13C magnetic resonance metabolic imaging: application to brain tumors. *Neuro Oncol*. 2010 Feb;12(2):133-44.

Ward CS, Venkatesh HS, Chaumeil MM, Brandes AH, Vancracking M, Dafni H, Sukumar S, Nelson SJ, Vigneron DB, Kurhanewicz J, James CD, Haas-Kogan DA, Ronen SM. Noninvasive detection of target modulation following phosphatidylinositol 3-kinase inhibition using hyperpolarized 13C magnetic resonance spectroscopy. *Cancer Res*. 2010 Feb 15;70(4):1296-305.

Wilson DM, Keshari KR, Larson PE, Chen AP, Hu S, Van Crielinge M, Bok R, Nelson SJ, Macdonald JM, Vigneron DB, Kurhanewicz J. Multi-compound polarization by DNP allows simultaneous assessment of multiple enzymatic activities *in vivo*. *J Magn Reson*. 2010 Jul;205(1):141-7.

Xu D, Lee MC, Carballido-Gamio J, Barkovich M, Majumdar S, Vigneron DB, Nelson SJ. Quantitative analysis of spatial distortions of diffusion techniques at 3T. *Magn Reson Imaging*. 2010 Apr;28(3):451-4.

Zierhut ML, Yen YF, Chen AP, Bok R, Albers MJ, Zhang V, Tropp J, Park I, Vigneron DB, Kurhanewicz J, Hurd RE, Nelson SJ. Kinetic modeling of hyperpolarized  $^{13}\text{C}$ -pyruvate metabolism in normal rats and TRAMP mice. *J Magn Reson*. 2010 Jan;202(1):85-92.



## MRI/MRS SPECIALIZED RESOURCE GROUP

Daniel Vigneron, PhD, Director

### Research Directions:

The MRI/MRS SRG works to advance MR imaging science to benefit the study of human disease. Studies include developing hardware and techniques to improve MR anatomic, diffusion, spectroscopic, hyperpolarized, perfusion, and high-field 3T and 7T imaging. We look at everything from developing new techniques and translating existing techniques, to improving the quality, speed, information content, and applicability of advanced MR methods. This graphic depicts our approach:

Basic development=>Translation=>Optimization=> Validation

Our key missions are to:

- Be world leaders in cutting-edge MR techniques for studying human disease
- Collaborate with RIGS to translate basic science MR techniques into application studies for testing and optimization
- Work with clinical MRI to optimize and evaluate new techniques and improve state-of-the-art methods
- Train and educate all personnel in advanced MR techniques

### Recent Key References:

Hu S, Lustig M, Balakrishnan A, Larson PE, Bok R, Kurhanewicz J, Nelson SJ, Goga A, Pauly JM, Vigneron DB. 3D compressed

sensing for highly accelerated hyperpolarized  $^{13}\text{C}$  MRSI with in vivo applications to transgenic mouse models of cancer. *Magn Reson Med*. 2010 Feb; 63(2):312-321.

Keshari KR, Kurhanewicz J, Jeffries RE, Wilson DM, Dewar BJ, Van Crielinge M, Zierhut M, Vigneron DB, Macdonald JM. Hyperpolarized  $^{13}\text{C}$  Spectroscopy And An NMR-Compatible Bioreactor System For The Investigation Of Real-Time Cellular Metabolism. *Magn. Reson. Med*. 2010 Feb; 63(2):322-329.

Larson PE, Bok R, Kerr AB, Lustig M, Hu S, Chen AP, Nelson SJ, Pauly JM, Kurhanewicz J, Vigneron DB. Investigation of tumor hyperpolarized  $[^{13}\text{C}]$ -pyruvate dynamics using time-resolved multiband RF excitation echo-planar MRSI. *Magn Reson Med*. 2010 Mar; 63(3):582-91.

Lupo JM, Chen AP, Zierhut ML, Bok RA, Cunningham CC, Kurhanewicz J, Vigneron DB, Nelson SJ. Analysis of hyperpolarized dynamic  $^{13}\text{C}$  lactate imaging in a transgenic mouse model of prostate cancer. *Magn Reson Imaging*. 2010 Feb; 28(2):153-62.

Wilson DM, Keshari KR, Larson PE, Chen AP, Hu S, Crielinge MV, Bok R, Nelson SJ, Macdonald JM, Vigneron DB, Kurhanewicz J. Multi-compound polarization by DNP allows simultaneous assessment of multiple enzymatic activities *in vivo*. *J Magn Reson*. 2010 Jul; 205(1):141-147.

Wu B, Wang C, Kelley D, Xu D, Vigneron D, Nelson S, Zhang X. Shielded Microrstrip Array at 7T. *IEEE Trans Medical Imaging* 2010 Jan; 29(1):179-84.

## MUSCULOSKELETAL AND QUANTITATIVE IMAGING RESEARCH INTEREST GROUP

Sharmila Majumdar, PhD, Co-Director

Thomas M. Link, MD, PhD, Co-Director

### Research Directions:

- High-field and high-resolution MRI for quantitative characterization of the morphology and function of the musculoskeletal system
- Identification of biomarkers for degeneration in bone, cartilage, and inter-vertebral disc, and diseases such as osteoporosis, spinal disorders, and osteoarthritis
- MR spectroscopy methods for characterizing muscle in diabetes, HIV disease, and other diseases
- Strategies for non-invasive monitoring of cartilage and disc regeneration
- Microscopic characterization of bone, cartilage, disc, and other tissues, using methodologies such as computed tomography, Fourier Transform Infra-red imaging, high-resolution NMR spectroscopy, and confocal laser microscopy
- Development of high-resolution, and quantitative-computed tomography for characterizing bone geometry, micro-archi-

texture, and density aimed at understanding aging, ethnic differences in the skeleton, osteoporosis, metal artifact reduction, and orthopedic implants



#### Recent Key References:

Blumenkrantz G, Zuo J, Li X, Kornak J, Link TM, Majumdar S. In vivo 3.0-tesla magnetic resonance T1rho and T2 relaxation mapping in subjects with intervertebral disc degeneration and clinical symptoms. *Magn Reson Med*. 2010 May;63(5):1193-200.

Burghardt AJ, Issever AS, Schwartz AV, Davis KA, Masharani U, Majumdar S, Link TM. High-resolution peripheral quantitative computed tomographic imaging of cortical and trabecular bone microarchitecture in patients with type 2 diabetes mellitus. *J Clin Endocrinol Metab*. 2010 Aug 18 [Epub ahead of print].

Burghardt AJ, Kazakia GJ, Sode M, de Papp AE, Link TM, Majumdar S. A longitudinal HR-pQCT study of alendronate treatment in post-menopausal women with low bone density: Relations between density, cortical and trabecular micro-architecture, biomechanics, and bone turnover. *J Bone Miner Res*. 2010 Jun 18. [Epub ahead of print].

Kiel DP, Hannan MT, Barton BA, Bouxsein ML, Lang TF, Brown KM, Shane E, Magaziner J, Zimmerman S, Rubin CT. Insights from the conduct of a device trial in older persons: low magnitude mechanical stimulation for musculoskeletal health. *Clin Trials*. 2010;7(4):354-67.

Luke AC, Stehling C, Stahl R, Li X, Kay T, Takemoto S, Ma B, Majumdar S, Link T. High-field magnetic resonance imaging assessment of articular cartilage before and after marathon running: does long-distance running lead to cartilage damage? *Am J Sports Med*. 2010 Jul 14. [Epub ahead of print].


Schafer AL, Vittinghoff E, Lang TF, Sellmeyer DE, Harris TB, Kanaya AM, Strotmeyer ES, Cawthon PM, Cummings SR, Tyllavsky FA, Scherzinger AL, Schwartz AV; for the Health, Aging, and Body Composition (Health ABC) Study. Fat Infiltration of

Muscle, Diabetes, and Clinical Fracture Risk in Older Adults. *J Clin Endocrinol Metab*. 2010 Jul 28. [Epub ahead of print].

Stehling C, Lane NE, Nevitt MC, Lynch J, McCulloch CE, Link TM. Subjects with higher physical activity levels have more severe focal knee lesions diagnosed with 3T MRI: analysis of a non-symptomatic cohort of the osteoarthritis initiative. *Osteoarthritis Cartilage*. 2010 Jun;18(6):776-86.

Stehling C, Liebl H, Krug R, Lane NE, Nevitt MC, Lynch J, McCulloch CE, Link TM. Patellar cartilage: T2 values and morphologic abnormalities at 3.0-T MR imaging in relation to physical activity in asymptomatic subjects from the osteoarthritis initiative. *Radiology*. 2010 Feb;254(2):509-20.

Zarins ZA, Bolbos RI, Pialat JB, Link TM, Li X, Souza RB, Majumdar S. Cartilage and meniscus assessment using T1rho and T2 measurements in healthy subjects and patients with osteoarthritis. *Osteoarthritis Cartilage*. 2010 Aug 7. [Epub ahead of print].



#### MUSCULOSKELETAL RADIOLOGY

Thomas M. Link, MD, PhD, Chief

#### Research Directions:

Bone Marrow Imaging

- Monitoring the progress of the treatment of Gauchers disease

Cartilage and Osteoarthritis MR Imaging

- Imaging osteoarthritis-related changes in the Osteoarthritis Initiative cohorts
- Osteoarthritis, obesity, and physical activity
- Cartilage imaging of marathoners and physically active people
- Optimizing MR protocols for the knee at 3T and 7T
- Assessing menisci and cartilage with matrix-sensitive MRI sequences

High-field MRI for musculoskeletal applications

- *In vitro* and *in vivo* comparison of cartilage imaging at 1.5T, 3T, and 7T
- Comparing 1.5T with 3T MRI for the evaluation of smaller joints and the spine



## Imaging of the Knee

- ACL grafts and popliteomeniscal fascicle tears with arthroscopic correlation

## Imaging of the Shoulder

- Optimizing MRI for visualizing metal-on-metal surface replacements
- Evaluating fatty infiltration of muscles of the rotator cuff

## MR Arthrography

- Evaluating the complications of MR arthrography

## Osteoporosis Imaging

- Evaluating insufficiency fractures of the pelvis, CT vs. MRI
- Contrast-enhanced, multi-slice-spiral CT for assessing bone density and structure
- Diabetic bone disease and bone structure
- CT and radiograph-based trabecular bone structure measures to predict implant failure in patients undergoing internal fixation of proximal femur fractures

## New MRI Techniques

- Use of CUBE and IDEAL sequences at 3T to image the knee
- Application of MAVRIC sequence for metal suppression
- MR neurography

## Recent Key References:

Burghardt AJ, Issever AS, Schwartz AV, Davis KA, Masharani U, Majumdar S, Link TM. High-Resolution Peripheral Quantitative Computed Tomographic Imaging of Cortical and Trabecular Bone Microarchitecture in Patients with Type 2 Diabetes Mellitus. *J Clin Endocrinol Metab*. 2010 Aug 18. [Epub ahead of print]

Giaconci JC, Allen CR, Steinbach LS. Anterior cruciate ligament graft reconstruction: clinical, technical, and imaging overview. *Top Magn Reson Imaging*. 2009 Jun;20(3):129-50.

Luke AC, Stehling C, Stahl R, Li X, Kay T, Takemoto S, Ma B, Majumdar S, Link T. High-Field Magnetic Resonance Imaging Assessment of Articular Cartilage Before and After Marathon Running: Does Long-Distance Running Lead to Cartilage Damage? *Am J Sports Med*. 2010 Jul 14. [Epub ahead of print]

Ristow O, Stehling C, Krug R, Steinbach L, Sabo G, Ambekar A, Huber M, Link TM. Isotropic 3-dimensional fast spin echo imaging versus standard 2-dimensional imaging at 3.0 T of the knee: artificial cartilage and meniscal lesions in a porcine model. *J Comput Assist Tomogr*. 2010 Mar-Apr;34(2):260-9.

Stehling C, Liebl H, Krug R, Lane NE, Nevitt MC, Lynch J, McCulloch CE, Link TM. Patellar cartilage: T2 values and morphologic abnormalities at 3.0-T MR imaging in relation to physical activity in asymptomatic subjects from the osteoarthritis initiative. *Radiology*. 2010 Feb;254(2):509-20.

Steinbach L. Magnetic resonance imaging of the lower extremity. *Top Magn Reson Imaging*. 2009 Jun;20(3):121.

Tham SC, Horvai AE, Link T, Steinbach L. Soft tissue mass at the infrascapular fossa. *Skeletal Radiol*. 2010 Apr 15. [Epub ahead of print]

## NEURODEGENERATIVE DISEASES RESEARCH INTEREST GROUP

Norbert Schuff, PhD, Co-Director

Michael Weiner, MD, Co-Director

## Research Directions:

- Studying the causes and effects of neurodegenerative and psychiatric disorders, using MRI as a surrogate marker
- Developing powerful, new brain MR techniques for early detection, improved diagnosis, and assessment of therapeutic interventions of neurodegenerative and psychiatric disorders
- Developing multimodal brain image processing and imaging statistical analysis techniques
- Highlights include:
  - Ultra-high resolution structural MRI
  - Diffusion spectrum imaging
  - Dynamic, arterial-spin-labeling imaging
  - Susceptibility-weighted imaging
  - Spectroscopic imaging and j-modulated spectroscopy
  - Bayesian image reconstruction
  - Multivariate image analysis methods
  - Standards for imaging neurodegenerative diseases that can be transferred into clinical practice and multi-center clinical trials

## Recent Key References:

Chao LL, Rothlind JC, Cardenas VA, Meyerhoff DJ, Weiner MW. Effects of low-level exposure to sarin and cyclosarin during the 1991 Gulf War on brain function and brain structure in US veterans. *Neurotoxicology*. 2010 Sep; 31: 493-501, 2010.

Durazzo TC, Gazdzinski S, Mon A, Meyerhoff DJ. Cortical perfusion in alcohol-dependent individuals during short-term abstinence: relationships to resumption of hazardous drinking after treatment. *Alcohol*. 2010 May;44(3):201-10.

Mueller SG, Schuff N, Yaffe K, Madison C, Miller B, Weiner MW. Hippocampal atrophy patterns in mild cognitive impairment and Alzheimer's disease. *Hum Brain Mapp*. 2010 Sep;31(9):1339-47.

Schuff N, Zhang Y, Zhan W, Lenoci M, Ching C, Boreta L, Mueller SG, Wang Z, Marmar CR, Weiner MW, Neylan TC. Patterns of altered cortical perfusion and diminished subcortical integrity in posttraumatic stress disorder: An MRI study. *Neuroimage*. 2010 May 17. [Epub ahead of print]



Tosun D, Schuff N, Truran-Sacrey D, Shaw LM, Trojanowski JQ, Aisen P, Peterson R, Weiner MW; Alzheimer's Disease Neuroimaging Initiative. Relations between brain tissue loss, CSF biomarkers, and the ApoE genetic profile: a longitudinal MRI study. *Neurobiol Aging*. 2010 Aug;31(8):1340-54.

Tosun D, Mojabi P, Weiner MW, Schuff N. Joint analysis of structural and perfusion MRI for cognitive assessment and classification of Alzheimer's disease and normal aging. *Neuroimage*. 2010 Aug 1;52(1):186-97.

Vichinsky EP, Neumayr LD, Gold JI, Weiner MW, Rule RR, Truran D, Kasten J, Eggleston B, Kesler K, McMahon L, Orringer EP, Harrington T, Kalinyak K, De Castro LM, Kutlar A, Rutherford CJ, Johnson C, Bessman JD, Jordan LB, Armstrong FD, Neuropsychological Dysfunction and Neuroimaging Adult Sickle Cell Anemia Study Group. Neuropsychological dysfunction and neuroimaging abnormalities in neurologically intact adults with sickle cell anemia. *JAMA*. 2010 May 12; 303(18):1823-31, 2010.

Weiner MW, Aisen PS, Jack CR Jr, Jagust WJ, Trojanowski JQ, Shaw L, Saykin AJ, Morris JC, Cairns N, Beckett LA, Toga A, Green R, Walter S, Soares H, Snyder P, Siemers E, Potter W, Cole PE, Alzheimer's Disease Neuroimaging Initiative. The Alzheimer's Disease Neuroimaging Initiative: progress report and future plans. *Alzheimer's & Dementia*. 2010 May; 6(3):202-11.



## NEURORADIOLOGY

William P. Dillon, MD, Chief

### Research Directions:

#### Neuropediatrics

- Cause of cerebellar hypoplasia in some prematurely born neonates
- Effects of brain cooling on CNS injury in term neonates suffering hypoxic-ischemic injury
- Embryogenesis of disorders of the midbrain and hindbrain
- Normal and abnormal development of the cerebral cortex
- Fetal MR Neuroimaging: development and application of advanced MRI techniques to study normal and abnormal fetal brain development.

#### Traumatic Brain Injury

- DTI and fiber tractography, fMRI, 3D MRSI, and deformation morphometry as imaging biomarkers for mild TBI to predict clinical outcomes in post-concussive syndrome, with correlation to neurocognitive testing and genomic analysis for TBI susceptibility genes such as ApoE
- DTI and fiber tractography processing for a multi-center consortium study of mild TBI

#### Cardiovascular Disease and Stroke

- Use of 64-slice CT to detect of cardiovascular disease and stroke
- Functional mapping and scoring system for predicting the outcome of ischemic stroke
- Use of perfusion and CTA imaging to detect ongoing hemorrhages in the brain of patients presenting with acute intracerebral hematoma
- Use of permeability image mapping to detect stroke patients at risk of subsequent hemorrhage
- Automated software for the outcome classification of patients with acute subarachnoid hemorrhage

#### Brain Tumors

- Use of permeability and perfusion imaging to guide operative biopsy
- Correlation of genetic markers and imaging markers from tissue obtained by image-guided biopsy

#### Head and Neck

- The utility of PET/CT in follow-up of patients with head and neck cancer
- The use of advanced imaging techniques in the detection of recurrent head and neck cancer

#### Spine

- CT-guided back pain management
- Use of image guidance to improve the accuracy of injections
- Utility of gadolinium MR myelography to detect CSF leaks
- MR neurography for peripheral nerve diagnosis

#### Neurodegenerative Diseases

- New imaging biomarkers for neurodegenerative diseases using 7T MRI
- 7T imaging of patients with intractable epilepsy
- Characterization of multimodal diffusion data using high-angular, resolution-diffusion imaging

### Recent Key References:

Desikan RS, Cabral HJ, Settecase F, Hess CP, Dillon WP, Glastonbury CM, Weiner MW, Schmansky NJ, Salat DH, Fischl B. Automated MRI measures predict progression to Alzheimer's disease. *Alzheimer's Disease Neuroimaging Initiative*. *Neurobiol Aging*. 2010 Aug;31(8):1364-74.

Glastonbury CM, Parker EE, Hoang JK. The postradiation neck: evaluating response to treatment and recognizing complications. *AJR Am J Roentgenol*. 2010 Aug;195(2):W164-71.

Glenn OA. MR imaging of the fetal brain. *Pediatr Radiol*. 2010 Jan;40(1):68-81.

Maruta J, Suh M, Niogi SN, Mukherjee P, Ghajar J. Visual tracking synchronization as a metric for concussion screening. *J Head Trauma Rehabil*. 2010 Jul-Aug;25(4):293-305.

Niogi SN, Mukherjee P. Diffusion tensor imaging of mild traumatic brain injury. *J Head Trauma Rehabil*. 2010 Jul-Aug;25(4):241-55.

Raj A, Hess C, Mukherjee P. Spatial HARDI: Improved visualization of complex white matter architecture with Bayesian spatial regularization. *Neuroimage*. 2010 Jul 27.

Yuh EL, Barkovich AJ, Gupta N. Imaging of ependymomas: MRI and CT. *Childs Nerv Syst*. 2009 Oct;25(10):1203-13.



## NEUROVASCULAR/NEUROINTERVENTIONAL RESEARCH INTEREST GROUP

Steven Hetts, MD, Co-Director

David Saloner, PhD, Co-Director

### Research Directions:

The Neurovascular/NIR RIG aims to use state-of-the-art imaging in monitoring the evolution of vascular disease; in assessing the delivery and efficacy of image-guided interventions and medical therapies; and in improving the selection of stroke patients for acute reperfusion therapy.

### Recent Key References:

Rayz VL, Boussel L, Ge L, Leach JR, Martin AJ, Lawton MT, McCulloch C, Saloner D. Flow Residence Time and Regions of Intraluminal Thrombus Deposition in Intracranial Aneurysms. *Ann Biomed Eng*. 2010 PMID: 20499185

Starr PA, Martin AJ, Ostrem JL, Talke P, Levesque N, Larson PS. Subthalamic nucleus deep brain stimulator placement using high-field interventional magnetic resonance imaging and a

skull-mounted aiming device: technique and application accuracy. *J Neurosurg*. 2010 Mar;112(3):479-90. PMID: 19681683

Saloner D, Uzelac A, Hetts S, Martin A, and Dillon WP. Modern Meningioma Imaging Techniques. *J Neurooncol*. 2010 PMID: 20809250



## NUCLEAR MEDICINE

Miguel Hernandez Pampaloni, MD, PhD, Chief

### Research Directions:

- Cardiac and vascular applications of clinical SPECT/CT, PET, and PET/CT
  - Applications of SPECT/CT for cardiac synchrony
  - Dementia imaging with SPECT/CT
  - Clinical PET and PET/CT studies of cancer, cardiovascular, and neurological diseases
  - Feasibility of PET and MRI to characterize myocardial metabolism and flow
  - Use of PET in monitoring therapy for breast and ovarian cancers
  - Conformal radiation treatment planning with PET/CT
  - Imaging structure and function in small animals with SPECT/CT
  - Molecular probe development for SPECT and PET

### Key Recent References:


Del Romeral LM, Stillson C, Lesh M, Dae M, Botvinick E. The relationship of myocardial contraction and electrical excitation—the correlation between scintigraphic phase image analysis and electrophysiologic mapping. *J Nucl Cardiol*. 2009 Sep-Oct;16(5):792-800.

Mihardja SS, Gao D, Sievers RE, Fang Q, Feng J, Wang J, Vanbrocklin HF, Larrick JW, Huang M, Dae M, Lee RJ. Targeted *in vivo* extracellular matrix formation promotes neovascularization in a rodent model of myocardial infarction. *PLoS One*. 2010 Apr 28;5(4):e10384.

Nikolic SD, Khairkhan A, Ryu M, Champsaur G, Breznock E, Dae M. Percutaneous implantation of an intraventricular device

for the treatment of heart failure: experimental results and proof of concept. *J Card Fail.* 2009 Nov;15(9):790-7.

Seo Y, Aparici CM, Cooperberg MR, Konety BR, Hawkins RA. In vivo tumor grading of prostate cancer using quantitative <sup>111</sup>In-capromab pendetide SPECT/CT. *J Nucl Med.* 2010 Jan;51(1):31-6.



#### NUCLEAR-OPTICAL SPECIALIZED RESOURCE GROUP

Henry F. VanBrocklin, PhD, Co-Director

Carina Mari Aparici, MD, Co-Director

##### Research Directions:

- Developing targeted nanoparticles for early pancreatic cancer detection
- Evaluating molecular probes for mesothelioma imaging
- Preparing phosphoramidate imaging agents for prostate cancer
- Identifying breast cancer premalignancy with molecular probes
- Noninvasive detection of heart transplant rejection with molecular probes
- Characterizing atherosclerotic plaques
- Hypoxia as a biomarker for tuberculosis and breast cancer
- Development of an automated system for the preparation of fluorine-18 fluorine gas for PET radiochemistry
- Developing a quantitative multipinhole SPECT/CT technology for highly sensitive targeted volume imaging
- Quantitative SPECT/CT and PET/CT imaging of prostate cancer using molecular probes
- Developing a patient-specific pretherapy dosimetry tool for targeted radiotherapy of neuroblastoma
- Developing quantitative dynamic SPECT/CT and PET/CT techniques for myocardial perfusion imaging
- Developing dual isotope simultaneous acquisition of myocardial perfusion imaging
- Developing novel radionuclide detector technologies for small animal imaging
- Developing quantitative dynamic imaging techniques for microPET/CT imaging of cardiovascular and cancer research

- Molecular imaging of metastatic lymph nodes in breast cancer
- Preparing tungsten-based nanomaterials for imaging applications
- Tracking distribution of labeled stem cells targeting the myocardium and assessing their physiologic effects on myocardial perfusion and function

##### Recent Key References:

He J, Wang Y, Feng J, Zhu X, Lan X, Iyer AK, Zhang N, Seo Y, VanBrocklin HF, Liu B. Targeting prostate cancer cells in vivo using a rapidly internalizing novel human single-chain antibody fragment. *J Nucl Med.* Mar 2010;51(3):427-432.

Lapi SE, Wahnische H, Pham D, Wu LY, Nedrow-Byers JR, Liu T, Vejdani K, VanBrocklin HF, Berkman CE, Jones EF. Assessment of an <sup>18</sup>F-labeled phosphoramidate peptidomimetic as a new prostate-specific membrane antigen-targeted imaging agent for prostate cancer. *J Nucl Med.* Dec 2009;50(12):2042-2048.

Mihardja SS, Gao D, Sievers RE, Fang Q, Feng J, Wang J, VanBrocklin HF, Larrick JW, Huang M, Dae M, Lee RJ. Targeted in vivo extracellular matrix formation promotes neovascularization in a rodent model of myocardial infarction. *PLoS One.* 5(4):e10384.

Seo Y, Aparici CM, Cooperberg MR, Konety BR, Hawkins RA. In vivo tumor grading of prostate cancer using quantitative <sup>111</sup>In-capromab pendetide SPECT/CT. *J Nucl Med.* Jan 2010;51(1):31-36.

Zeng GL, Gullberg GT. Exact iterative reconstruction for the interior problem. *Phys Med Biol.* Oct 7 2009;54(19):5805-5814.

#### PEDIATRIC/FETAL RESEARCH INTEREST GROUP

A. James Barkovich, MD, Director

##### Research Directions:

- Developing new imaging techniques to assess normal and abnormal development, including MRSI and DTI
- Developing new technology for imaging fetuses and neonates and adapting state-of-the-art techniques for application in the developing fetus and infant
- Using imaging techniques to:
  - diagnose and study malformations of the brain
  - assess injury in premature and term neonates
  - assess new therapies for injured fetuses and neonates
  - assess brain injury in neonates and infants with severe congenital heart disease

##### Recent Key References:

Berman JJ, Hamrick SE, McQuillen PS, Studholme C, Xu D, Henry RG, Hornberger LK, Glenn OA. Diffusion-Weighted Imaging in



Fetuses with Severe Congenital Heart Defects. *AJNR Am J Neuroradiol*. 2010 Feb 11. [Epub ahead of print]

Bonifacio SL, Glass HC, Chau V, Berman JI, Xu D, Brant R, Barkovich AJ, Poskitt KJ, Miller SP, Ferriero DM. Extreme Premature Birth is not Associated with Impaired Development of Brain Microstructure. *J Pediatr*. 2010 Jun 30. [Epub ahead of print]

Curran PF, Jelin EB, Rand L, Hirose S, Feldstein VA, Goldstein RB, Lee H. Prenatal steroids for microcystic congenital cystic adenomatoid malformations. *J Pediatr Surg*. 2010 Jan;45(1):145-50.

Habas PA, Kim K, Rousseau F, Glenn OA, Barkovich AJ, Studholme C. Atlas-based segmentation of developing tissues in the human brain with quantitative validation in young fetuses. *Hum Brain Mapp*. 2010 Sep;31(9):1348-58.

Glenn OA, Quiroz EM, Berman JI, Studholme C, Xu D. Diffusion-weighted imaging in fetuses with unilateral cortical malformations and callosal agenesis. *AJNR Am J Neuroradiol*. 2010 Jun;31(6):1100-2.

Xu D, Vigneron D. Magnetic resonance spectroscopy imaging of the newborn brain—a technical review. *Semin Perinatol*. 2010 Feb;34(1):20-7. Review.



## PEDIATRIC RADIOLOGY

John MacKenzie, MD, Chief

### Research Directions:

The mission of the Pediatric Radiology section is to improve the health of children through advanced clinical imaging and research. The section studies pediatric disease through the lens of imaging and is focused on developing new imaging technologies. Several ongoing basic science and clinical studies are underway in collaboration with MRI physics, pediatric oncology, pediatric gastroenterology, and pediatric surgery. Examples of our research include:

- Novel contrast media for use in tumor detection and angiogenesis

- Hyperpolarized-<sup>13</sup>C MRSI to detect and monitor treatment of inflammatory arthritis
- High resolution MRI to characterize treatment of congenital rectal floor abnormalities

### Recent Key References:

MacKenzie JD, Vasanaawala SS. State-of-the-art in pediatric body and musculoskeletal magnetic resonance imaging. *Semin Ultrasound CT MR*. 2010 Apr;31(2):86-99. Review.

MacKenzie JD, Yen Y-F, Mayer D, Spielman DM. Hyperpolarized [1-<sup>13</sup>C]-Pyruvate Metabolic Imaging for Treatment of Inflammatory Arthritis. *Society of Pediatric Radiology*. April 13-17, 2010, Boston, MA.

Courtier J, Poder L, Wang ZJ, Westphalen A, Yeh BM, Coakley F. Fetal tracheolaryngeal obstruction: prenatal evaluation by sonography and MRI. *Pediatr Radiol*. 2010 Aug 25. [Epub ahead of print]

Hope TA, High WA, Leboit PE, Chaopathomkul B, Rogut VS, Herfkens RJ, Brasch RC. Nephrogenic systemic fibrosis in rats treated with erythropoietin and intravenous iron. *Radiology*. 2009 Nov;253(2):390-8.

Sennino B, Raatschen HJ, Wendland MF, Fu Y, You WK, Shames DM, McDonald DM, Brasch RC. Correlative dynamic contrast MRI and microscopic assessments of tumor vascularity in RIP-Tag2 transgenic mice. *Magn Reson Med*. 2009 Sep;62(3):616-25.

## PROSTATE CANCER RESEARCH INTEREST GROUP

John Kurhanewicz, PhD, Co-Director

Fergus V. Coakley, MD, Co-Director

### Research Directions:

- Developing an optimized and clinically feasible multiparametric MR protocol for prostate cancer and diseases of the liver
- Rigorous histopathological correlative studies to validate MR biomarkers
- Developing ways to analyze multiparametric imaging data
- Developing clinical predictive nomograms that incorporate imaging variables
- Image-guided biopsy and therapy
- Identifying, validating, and implementing robust, quantitative, noninvasive magnetic-resonance-based metabolomic biomarkers of human disease and therapeutic response using *ex vivo* tissues, biofluids, and preclinical cell and murine models of human disease
- Developing targeted contrast agents for prostate cancer and other diseases
- Developing and implementing hyperpolarized-<sup>13</sup>C magnetic resonance spectroscopic imaging in prostate cancer patients



### Recent References:

Ghotb A, Noworolski SM, Madden E, Scherzer R, Qayyum A, Pannell J, Ferrell L, Peters M, Tien PC. Adipose Tissue and Metabolic Factors Associated With Steatosis in HIV/HCV Coinfection: Histology Versus Magnetic Resonance Spectroscopy. *J Acquir Immune Defic Syndr*. 2010 May 27. [Epub ahead of print]

Noworolski SM, Reed GD, Kurhanewicz J, Vigneron DB. Post-processing correction of the endorectal coil reception effects in MR spectroscopic imaging of the prostate. *J Magn Reson Imaging*. 2010 Sep;32(3):654-62.

Qayyum A. Diffusion-weighted imaging in the abdomen and pelvis: concepts and applications. *Radiographics*. 2009 Oct;29(6):1797-810.

Ratney H, Albers MJ, Rabeson H, Kurhanewicz J. Semi-parametric time-domain quantification of HR-MAS data from prostate tissue. *NMR Biomed*. 2010 Sep 15. [Epub ahead of print]

Westphalen AC, Coakley FV, Kurhanewicz J, Reed G, Wang ZJ, Simko JP. Mucinous adenocarcinoma of the prostate: MRI and MR spectroscopy features. *AJR Am J Roentgenol*. 2009 Sep;193(3):W238-43.

Westphalen AC, Coakley FV, Roach M 3rd, McCulloch CE, Kurhanewicz J. Locally recurrent prostate cancer after external beam radiation therapy: diagnostic performance of 1.5-T endorectal MR imaging and MR spectroscopic imaging for detection. *Radiology*. 2010 Aug;256(2):485-92.

### SAN FRANCISCO GENERAL HOSPITAL

Mark W. Wilson, MD, Chief

### Research Directions:

- Imaging evaluation of pulmonary embolism, particularly the ability of CT pulmonary angiography to predict outcomes in patients with pulmonary embolism
- Utility of imaging for diagnosis in AIDS patients
- Functional evaluation of pulmonary nodules in patients with suspected lung carcinoma, imaging of mesothelioma
- Imaging recurrent pyogenic cholecystitis and cholangitis
- Imaging trauma to the spine and spinal cord, chest, abdomen, and extremities
- Exploring MR sequences before and after gadolinium for focal hepatic lesions
- Neutral versus positive oral contrast in abdominal imaging
- Evaluating and maintaining atypical dialysis access grafts and fistulas
- Outcomes of transcatheter embolization for treatment of hemorrhagic complications of pregnancy termination



- Evaluating evolving techniques for transcatheter embolization for pelvic trauma
- Magnetic catheter manipulation in the MRI environment
- Proliferation of ultrasound in underdeveloped countries
- Global health care initiatives
- Internet applications in radiology
- Evaluating patterns of infection by atypical mycobacteria
- Evaluating HRCT features of interstitial lung disease in the setting of hypersensitivity pneumonitis
- Imaging and computer-aided assessment of traumatic brain injury
- Optimizing hepatic MRI and CT imaging parameters
- Transcatheter treatment of pelvic hemorrhage: post-traumatic, post-partum, and post-abortion.

### Recent Key References:

Bernhardt AF, Wilson MW, Settecasse F, Evans L, Malba V, Martin AJ, Saeed M, Roberts TPL, Arenson RL, Hettis SW. Steerable Catheter Microcoils for Interventional MRI: Reducing Resistive Heating. *Academic Radiology* (in press).

Cantu RC, Gean AD. Second-impact syndrome and a small subdural hematoma: an uncommon catastrophic result of repetitive head injury with a characteristic imaging appearance. *J Neurotrauma*. 2010 Sep;27(9):1557-64.

Gean AD, Fischbein NJ, Purcell DD, Aiken AH, Manley GT, Stiver SI. Benign Anterior Temporal Epidural Hematoma: Indolent Lesion with a Characteristic CT Imaging Appearance after Blunt Head Trauma. *Radiology*. 2010 Oct;257(1):212-8.

Jelin AC, Glenn OA, Strachowski L, Vargas JE. Membranous aplasia cutis congenita: a recognizable lesion on prenatal sonography. *J Ultrasound Med*. 2009 Oct;28(10):1393-6.

Rybkin AV, Wilson M. Internet-based flexible communication system in radiology. *J Digit Imaging* (in press).

Settecase F, Hetts SW, Martin AJ, Roberts TPL, Bernhardt AF, Evans L, Malba V, Saeed M, Arenson RL, Kucharczyk W, Wilson MW. RF Heating of MRI-Assisted Catheter Steering Coils for Interventional MRI. *Academic Radiology* (in press).

Urbania TH, Hope MD, Huffaker SD, Reddy GP. Role of computed tomography in the evaluation of acute chest pain. *J Cardiovasc Comput Tomogr*. 2009 Jan-Feb;3(1 Suppl):S13-22.



## ULTRASOUND

Ruth B. Goldstein, MD, Chief

### Research Directions:

- Prenatal diagnosis of CNS anomalies with ultrasound and MRI
- Further investigation of clinical manifestations and treatment of twin transfusion syndrome
- Prospective, randomized trial of repair of fetal myelomeningocele
- Prospective, randomized trial for selective ablation of connecting vessels in twin transfusion syndrome

### Recent Key References:

Aziz S, Cho RC, Baker DB, Chhor C, Filly RA. "Empty" sac in pregnant women with bleeding: are measurements answering the right question? *J Clin Ultrasound*. 2009 Jun;37(5):249-52.

Courtier J, Poder L, Wang ZJ, Westphalen AC, Yeh BM, Coakley FV. Fetal tracheolaryngeal airway obstruction: prenatal evaluation by sonography and MRI. *Pediatr Radiol*. 2010 Aug 25. [Epub ahead of print]

Esakoff TF, Sparks TN, Kaimal AJ, Kim LH, Feldstein VA, Goldstein RB, Cheng YW, Caughey AB. Diagnosis and morbidity of placenta accreta. *Ultrasound Obstet Gynecol*. 2010 Sep 2. [Epub ahead of print]

Filly MR, Filly RA, Barkovich AJ, Goldstein RB. Supratentorial abnormalities in the Chiari II malformation, IV: the too-far-back ventricle. *J Ultrasound Med*. 2010 Feb;29(2):243-8.

Filly MR, Callen PW, Yegul NT, Filly RA. The yolk stalk sign: evidence of death in small embryos without heartbeats. *J Ultrasound Med*. 2010 Feb;29(2):237-41.

Smith-Bindman R, Lipson J, Marcus R, Kim KP, Mahesh M, Gould R, Berrington de González A, Miglioretti DL. Radiation dose associated with common computed tomography examinations and the associated lifetime attributable risk of cancer. *Arch Intern Med*. 2009 Dec 14;169(22):2078-86.

Taplin S, Abraham LA, Geller B, Barlow WE, Buist DSM, Smith-Bindman R, Lehman C, Smith-Bindman R. Is computed tomography safe? *N Engl J Med*. 2010 Jul 1;363(1):1-4.



## VETERANS AFFAIRS MEDICAL CENTER

Judy Yee, MD, Chief

### Research Directions:

Diagnostic Radiology

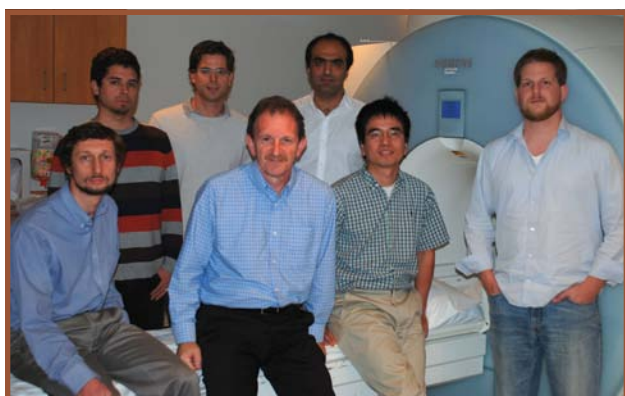
- Reduced cathartic and non-cathartic CT colonography
- Assessment of bone mineral density on CT colonography
- Comparison of eovist MR and contrast-enhanced CT for the detection of hepatocellular carcinoma
- Spectral imaging, dual-energy and low kVp CT imaging
- Dynamic contrast-enhanced (perfusion) imaging in the abdomen and pelvis
- Novel applications of CT and MR contrast timing and delivery in the abdomen and pelvis

### Recent Key References:

Benedetti N, Aslam R, Wang ZJ, Joe BN, Fu Y, Yee J, Yeh BM. Delayed enhancement of ascites following i.v. contrast material at CT: time course and clinical correlation. *AJR Am J Roentgenol*. 2009 Sep;193(3):732-7.

Berrington A, Yee J. Safety of CT Colonography. *Gastrointest Endosc Clin N Am*. 2010;20:260-277.

Fletcher JG, Chen M, Herman BA, Johnson CD, Toledano A, Dachman A, Hara AK, Fidler JL, Menias C, Coakley K, Kuo M, Horton K, Cheema J, Iyer R, Siewart B, Yee J, et al. Can radiologist training and testing ensure high performance in CT Colonography? Lessons from the National CT Colonography Trial. *AJR Am J Roentgenol*. 2010 Jul;195(1):117-25.



Kirkland JG, Godfrey GB, Garrett R, Kakar S, Yeh BM, Corvera CU. Reversible Surgical Model of Biliary Inflammation and Obstructive Jaundice in Mice. *J Surg Res*. 2009 Sep 11. [Epub ahead of print]

McFarland EG, Fletcher JG, Pickhardt PJ, Dachman AH, Yee J, Macari M, et al. ACR Colon Cancer Committee White Paper: Status of CT Colonography 2009. *J Am Coll Radiol*. 2009 Nov;6(11):756-772.e4.

Thornton E, Morrin MM, Yee J. Current status of MR colonography. *Radiographics*. 2010 Jan-Feb;30(1):201-18.

Yee J, Rosen MP, Blake MA, Baker ME, Cash BD, Fidler JL, et al. Colorectal Cancer Screening American College of Radiology Appropriateness Criteria 2010. *J Am Coll Radiol* 2010;7:670-678.

Yee J, Sadda S, Aslam R, Yeh B. Extracolonic findings at CT colonography. *Gastrointest Endosc Clin N Am*. 2010 Apr;20(2):305-22. Review.

Yeh BM, Liu PS, Soto JA, Corvera CA, Hussain HK. MR imaging and CT of the biliary tract. *Radiographics*. 2009 Oct;29(6):1669-88.

Zhang LJ, Peng J, Wu SY, Yeh BM, Zhou CS, Lu GM. Dual source dual-energy computed tomography of acute myocardial infarction: correlation with histopathologic findings in a canine model. *Invest Radiol*. 2010 Jun;45(6):290-7.

*Research directions and references for the Center for Imaging of Neurodegenerative Diseases (CIND) at the VAMC are listed under the Neurodegenerative Diseases Research Interest Group on page 78. Research directions and references for the Vascular Imaging Research Center at the VAMC are listed under the Neurovascular/Neurointerventional Research Interest Group on page 80.*

## WOMEN'S IMAGING

Bonnie N. Joe, MD, PhD, Chief

### Research Directions:

- MRI, optical imaging, and X-ray mammography for breast cancer screening and surveillance, diagnosis, and tissue characterization for risk assessment, cancer staging, and treatment response assessment
- New techniques in MRI-guided biopsy and imaging protocols
- Quantitative assessment of breast density and breast cancer risk models
- Digital breast tomosynthesis
- MRI/MRS for assessing tumor response to neo-adjuvant chemotherapy for patients with locally advanced breast cancer
- MR spectroscopy for biomarker development in breast cancer and fetal maturity applications

### Recent Key References:

Burnside ES, Sickles EA, Bassett LW, Rubin DL, Lee CH, Ikeda DM, Mendelson EB, Wilcox PA, Butler PF, D'Orsi CJ. The ACR



BI-RADS experience: learning from history. *J Am Coll Radiol*. 2009 Dec;6(12):851-60.

Carney PA, Sickles EA, Monsees BS, Bassett LW, Brenner RJ, Feig SA, Smith RA, Rosenberg RD, Bogart TA, Browning S, Barry JW, Kelly MM, Tran KA, Miglioretti DL. Identifying minimally acceptable interpretive performance criteria for screening mammography. *Radiology*. 2010 May;255(2):354-61.

Chang CB, Lvoff NM, Leung JW, Brenner RJ, Joe BN, Tso HH, Sickles EA. Solitary dilated duct identified at mammography: outcomes analysis. *AJR Am J Roentgenol*. 2010 Feb;194(2):378-82.

Cohn BR, Fukuchi EY, Joe BN, Swanson MG, Kurhanewicz J, Yu J, Caughey AB. Calculation of gestational age in late second and third trimesters by *ex vivo* magnetic resonance spectroscopy of amniotic fluid. *Am J Obstet Gynecol*. 2010 Jul;203(1):76.e1-76.e10.

Cohn BR, Joe BN, Zhao S, Kornak J, Zhang VY, Iman R, Kurhanewicz J, Vahidi K, Yu J, Caughey AB, Swanson MG. Quantitative

metabolic profiles of 2nd and 3rd trimester human amniotic fluid using (1)H HR-MAS spectroscopy. *MAGMA*. 2009 Dec;22(6):343-52.

Wang SC, Joe BN, Esserman LJ. Magnetic resonance imaging is more accurate than mammography for assessing response to neoadjuvant chemotherapy in a breast cancer patient with significant calcifications. *Reports in Medical Imaging*. April, 2009 Volume 2009(2):35-40.



## Grants and Fellowships

### GRANTS

#### Ronald L. Arenson, MD

- Radiological Society of North America; Internet-Based Network for Patient-Controlled Medical Image Sharing Data, 9/30/09-9/29/10, \$76,559.
- Radiological Society of North America; NIBIB Image Sharing "Software Development Project," 9/30/09-9/29/11 \$96,875.

#### Anthony J. Barkovich, MD

- NIH National Institute Neurological Disorders and Stroke; DTL, MRSI, and Volumetry of Cerebellar Injury in Preterm Neonates, 9/25/09-8/31/10, \$462,522.

#### Richard S. Breiman, MD

- M.R. and Evelyn Hudson Foundation; Hudson Grant, 11/1/09-10/31/10, \$10,000.

#### Andrew J. Burghardt, BS

- Mayo Foundation/Mayo Clinic; Epidemiology of Age-Related Bone Loss and Fractures, 7/2/10-5/31/11, \$13,698.

#### Fergus V. Coakley, MD

- NIH National Center for Research Resources; High Field MR-Guided Focused Ultrasound System, 7/8/10-7/7/11, \$1,368,750.

#### William P. Dillon, MD

- ev3 Endovascular, Inc.; Solitaire With the Intention For Thrombectomy (SWIFT) Study, 2/5/10-2/4/11, \$362,250.

#### Jeremy C. Durack, MD

- ev3 Endovascular, Inc.; Safety and Efficacy of Percutaneously Delivered Liquid Embolic Agents, 11/15/09-11/14/10, \$12,600.

#### Nicholas Fidelman, MD

- Bayer HealthCare Pharmaceuticals, Inc.; Comparison of Multi-Detector CT and Multi-parametric MR Imaging Detection of Hepatocellular Carcinoma Detection: Assessment of Small Tumor Diagnosis and Detection of Post-Ablation Recurrence, 2/2/10-2/1/12, \$44,500.



**Roland G. Henry, PhD**

- NIH National Institute of Neurological Disorders and Stroke; Multimodal Connectivity for Surgical Mapping, 9/1/09–8/31/10, \$274,453.

**Miguel Hernandez Pampaloni, MD, PhD**

- Molecular Insight Pharmaceuticals, Inc.; A Phase II study evaluating the efficacy and safety of ultratrace iobenguane I 131 in patients with malignant relapsed/refractory pheochromocytoma/paraganglioma, 1/29/10–1/28/15, \$485,958.

**Randall T. Higashida, MD**

- Abbott; Vascular Carotid Stenting for high surgical risk patients; evaluating outcomes through the collection of clinical evidence (CHOICE), 5/3/10–4/14/16 \$114,325.

**Ella F. Jones, PhD**

- Omnix, Inc.; Imaging Fluorescently-tagged H-NOX Variants In Mouse Xenografts, 1/22/10–3/21/12, \$29,413.
- Washington State University; Probe Optimization for Prostate Cancer Detection, 4/5/10–1/31/11, \$180,349.

**John Kurhanewicz, PhD**

- MEDRAD, Inc.; Medrad, E-Coil Testing Contract, 11/12/09–3/12/10, \$13,197.
- DOD US Army Medical Research Acq. Activity; Discovery of Hyperpolarized Molecular Imaging Biomarkers, 5/15/10–5/14/11 \$133,428.
- NIH National Cancer Institute; Translation and Evaluation of a Multiparametric Prostate Cancer 3T MRI Exam, 8/9/10–6/30/11 \$582,287.
- AdMeTech Foundation; Molecular Imaging of Prostate Cancer, 9/21/09–7/31/10 \$49,762.

**Thomas F. Lang, PhD**

- Merck and Co., Inc.; *In Vivo* Imaging of Skeletal Muscle Protein Synthesis using PET/CT with L-[methyl-11C]methionine, 8/24/09–8/23/10, \$25,200.

**Peder E. Larson, PhD**

- NIH National Institute of Biomedical Imaging and Bioengineering; Hyperpolarized C-13 MR Pulse Sequence Developments for Novel Contrast, 9/1/10–8/31/11, \$83,459.

**Xiaojuan Li, PhD**

- NIH National Institute of Arthritis, Musculoskeletal and Skin; *In Vivo* Early Detection of Cartilage Degeneration Using High Field MRI, 9/18/09–9/17/11, \$99,986.

**Thomas M. Link, MD, PhD**

- NIH National Institute of Arthritis, Musculoskeletal and Skin; T2 Relaxation Time of Knee Cartilage in the OAI Incidence Subcohort Cooperative Agreement, 8/1/10–6/30/11, \$217,660.

- NIH Institute of Arthritis, Musculoskeletal and Skin; Cortical Bone Porosity identifies Diabetes Subjects with Fragility Fractures 9/30/09–8/31/10, \$419,410.

**Sharmila Majumdar, PhD**

- Institute of Arthritis, Musculoskeletal and Skin; A Multi-Disciplinary Multi-Department Core on Musculoskeletal Imaging, 9/30/09–8/31/10, \$468,213.
- UC Davis; 3D *In Vivo* Morphometry of Trabecular Microstructure, 4/1/09–1/31/10, \$8,888.

**Alastair J. Martin, PhD**

- UC Discovery-Surgi-Vision; Optimized Methodology for Implantation of DBS Electrodes, 11/2/09–11/1/10, \$506,255.

**Tracy R. McKnight, PhD**

- NIH National Cancer Institute; Identification of MRS Markers of Glioma Progression, 9/1/09–8/31/10, \$49,195.
- NIH National Cancer Institute; The Effect of p53 Signaling on the Metabolism and Therapeutic Response of Glioma, 6/29/1–05/31/11, \$161,886.

**Dieter Meyerhoff, PhD**

- NIH, Polysubstance Use and Chronic Smoking; Neuroimaging and Cognition, 8/15/09–7/31/11, \$426,250.

**Srikantan S. Nagarajan, PhD**

- UC Davis; Neural Substrates of Switching in Parkinson's Disease, 7/25/09–6/30/10, \$150,383.

**Sarah Nelson, PhD**

- NIH National Center for Research Resources; 3T MR Scanner for Translational Research using MRI and MRSI, 6/3/10–6/2/11, \$2,299,500.
- NIH National Center for Research Resources; Upgrading a 7T Scanner to Study Cancer, Neurological and Musculoskeletal Diseases, 6/10/10–6/9/11, \$500,000.
- UC Discovery/General Electric Company; Novel MR Technology—Monitoring Treatment in Human Disease, 7/1/10–6/30/11, \$2,113,174.

**Susan Noworolski, PhD**

- NIH National Cancer Institute; DCE MRI to Improve Prostate Cancer Identification and Characterization, 4/1/10–1/31/11 \$263,705.

**Karen G. Ordovás, MD**

- American Roentgen Ray Society; Coronary CTA for Assessment of Coronary Allograft Vasculopathy, 7/1/10–6/30/11 \$70,000.

**Sabrina M. Ronen, PhD**

- DOD US Army Medical Research. Acq. Activity; Discovery of Hyperpolarized Molecular Imaging Biomarkers, 5/15/10–5/14/11, \$131,958.

## David A. Saloner, PhD

- VP Diagnostics, Inc.; Performance of "SmartRisk" Prediction of Stroke and Stroke Related Events in Carotid Atherosclerosis, 8/1/0–98/31/10 \$156,727.

## Norbert Schuff, PhD

- NIH; The Frontotemporal Lobar Degeneration Neuroimaging Initiative, \$2,392,276.

## Youngho Seo, PhD

- NIH National Cancer Institute; Prostate Cancer Management with Multimodality Imaging, 8/1/09–7/31/11, \$92,975.

## John A. Shepherd, PhD

- NIH National Cancer Institute; The Breast Radiology Evaluation and Study of Tissues Stamp Project (NCI), 9/10/09–9/9/10, \$99,000.
- Social and Scientific Systems, Inc.; 9/1/09–5/31/10, \$102,702.

## Rebecca Smith-Bindman, MD

- Group Health Cooperative of Puget Sound; Medical Radiation Induced Cancers, 5/1/09–10/31/09, \$3,557.

## Radhika Srinivasan, PhD

- American Brain Tumor Association; Translation of an MR Diagnostic Assay for Tumor Assessment in Recurrent Malignant Glioma, 7/1/1–06/30/11, \$75,000.

## Henry F. VanBrocklin, PhD

- Varian Medical Systems; Imaging Hypoxia: Preparation and Evaluation at EF5, 11/1/09–10/31/11, \$210,000.
- CellSight Technologies; Pre-Clinical Molecular Imaging 5/20/10–5/19/11, \$62,942.25.
- UC Discovery-Info Tech for Life Sciences; Imaging Hypoxia: Preparation and Evaluation at EF5 11/1/09–10/31/10, \$66,709.
- Molecular Express (Iowa); Aptamers for Imaging and Therapy, 6/15/09–6/15/11, \$166,570.

## Daniel B. Vigneron, PhD

- NIH National Cancer Institute; Metabolic Imaging of the Prostate Using 3-D MRSI, 8/1/09–7/31/11, \$307,206.
- NIH National Institute of Biomedical Imaging and Bioengineering; Technique Development for Hyperpolarized C13 MR Studies, 9/30/09–9/29/10, \$1,221,350.
- UC Discovery/General Electric Company; Novel MR Technology—Monitoring Treatment in Human Disease, 7/1/10–6/30/11, \$2,113,174.

## Michael Weiner, MD

- Avid Radiopharmaceuticals, Inc.; Clinical Evaluation of (18) F-AV-45 for Diagnosis of Alzheimer's, 2/16/10–2/15/11, \$207,585.
- NIH; Alzheimer's Disease Neuroimaging Initiative 2, 9/30/10–8/31/15, \$69,995,000.
- NIH; Amyloid Imaging, VMCI, and Analysis for ADNI, 9/30/09–8/31/11, \$24,200,000.
- NIH; Resource for MRI of Neurodegenerative Disorders, 8/24/09–8/23/11, \$999,850.
- MJFF; Promoting Widespread Data Sharing Among Scientists, 11/1/09–8/31/10, \$75,000.
- NIH; Biomarkers for PTSD, 4/1/10–7/11/11, \$634,895.

## Benjamin Yeh, MD

- MEDRAD, Inc.; Retrospective evaluation of multiphase liver CT scans obtained with fixed scan delay versus patient-specific scan delays, 2/11/10–2/10/11, \$64,998.

## Xiaoliang Zhang, PhD

- NIH National Institute of Biomedical Imaging and Bioengineering; Multichannel Dual-tuned Transceiver Techniques for Human Low-Gamma Nuclei MR, 2/1/10–1/31/11, \$347,625.

## FELLOWSHIPS

### Thomas A. Hope, MD

- Radiological Society of North America; Validation of an NSF model in renal failure rats and evaluation of Imatinib as a potential treatment, 7/1/10–6/30/11, \$30,000.

### Gabrielle A. Joseph, PhD

- NIH National Institute of Arthritis, Musculoskeletal and Skin; MRI T2 Relaxation Time as a Predictor of Osteoarthritis, 4/1/10–3/31/11, \$46,590.

### Yan Li, PhD

- American Brain Tumor Association; Characterization of Gliomas using Ultra High Field MR Spectroscopic Imaging, 7/1/10–6/30/11, \$40,000.

### David P. Wipf, PhD

- NIH National Institute of Neurological Disorders and Stroke; Bayesian Methods for Localizing Dynamic Brain Activity and Epileptogenic Zones, 1/1/10–12/31/10, \$51,710.

**The Department of Radiology and Biomedical Imaging  
is grateful to the many alumni  
who give back with a gift to the department.**



“Training and developing future generations of radiologists is the responsibility of all of us in the field, not just the academic departments. So many individuals selflessly gave their time, money, and effort so I could enjoy the benefits of the best radiological training possible. Now that I have graduated and have moved into practice, I feel it is critically important to continue the cycle of giving to ensure that future radiology trainees enjoy these same opportunities and benefits.”

—Michael B. Gotway, MD, '98  
*Scottsdale Medical Imaging, Scottsdale, Ariz.*




“As a second-generation alum of UCSF and UCSF Radiology, I feel a strong connection to the department. I believe it is my responsibility to uphold the superb value of UCSF's education. The Department of Radiology and Biomedical Imaging at UCSF has provided an amazing foundation for my life ... it's just a matter of 'giving back!'”

—Kathryn Pearson Peyton, MD, '98  
*Mori, Bean & Brooks, Jacksonville, Florida*



“I am very grateful for the education I received as a resident and fellow at UCSF. I'm proud to be an alum of the department and feel that it is important to maintain the UCSF tradition of training excellent radiologists—so we can continue to hire them in our group!”

—Melissa Yu, MD, '03  
*Newport Harbor Radiology Associates, Inc., Newport Beach, Calif.*



“It is very satisfying to know that through my donation I participate in some way in the education of current residents. Providing the best resident education possible is an investment in the future of radiology.”

—Miriam Bredella, MD, '04  
*Harvard University, Cambridge, Mass.*



University of California  
San Francisco

---

*advancing health worldwide™*